

## Supplementary Material

### Table of Contents

Content	Page number
<u>Supplementary table 1</u> : Published research definitions of COVID-19 associated pulmonary aspergillosis	2-6
<u>Supplementary Figure 1</u> : Sensitivity analysis – Factors associated with a diagnosis of ‘CAPA’ when Possible cases are included with Probable cases to define ‘CAPA’ and when all possible cases are excluded from analysis.	7
<u>Supplementary Figure 2</u> : Sensitivity analysis – 90-day mortality risk when Possible cases are included with Probable cases to define ‘CAPA’ and when all possible cases are excluded from analysis.	8
<u>Supplementary Figure 3</u> : Venn diagram showing concordance between published CAPA case definitions	9

Supplementary table 1: Published research definitions of COVID-19 associated pulmonary aspergillosis.

Definition	Clinical/Host criteria	Bronchoscopy/ radiologic criteria	Mycological criteria
<b>Koehler (ECMM/ISHAM) [1]</b>			
<b>Proven</b> with or without tracheobronchitis	COVID-19 requiring ICU admission and temporal relationship		1) Histopathologic or direct microscopic detection of fungal hyphae showing invasive growth with associated tissue damage  AND/OR  2) <i>Aspergillus</i> spp. recovered by culture or microscopy or histology or PCR obtained by a sterile aspiration or biopsy from a pulmonary site showing an infectious disease process
<b>Probable</b> tracheobronchitis	COVID-19 requiring ICU admission and temporal relationship	Tracheobronchitis: tracheobronchial ulceration, nodule, pseudomembrane, plaque or eschar seen on bronchoscopy	≥ 1 of the following:  1) Microscopic detection of fungal elements on BAL, indicating a mould 2) Positive BAL culture or PCR 3) Serum: GM ≥ 0.5 ODI or LFA index ≥ 0.5 4) BAL: GM ≥ 1.0 ODI or LFA index ≥ 1.0
<b>Probable</b> Pulmonary form	COVID-19 requiring ICU admission and temporal relationship	Pulmonary infiltrate, preferably documented by chest CT  OR  Cavitating infiltrate (not attributed to another cause)	≥ 1 of the following:  1) Microscopic detection of fungal elements on BAL, indicating a mould 2) Positive BAL culture or PCR (Cycle threshold < 36) 3) Serum: GM ≥ 0.5 ODI or LFA index ≥ 0.5 4) BAL: GM ≥ 1.0 ODI or LFA index ≥ 1.0 5) ≥ 2 positive PCR in plasma, serum or whole blood 6) Single positive PCR in plasma, serum or whole blood AND a single positive BAL PCR (any cycle threshold)

<p><b>Possible</b></p> <p>Pulmonary forms</p>	<p>COVID-19 requiring ICU admission and temporal relationship</p>	<p>Pulmonary infiltrate, preferably documented by chest CT</p> <p>OR</p> <p>Cavitating infiltrate (not attributed to another cause)</p>	<p>≥ 1 of the following:</p> <ol style="list-style-type: none"> <li>1) Microscopic detection of fungal elements in NBL sample indicating a mould</li> <li>2) Positive NBL culture</li> <li>3) NBL GM ≥ 4.5 ODI</li> <li>4) ≥2 NBL GM ≥1.2 ODI</li> <li>5) NBL GM ≥1.2 ODI plus another NBL positive test (PCR or LFA)</li> </ol>
<p><b>Bassetti (EORTC/MSGERC-ICU) [2]</b>  <i>guidance also applies to non-COVID-19 patients (not included here)</i></p>			
<p><b>Proven</b></p>	<p>COVID-19 requiring ICU admission</p>		<p>≥ 1 of the following:</p> <ol style="list-style-type: none"> <li>1) Histopathologic, cytopathologic, or direct microscopic examination of a specimen obtained by needle aspiration or biopsy with hyphae compatible with <i>Aspergillus</i> spp. and evidence of associated tissue damage (with necessary confirmation by means of culture or PCR)</li> <li>2) Recovery of <i>Aspergillus</i> spp. by culture of a specimen obtained by a sterile procedure from a normally sterile site and clinically or radiologically abnormal site consistent with an infectious-disease process</li> </ol>
<p><b>Probable</b></p>	<p>Severe COVID-19 requiring ICU admission</p>	<p>≥ 1 of the following:</p> <ol style="list-style-type: none"> <li>1) Dense well-circumscribed lesions +/- halo sign</li> <li>2) Air crescent sign</li> <li>3) Cavity</li> <li>4) Wedge-shaped and segmental or lobar consolidation</li> <li>5) <i>Aspergillus</i> tracheobronchitis on bronchoscopy: tracheobronchial ulceration, pseudomembrane, nodule, plaque, or eschar</li> </ol>	<ol style="list-style-type: none"> <li>1) Cytology, direct microscopy and/or culture indicating presence of <i>Aspergillus</i> spp. in lower respiratory tract specimen</li> </ol> <p>OR ≥ 1 clinical/radiological abnormality consistent with an otherwise unexplained pulmonary infectious-disease process with:</p> <ol style="list-style-type: none"> <li>2) Serum/plasma: GM ≥ 0.5 ODI</li> <li>3) BAL: GM ≥ 0.8 ODI</li> </ol>

<b>White [3]</b>			
<b>Proven</b>	COVID-19 (PCR confirmed) with $\geq 1$ of the following: 1) Refractory fever despite $\geq 3$ days antibiotics 2) Recrudescence fever $\geq 48$ hours despite antibiotics 3) Dyspnea 4) Hemoptysis 5) Pleural rub or chest pain 6) Worsening respiratory function despite antibiotics and ventilatory support	$\geq 1$ of the following: 1) New infiltrates on chest x-ray or chest CT when compared with admission, including progression of signs attributed to viral infection. 2) Radiological signs typical of invasive pulmonary aspergillosis (nodules, halos, cavities, wedge-shaped and segmental or lobar consolidation) 3) Evidence of sinusitis with heightened suspicion of fungal disease	AND $\geq 1$ of the following: 1) Histology/Microscopy demonstrating dichotomous septate hyphae in tissue 2) Positive culture from tissue
<b>Putative</b> <i>Radiology typical of IA</i>	<i>As per proven above</i>	<i>As per proven above</i>	AND $\geq 1$ of the following: 1) Positive BAL/NBL culture 2) BAL or NBL: GM $\geq 1.0$ ODI 3) Serum: GM $\geq 0.5$ ODI 4) Serum/plasma: BDG $\geq 80$ pg/mL 5) Positive <i>Aspergillus</i> PCR in BAL or blood
<b>Putative</b> <i>Radiology non specific</i>	<i>As per proven above</i>	Non-specific radiology or typical radiology for IA as above attributed to different underlying disease e.g. lung cancer, alternative infection)	AND $\geq 2$ positives across different test types OR $\geq 2$ positives within single test type of the following: 1) Positive BAL/NBL culture 2) BAL or NBL: GM $\geq 1.0$ ODI 3) Serum: GM $\geq 0.5$ ODI 4) Serum/plasma: BDG $\geq 80$ pg/mL 5) Positive <i>Aspergillus</i> PCR in BAL or blood
<b>Verweij [4]</b>			

<b>Proven</b> tracheobronchitis	COVID-19 with temporal relationship	Tracheobronchitis: Airway plaque, pseudomembrane or ulcer	AND Biopsy or brush specimen showing hyphal elements and:  <i>Aspergillus</i> spp. culture  OR  Positive <i>Aspergillus</i> PCR from tissue
<b>Proven</b> without tracheobronchitis	COVID-19 with temporal relationship		Lung biopsy showing invasive fungal elements and:  <i>Aspergillus</i> growth on culture  OR  positive <i>Aspergillus</i> PCR in tissue
<b>Probable</b> tracheobronchitis	COVID-19 with temporal relationship	Tracheobronchitis: Airway plaque, pseudomembrane or ulcer	AND $\geq 1$ of the following:  1) Serum: GM $\geq 0.5$ ODI 2) BAL: GM $\geq 1.0$ ODI 3) BAL culture 4) TA culture 5) Sputum culture 6) Hyphae consistent with <i>Aspergillus</i>
<b>Probable</b> without tracheobronchitis	COVID-19 with temporal relationship	Pulmonary infiltrate  OR  Cavitating infiltrate (not attributable to other cause)	Pulmonary infiltrate with $\geq 1$ of the following:  1) Serum: GM $\geq 0.5$ ODI 2) BAL: GM $\geq 1.0$ ODI 3) BAL culture  OR  Cavitating infiltrate with $\geq 1$ of the following:  1) Serum: GM $\geq 0.5$ ODI 2) BAL: GM $\geq 1.0$ ODI 3) BAL culture 4) TA culture

			5) Sputum culture
--	--	--	-------------------

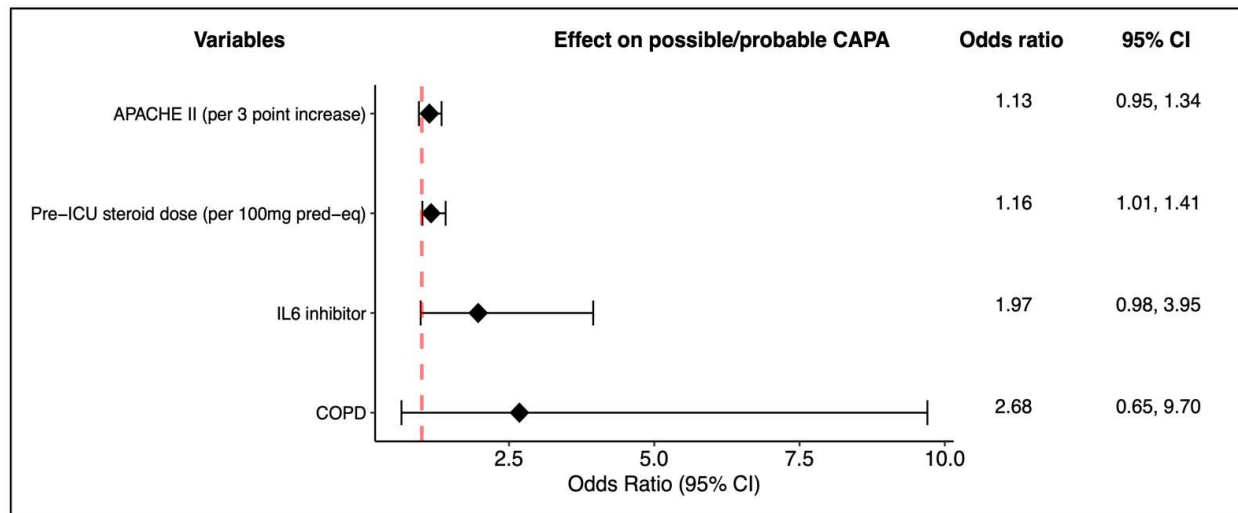
**Abbreviations:** BAL: bronchoalveolar lavage; BDG: 1-3- $\beta$ -D-glucan; CAPA: COVID-19 associated pulmonary aspergillosis; CT: computed tomography; ECMM/ISHAM: European Confederation of Medical Mycology-International Society for Human and Animal Mycoses; EORTC/MSGERC: European Organization for Research and Treatment of Cancer and the Mycoses Study Group Education and Research Consortium; GM: galactomannan; LFA: lateral flow assay; NBL: non-bronchoscopic lavage; ODI: optical density index; PCR: polymerase chain reaction

#### References

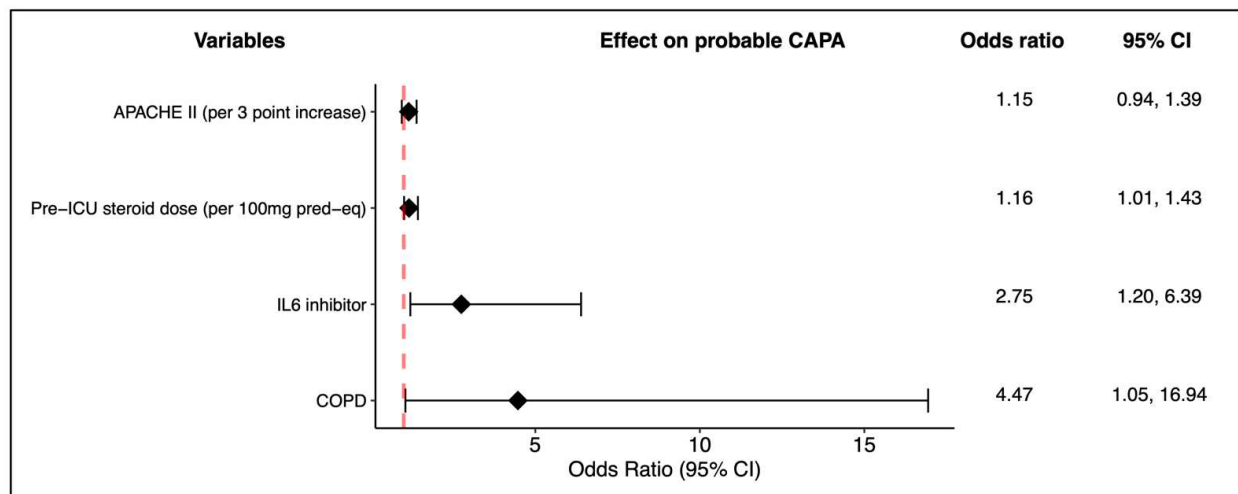
1. Koehler P, Bassetti M, Chakrabarti A, et al. Defining and managing COVID-19-associated pulmonary aspergillosis: the 2020 ECMM/ISHAM consensus criteria for research and clinical guidance. *The Lancet Infectious Diseases* **2021**; 21:e149–e162.
2. Bassetti M, Azoulay E, Kullberg B-J, et al. EORTC/MSGERC Definitions of Invasive Fungal Diseases: Summary of Activities of the Intensive Care Unit Working Group. *Clinical Infectious Diseases* **2021**; 72:S121–S127.
3. White PL, Dhillon R, Cordey A, et al. A National Strategy to Diagnose Coronavirus Disease 2019–Associated Invasive Fungal Disease in the Intensive Care Unit. *Clinical Infectious Diseases* **2021**; 73:e1634–e1644.
4. Verweij PE, Rijnders BJA, Brüggemann RJM, et al. Review of influenza-associated pulmonary aspergillosis in ICU patients and proposal for a case definition: an expert opinion. *Intensive Care Medicine* **2020**; 46:1524–1535.

**Supplementary figure 1: Sensitivity analysis – Factors associated with a diagnosis of ‘CAPA’ when Possible cases are included with Probable cases to define ‘CAPA’ and when all possible cases are excluded from analysis.**

A. Possible cases included with probable cases as ‘CAPA’ vs. those with ‘No CAPA’

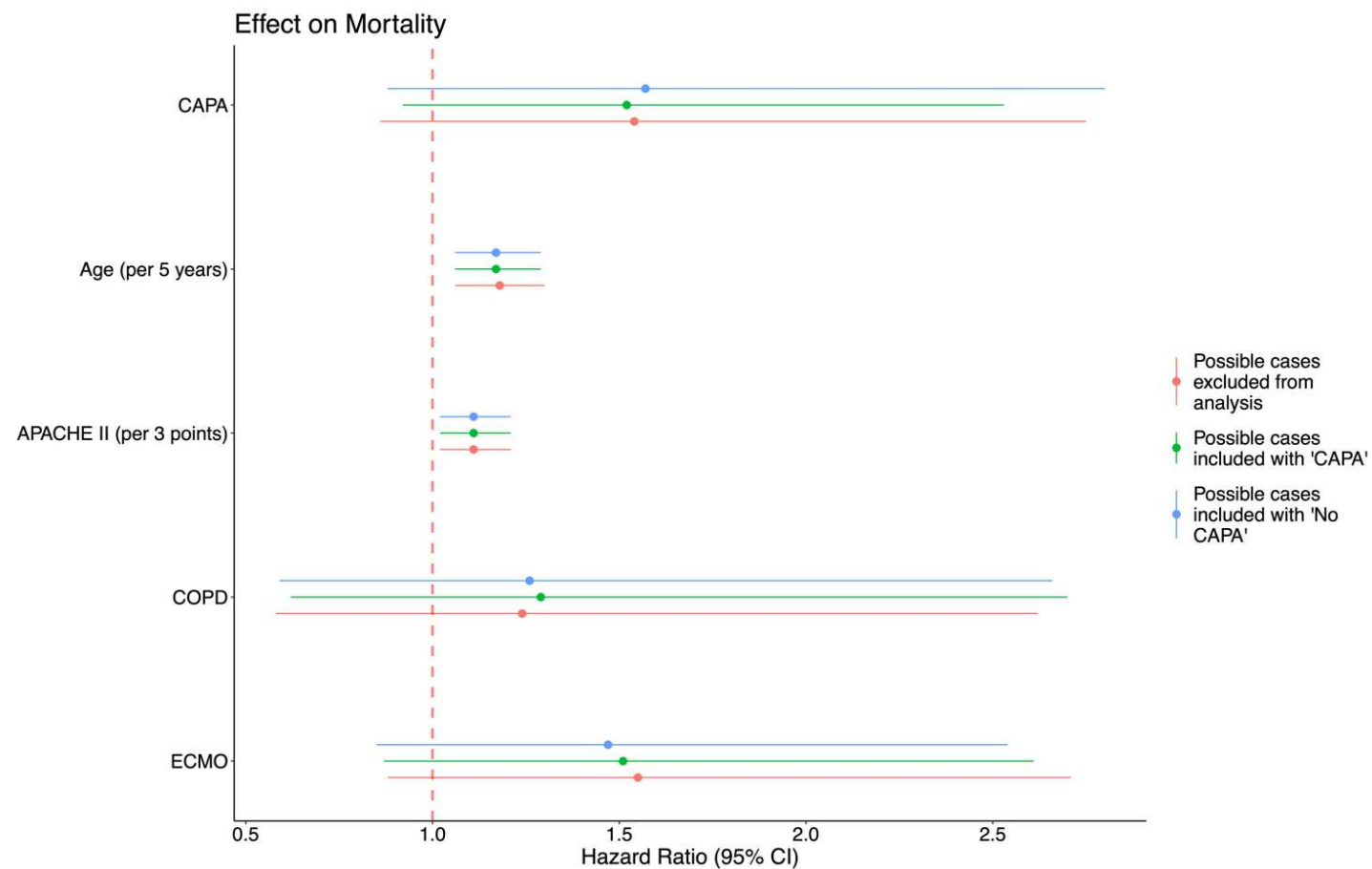


B. ‘Probable CAPA’ vs. ‘No CAPA’ – all possible cases removed from analysis.



**Supplementary figure 2: Sensitivity analysis: Time adjusted Cox proportional hazard model for 90-day mortality**

Adjusted for probable/ possible CAPA (ECMM/ISHAM), age, Apache II, COPD and ECMO. Excluding possible cases from the analysis (red) or including possible with probables as cases of CAPA (green) had no significant impact on the hazard ratios for mortality.





**Supplementary Figure 3. Venn diagram showing concordance between published CAPA case definitions according to the ECMM/ISHAM (probable/proven), Verweij (probable/proven), White (proven/putative) and Bassetti EORTC/MSGERC-ICU (Proven/Probable) criteria.**

