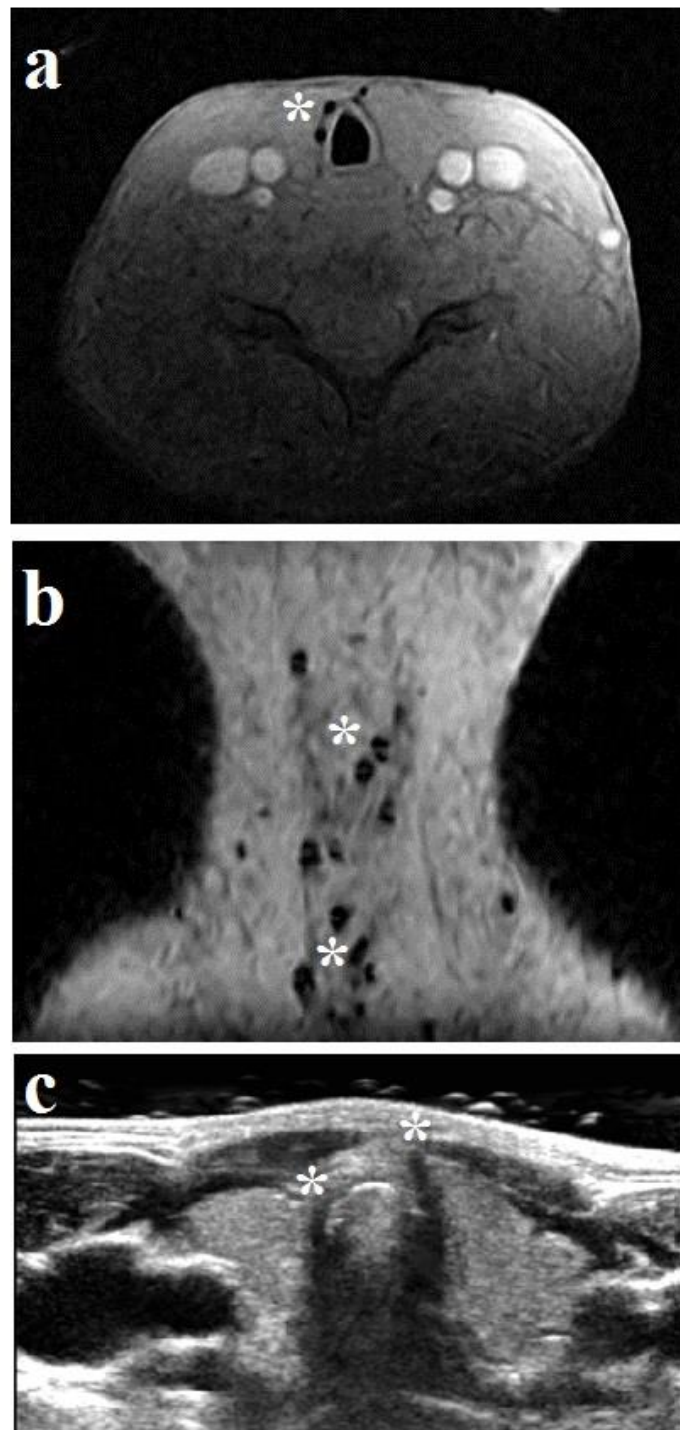


Online supplement 6: incidental finding of hypodense regions on proton density imaging

Online supplement 6: example of a patient with history of LTS showing an incidental finding of hypodense regions (*) on axial (A) and sagittal (B) proton density weighted MRI and corresponding ultrasonography (C).