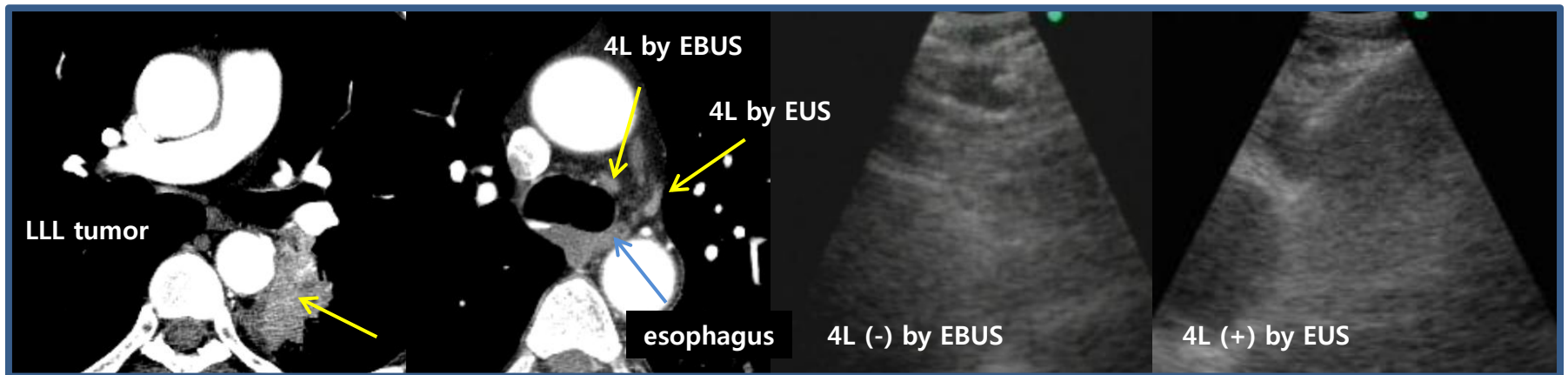


Supplemental Figures

These figures were prepared for editors and peer reviewers, **not for posting in the Online Supplement.**

Supplemental figure 1.

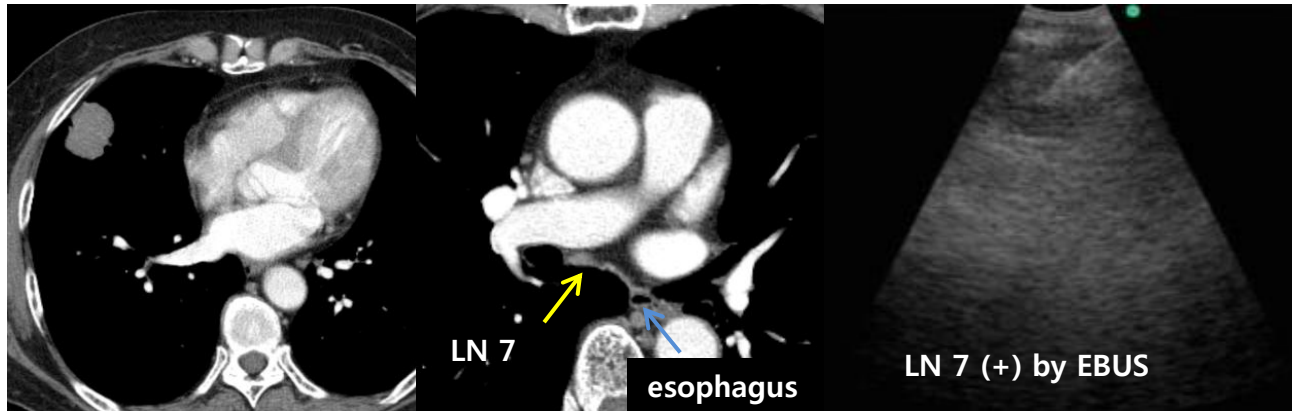
A representative case with additional gain obtained by EUS-FNA in Group A.



In a patient (M/65) with adenocarcinoma in the left lower lobe, EBUS-TBNA on stations 4R, 4L and 7 was negative. EUS-FNA on a deep 4L lymph node diagnosed metastasis. This lymph node was not well visualized by EBUS. N2 disease was confirmed by adding EUS to EBUS.

Supplemental figure 2.

Representative case with additional gain of EBUS-TBNA on nodal station 7 following EUS in Group B.



Nodal station 7 is usually accessible by EUS-FNA. However, we observed several cases with metastasis diagnosed only by EBUS at station 7. In a patient (F/68) with adenocarcinoma in the right middle lobe, EUS-FNA on station 4L was negative. A major part of station 7 was not well visualized by EUS. EBUS-TBNA on the right side of the subcarinal node detected metastasis, which diagnosed N2 disease.