



PULMONARY PUZZLES

A surprising cause of polycythaemia

N E De Maeyer,¹ S Van Lommel,² T Devos,³ B Buyse,¹ K Nackaerts¹

¹Department of Respiratory Diseases, University Hospitals Leuven, Leuven, Belgium

²Department of Psychiatry, University Hospitals Leuven, Leuven, Belgium

³Department of Hematology, University Hospitals Leuven, Leuven, Belgium

Correspondence to

Dr N E De Maeyer, Department of Respiratory Diseases, University Hospitals Leuven, Herestraat 49, Leuven 3000, Belgium; nikolaas.demaeyer@uzleuven.be

Prior publication: The case was presented as a poster at the annual meeting of the Belgian Society of Pneumology (05-12-2015, Brussels Belgium) and won the second prize in the J.C. Yernault award. <https://www.bvp-sbp.org/index.php/nl/awards-fellowships/jcynl>

Received 9 March 2016

Revised 5 June 2016

Accepted 7 June 2016

To cite: De Maeyer NE, Van Lommel S, Devos T, et al. *Thorax* Published Online First: [please include Day Month Year] doi:10.1136/thoraxjnl-2016-208610

CASE PRESENTATION

A 48-year-old man was referred to the outpatient clinic because of fatigue and an elevated haemoglobin level of 19.4 g/dL. His relevant medical history only revealed psychosis. He had quit cigarette smoking for several years. His daily medication schedule consisted of valproic acid 1500 mg, quetiapine 400 mg and lormetazepam 1 mg daily. There were no clinical abnormalities besides a body mass index of 28.3 kg/m².

Since primary erythrocytosis was not excluded initially, venesections were performed three times. Meanwhile, diagnostic work-up took place. Serum erythropoietin levels and V617F JAK-2 mutation were normal. Red blood cell mass nuclear scintigraphy showed an absolute elevation in red blood cell mass. Bone marrow examination, chest X-ray,

abdominal ultrasound and functional cardiopulmonary evaluation were non-diagnostic.

Because of fatigue and significant weight gain, a polysomnography was performed, showing moderate obstructive sleep apnoea with an apnoea-hypopnoea index of 19/hour of sleep. Oxygen desaturation below 90% occurred during 74 min, with an absolute minimum of 86%. Following regulations in our country, CPAP therapy was not reimbursed. Therefore, we opted for conservative treatment with weight loss, which was hard to achieve. His polycythaemia persisted despite his efforts.

QUESTION

What is the missing element in his medical record and what would be your next investigation to complete the diagnosis?

ANSWER

After a more profound history taking, we found out that he was a regular water pipe smoker, smoking about 90 min/day. Carboxyhaemoglobin ratio proved to be 13.7% on arterial blood gas analysis (normal range for heavy smoker: 7%–9%). A patient-tailored smoking cessation programme was offered and the patient succeeded in quitting smoking with the aid of a trained psychologist and an electronic cigarette. Following smoking cessation, haemoglobin levels returned within normal limits (figure 1).

DISCUSSION

Secondary polycythaemia has a wide range of possible aetiologies, among which smoker's polycythaemia has been discovered decades ago.¹ In the Western world, smoking is usually understood as cigarette or cigar smoking. However, water pipe smoking has increasing user rates in Western countries.²

In our case, only a more profound history taking revealed his actual smoking habits. The patient saw no harm in his smoking behaviour. Yet, several epidemiological and other studies suggest otherwise.³ The significant lowering of haemoglobin

concentration and expired carbon monoxide measurements after successful smoking cessation, suggest a causal link between water pipe smoking and polycythaemia in our patient. In literature, we found two case reports with similar findings to ours.^{4 5}

Contributors SVL, TD, BB and KN treated the patient. NEDM performed the literature research. All authors wrote and corrected the manuscript in a substantial way. BB and KN contributed equally to the manuscript.

Competing interests None declared.

Patient consent Obtained.

Provenance and peer review Not commissioned; externally peer reviewed.

REFERENCES

- 1 Smith JR, Landaw SA. Smokers' polycythemia. *N Engl J Med* 1978;298:6–10.
- 2 Primack BA, Freedman-Doan P, Sidani JE, et al. Sustained waterpipe tobacco smoking and trends over time. *Am J Prev Med* 2015;49:859–67.
- 3 El-Zaatari ZM, Chami HA, Zaatar GS. Health effects associated with waterpipe smoking. *Tob Control* 2015;24(Suppl 1):i31–43.
- 4 Tadmor T, Mishchenko E, Polliack A, et al. Hookah (narghile) smoking: a new emerging cause of secondary polycythemia. *Am J Hematol* 2011;86:719–20.
- 5 Bonadies N, Tichelli A, Rovó A. When water does not clear the smut from the smoke. *BMJ Case Rep* Published 18 Oct 2013. doi:10.1136/bcr-2013-200665

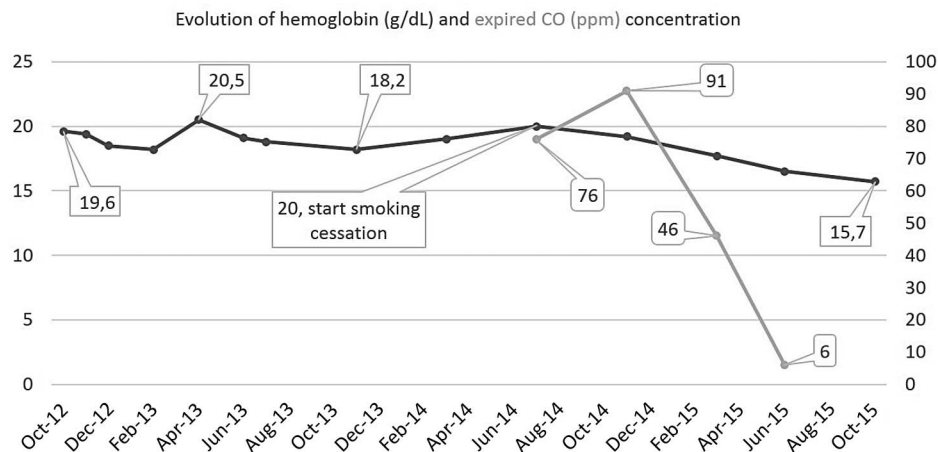


Figure 1 Evolution of serum haemoglobin (g/dL, black line) and expired carbon monoxide (ppm, grey line) concentration over time.