



PULMONARY PUZZLES

Acute respiratory distress syndrome or pulmonary oedema?

Yi-Ting Chen,¹ Wei-Kai Wu,² Yung-Hsiang Hsu³

¹Department of Internal Medicine, Buddhist Tzu Chi Hospital and Tzu Chi University, Hualien, Taiwan

²Department of Internal Medicine, National Taiwan University Hospital, Taipei, Taiwan

³Department of Pathology, Buddhist Tzu Chi Hospital and Tzu Chi University, Hualien, Taiwan

Correspondence to

Dr Yi-Ting Chen, Department of Internal Medicine, Buddhist Tzu Chi Hospital and Tzu Chi University, 707, Sec. 3, Chung-Yang Rd., Hualien 97002, Taiwan; yitingchen@tzuchi.com.tw

Received 15 January 2015

Revised 13 February 2015

Accepted 13 February 2015

CASE PRESENTATION

A 51-year-old woman who was a smoker presented to our emergency department with acute respiratory distress. Two months previously she had developed dyspnoea aggravated by exertion and a dry cough. Orthopnoea, leg oedema and resting dyspnoea had deteriorated 3 days prior to this presentation. There was no chest pain, fever, anorexia, abdominal pain or body weight loss. On examination she was obese and normotensive. A non-rebreathing oxygen mask was necessary to maintain her oxygen saturation (SpO₂) at >90%. She had diffuse lung crackles, elevated jugular veins and pretibial pitting oedema. There was no heart murmur or gallop sounds. The ECG showed sinus tachycardia of 115 bpm. Routine blood tests showed no remarkable findings except D-dimer of 2019 ng/mL. The serum procalcitonin level was normal. Chest radiography showed a bilateral alveolar pattern, compatible with pulmonary oedema (figure 1A). CT showed no lymphadenopathy or pulmonary embolism, but a thickened interlobular septum mixed with ground glass opacities (figure 1B). Cardiac sonography showed normal left ventricular systolic function but leftward shift of the interventricular septum. Right heart catheterisation measured systolic pulmonary artery pressure of 68 mm Hg, pulmonary capillary wedge pressure of 10 mm Hg and cardiac index by the thermodilution method of 3.2 L/min/m². All microbiological and immunological surveys showed negative results. The lung patches in the chest X-ray and the arterial oxygen tension/fractional inspired oxygen ratio improved initially after the administration of diuretics and mechanical ventilator use but deteriorated over the following days.

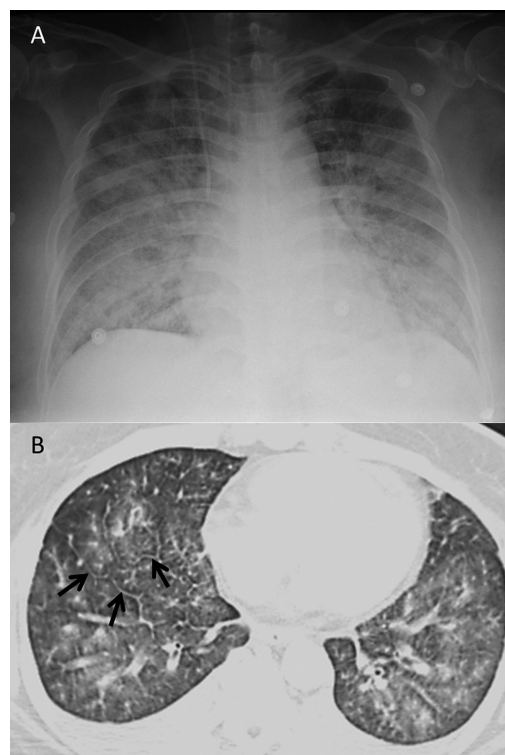


Figure 1 (A) Chest X-ray showing patterns of pulmonary edema. (B) CT scan showing thickened interlobular septum (arrows) mixed with ground glass opacities distributed along the bronchovascular bundles.

QUESTION

What is the diagnosis and cause of death?

To cite: Chen Y-T, Wu W-K, Hsu Y-H. *Thorax* Published Online First: [please include Day Month Year] doi:10.1136/thoraxjnl-2015-206806

ANSWER

Pulmonary tumour thrombotic microangiopathy (PTTM).

Signet ring cells were identified on pleural effusion cytology. Gastric endoscopy showed a 5 cm irregular ulcer at the posterior wall of the antrum and the biopsy confirmed adenocarcinoma. Two weeks later the patient died of progressive hypoxaemia and right heart failure. Necropsy of the lung confirmed the diagnosis of PTTM (figure 2).

DISCUSSION

PTTM is an under-recognised clinicopathological entity which occurs in 3.3% of postmortem carcinoma cases. About 60% of PTTM cases originate from gastric cancer. Among patients with gastric adenocarcinoma the incidence can be as high as 26%.^{1 2} Microscopic tumour emboli in the pulmonary vessels may damage the endothelium, activate the coagulation system and lead to fibrocellular intimal proliferation. Tumour cells are often detectable in periarterial lymphatics.¹ The clinical manifestation includes dyspnoea, cough and signs of subacute cor pulmonale. The plain chest X-ray often shows bilateral infiltration, and CT findings include ground glass opacity, tree-in-bud pattern, thickening of bronchovascular bundles and pleural effusion.² Thickening of the interlobular septum indicates concurrent lymphangitic carcinomatosis. From a combination of the clinical presentation, image findings and the appearance of pulmonary hypertension, the differential diagnosis should include pulmonary veno-occlusive disease in addition to PTTM.³ The clinical diagnosis can be made by pulmonary microvascular cytological examination of samples drawn through a wedged pulmonary artery catheter, transbronchial lung biopsy or open lung biopsy.⁴ PTTM is almost universally fatal; the median survival time from oxygen supplementation is about 9 days.^{2 5} Treatment targeting the primary tumour remains the only therapeutic option, but it is usually prevented by the poor performance status of the patient.⁵

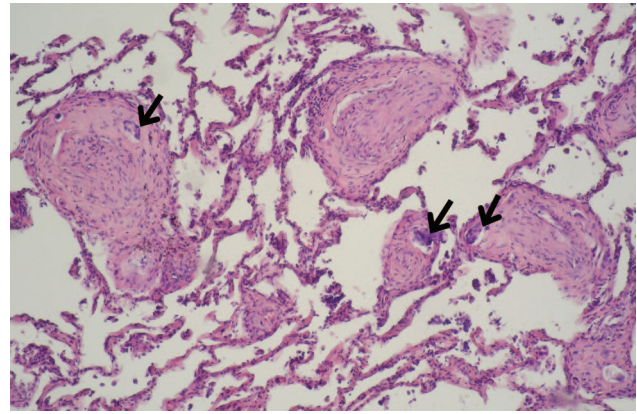


Figure 2 Obliterated arterioles with fibrointimal proliferation and tumor emboli (arrows) (H&E, ×100).

Contributors Y-TC cared for the patient, formed the clinical reasoning and wrote the article. W-KW cared for the patient. Y-HH made the pathological diagnosis and contributed microscopic pictures.

Competing interests None declared.

Patient consent Obtained.

Provenance and peer review Not commissioned; internally peer reviewed.

REFERENCES

- 1 von Herbay A, Illes A, Waldherr R, *et al*. Pulmonary tumor thrombotic microangiopathy with pulmonary hypertension. *Cancer* 1990;66:587–92.
- 2 Uruga H, Fujii T, Kurosaki A, *et al*. Pulmonary tumor thrombotic microangiopathy: a clinical analysis of 30 autopsy cases. *Intern Med* 2013;52:1317–23.
- 3 Montani D, Price LC, Dorfmueller P, *et al*. Pulmonary veno-occlusive disease. *Eur Respir J* 2009;33:189–200.
- 4 Masson RG, Krikorian J, Lukl P, *et al*. Pulmonary microvascular cytology in the diagnosis of lymphangitic carcinomatosis. *N Engl J Med* 1989;321:71–6.
- 5 Gavin MC, Morse D, Partridge AH, *et al*. Clinical problem-solving. Breathless. *N Engl J Med* 2012;366:75–81.