

## Images in Thorax

## Coral broncholith associated with cystic bronchiectasis

We present an unusual type of broncholithiasis complicated with cystic bronchiectasis. Chest CT scans showed cystic bronchiectasis with fluid collection in the right lower lobe and calcification was also detected in the right lower bronchus (figure 1A,B). Bronchoscopy showed a 'coral' broncholith arising from the right lower bronchus (figure 2A,B).

Broncholithiasis is commonly caused by erosion and extrusion of a calcified adjacent lymph node into the bronchial lumen,

## Learning points

- ▶ This case is the first report of the 'coral' broncholith.
- ▶ Cystic bronchiectasis might be associated with the broncholith formation.

a finding usually associated with tuberculosis or histoplasmosis.<sup>1</sup> In the present case, cystic bronchiectasis might be associated with broncholith formation.

**Toru Kadowaki, Shuichi Yano, Toshikazu Ikeda**

Department of Pulmonary Medicine, National Hospital Organization Matsue Medical Center, Matsue, Shimane, Japan

**Correspondence to** Toru Kadowaki, Department of Pulmonary Medicine, National Hospital Organization Matsue Medical Center, 8-31, 5 cho-me, Agenogi, Matsue, Shimane 690-8556, Japan; toruyan@matsue.hosp.go.jp

**Competing interests** None.

**Patient consent** Obtained.

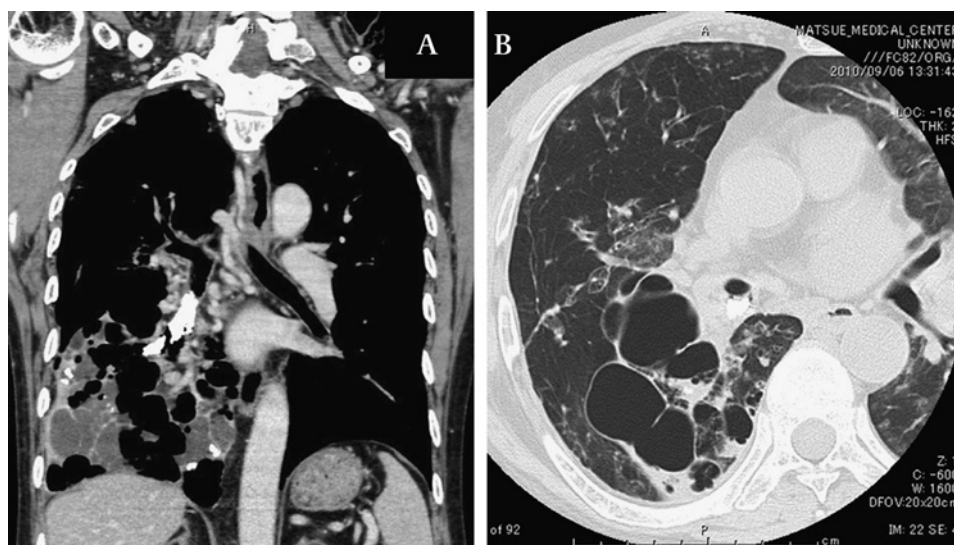
**Provenance and peer review** Not commissioned; externally peer reviewed.

Accepted 18 April 2011

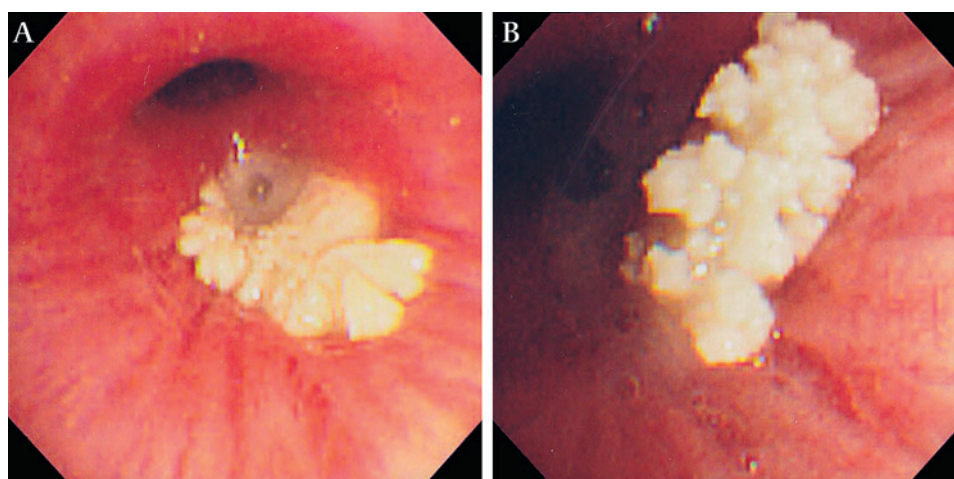
*Thorax* 2011; **66**:1. doi:10.1136/thoraxjnl-2011-200304

## REFERENCE

1. **Seo JB**, Song KS, Lee JS, *et al*. Broncholithiasis: review of the causes with radiologic-pathologic correlation. *Radiographics* 2002;**22**:S199–213.



**Figure 1** (A) Coronal section of chest CT. Calcified lesion is seen in the lower bronchus. Cystic lesion is evident in the right lower lobe. (B) Chest CT showing cystic bronchiectasis in the right lower lobe.



**Figure 2** (A,B) Bronchoscopy showing 'coral' broncholith arising from the right lower bronchus.