Thorax (1954), **9**, 159.

THE MORPHOLOGICAL AND PATHOLOGICAL SIGNIFICANCE OF SYNOSTOSIS AT THE MANUBRIO-STERNAL JOINT

BY

G. T. ASHLEY

From the Department of Anatomy, The University of Manchester

(RECEIVED FOR PUBLICATION OCTOBER 16, 1953)

Accepted teaching concerning the time and nature of synostosis of the manubrio-sternal joint is, generally speaking, erroneous.

In agreeing with Fallopius and Eustachius, Coiter (1573) showed justifiable caution in stating that synostosis of this joint appears at the time at which the cranial sutures begin to be obliterated. This, of course, can mean any time after 30 years.

Anatomists of the seventeenth and eighteenth centuries (Crooke, 1615 ; Highmore, 1651 ; Bartholinus, 1668 ; Bidloo, 1685 ; Weitbrecht, 1742 ; Winslow, 1756 ; Monro Primus, 1758) were more definite, but less justified, in stating that the sternum is " not one bone, unless it be in very old men " (Crooke).

Despite a steadily growing mass of evidence which shows that fusion at this joint is a phenomenon by no means peculiar to old age, modern textbooks still adhere to the old teaching. For example, one may quote Latarjet (1928), who states that fusion of the manubrium and body of the sternum occurs " dans l'extrême vieillesse seulement "; Johnston and Whillis (1949) say that it " occasionally becomes ossified in advanced life "; Jones (1949) that " the manubrium usually remains permanently separate unless in advanced life, when it may become ankylosed to the body "; and Walmsley (1951) that, (infrequently) " the joint is obliterated by synostosis in old age."

However, at least one modern anatomist (Grant, 1944) gives credit to Trotter (1934), who found from study of 877 sterna that there is " no correlation . . . between the incidence of synostosis and age." Even before Trotter published her findings evidence had accumulated to show the fallacy of the accepted teaching concerning this joint. Paterson (1904) in his monograph stated, " It [synostosis] occurs in 8.8% of the 642 sterna examined. Its frequency increases with age. Fusion occurs in 3.1% of sterna under 30, in 10.5% between 30 and 49, and in 15.6% between 50 and 82. At the same time it is not altogether a senile condition. Among 46 sterna between 61 and 82, union of the presternum and the mesosternum only occurs four times (8.7%)." Paterson chose to group his sterna in age groups of varying range and not in regular 10-year groups as did Trotter and other later investigators. Accordingly, I have re-examined his material to ascertain the incidence of synostosis in 10-year age groups in his series also. The findings are reported below.

Van Gelderen (1924), in a study of 132 sterna, found synostosis of this joint in a girl of 12 years and, further, stated that from 30 years onwards the frequency of synostosis remains constant up to old age. He believed that synostosis generally appeared before 40 years of age.

Pässler (1931) reported on his study of 1,000 sterna in which he found the incidence of synostosis constantly between 5 and 8% in all decades from the fourth to the eighth.

Frey (1935) examined 100 sterna and stated that manubrio-sternal synostosis is to be found in all age groups, though somewhat more frequently in old age.

The work of Trotter, van Gelderen, and Pässler, combined with my own re-arrangement of Paterson's findings, plus personal findings from study of a further 228 sterna, represent a combined study of 2,787 specimens from subjects of known age between 1 and 90 years. This is a large enough series to justify, from the consistency of the findings, some modification of the over-simplified and indeed erroneous textbook teaching that synostosis of this joint is found only in advanced life.

However, even after acknowledging the undoubted fact that the condition is not necessarily a senile change, the problem remains as to why synostosis of this joint should occur at all. Without doubt, movement at the joint is physiologically necessary for optimum respiratory function, and it is strange that the joint should become functionless so early in life in about 10% of individuals.

As part of a general anatomical and morphological study of the sternum I have sought to find an answer to this problem, both through a review

TABLE I

NUMBERS AND PERCENTAGES OF INDIVIDUALS WITH SYNOSTOSIS AT THE MANUBRIO-STERNAL JOINT IN 10-YEAR-AGE GROUPS

Observer		Age Groups									Total	
		1–9	10–19	20–29	30–39	40–49	50–59	60–69	70–79	80–89	No.	%
Van Gelderen (1924)		—	1/31	0/10	2/11	2/16	2/20	3/20	2/17	1/7	13/132	9·9
Pässler (1931)		0/26	0/38	2/129	7/97	7/124	17/228	16/212	9/118	0/28	58/1000	5·8
Trotter (1934)		—	0/14	5/73	8/99	22/157	12/152	25/192	23/130	4/32	99/849	11·7
Author: African Series		—	0/7	4/34	4/26	2/14	2/8	2/6	1/3	—	15/98	15·3
Manchester ,,		0/20	0/7	1/6	1/12	4/10	3/18	3/23	3/26	1/8	16/130	12·3
Liverpool ,,		0/24	2/72	6/82	13/132	14/124	18/86	4/44	1/12	0/2	58/578	10·0
Totals	No.	0/70	3/169	18/334	35/377	51/445	54/512	53/497	39/306	6/77	259/2787	
	%	0·0	1·8	5·4	9·3	11·5	10·6	10·6	12·7	7·9		9·3

of the literature and in a personal examination of a large series of sterna ranging in age from early foetal stages to advanced senility.

MATERIALS AND METHODS

Altogether I have examined a total of 1,400 sterna, in 1,138 of which the age was known. Of these latter, 683 were dry adult sterna cleaned of all ligaments and cartilage by boiling and scraping, 143 were immature post-natal specimens, and 312 were foetal.

Concerning the specimens of known age, the adult material included 91 in the Galloway collection of East African skeletons at Makerere College, Uganda, 489 belonging to the Paterson collection at Liverpool University and kindly made available for my use by Professor Harrison, and 103 in my own collection obtained through the courtesy of pathologists in the Manchester area.

Of the 143 immature post-natal sterna seven were East African, 102 were in the Paterson (Liverpool) collection, and the remaining 34 are in my own (Manchester) collection.

Of the foetal sterna 76 are in my own series ; and relevant details concerning the remaining 236 have been extracted from the full and well-illustrated manuscript records left by Professor A. M. Paterson at Liverpool.

In 1,050 instances, radiographs were taken to seek more detailed evidence of the nature of union between adjacent parts of the sternum. In 50 foetal specimens sections were cut to establish the presence or absence of a fibrous lamina at the level of the second costal cartilages.

Of the 1,050 sterna radiographed 113 were foetal or infantile, 143 were from children and adolescents, 683 were from adults, and 111 were unclassed.

In adult specimens with ligaments and cartilage removed by boiling and scraping, synostosis between pre- and meso-sternum was best ascertained by inspection alone. If necessary the specimen was dissected and if doubt remained the joint was forcibly broken open and its true nature thus revealed. This procedure is essential, because radiographs alone can be misleading, especially when one is examining museum material. In Fig. 2 (C, H, and J) are shown three radiographs in which the appearances of the joint are very similar and all suggest early synostosis. In specimen (C) this impression is justified, but in specimen (J) the appearance is due to osteoarthritic lipping of the lower end of the manubrium which extends into the anterior ligament of the joint, and in specimen (H) the appearance of synostosis is produced by a little adhesive which had been applied to hold the bones together. All such sources of error have been excluded in this series. The main value of the radiographs was in determining the extent and nature of osseous union where such existed. On the other hand, in immature post-natal and foetal specimens with cartilaginous elements still intact radiography was often essential to determine the presence or absence of osseous union across the junctional region.

FINDINGS

Table I summarizes my own findings concerning the incidence of synostosis at the manubrio-sternal joint together with the results of previous workers.

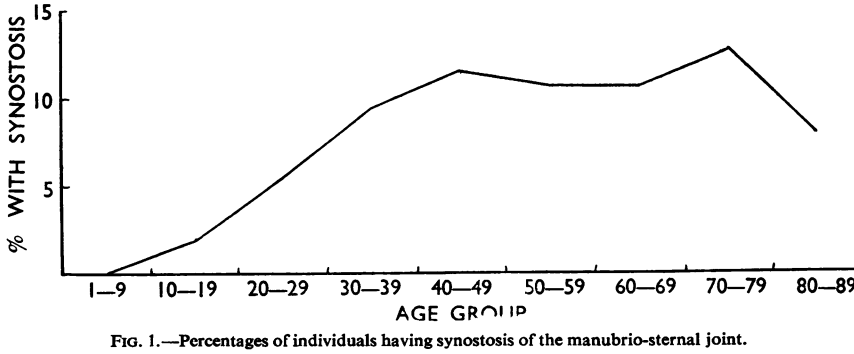

FIG. 1.—Percentages of individuals having synostosis of the manubrio-sternal joint.

All sterna from subjects in which the age was not specified were necessarily excluded in compiling this Table, so the total reported on is less than the total of sterna examined.

From the grand totals obtained from these investigations Fig. 1 has been prepared to show, graphically, that the incidence of synostosis at the manubrio-sternal joint is almost uniformly found to be about 10% in individuals dying from age 30 onwards. It is, of course, important to bear in mind the fact that the conditions found in individuals coming to necropsy at certain ages do not necessarily represent the average conditions which would be found could one examine this joint in the living of the same age groups. Nevertheless, as it is unusual for people to live beyond the age of 90, the incidence of synostosis in octogenarians coming to necropsy may reasonably be considered to be the average for all octogenarians. As the incidence of synostosis in octogenarians in this series is only 7.9%, whereas it has already reached 9.3% in those dying in the fourth decade, the inference one is tempted to make is that a freely-movable manubrio-sternal joint is conducive to longevity.

The reverse would seem to be true in respect of those in whom the joint becomes synostosed early in life, as facts brought out in the following discussion reveal.

Discussion

It is a well-recognized fact that the sternum develops from a variable number of ossification centres (Paterson, 1904; Markowski, 1905; Ashley, 1953). These centres are segmentally arranged in sets of one, two, or more per segment. In each segment the centres may be single and median; paired (laterally, obliquely, or vertically), or multiple and irregularly disposed. All the centres are endochondral, being embedded in a mass of cartilage which presents, approximately, the shape of the definitive sternum. Normally, according to Ruge (1880) and Paterson (1904), during foetal life the presternum becomes demarcated from the mesosternum by a fibrous lamina which develops across the cartilaginous sternum at the level of the second costal cartilages. This fibrous lamina is the anlage of the secondary cartilaginous joint which is usually found between manubrium and mesosternum in the adult. The centres of ossification begin to make their appearance about the sixth month of intra-uterine life. Adjacent centres may arise in lesser or greater proximity to each other. The more closely placed centres may coalesce in the late foetal or early post-natal months of life, as is apparent from the series of radiographs shown in Fig. 2, in which (O) shows early coalescence of paired lateral centres in the third segment in a child of 1 year 8 months; (M) and (N) show coalescence of centres from adjacent segments in an infant of 2 months and an infant of 5 months respectively. At this stage, very rarely, one may even observe coalescence between the manubrial and first mesosternal ossification centres. I have seen only two definite cases of this occurrence, both in full-term foetuses, and the radiographs are shown at (P) and (Q) in Fig. 2. The rarity of this occurrence is in part due to the wide gap which normally separates the manubrial and first mesosternal centres (see M and N, Fig. 2) and in part to the normal development of the fibrous lamina previously referred to.

If, as is commonly the case, adjacent centres of ossification in the mesosternum fail to coalesce in these early months, then the portions of the bone derived from each ossification centre tend to retain some degree of independence for many years as revealed by radiographs of adolescent and young adult sterna (e.g. A, B, Fig. 2). In a series of 100 adult East African sterna I found evidence of the pattern of ossification in 65% (Ashley, 1951). However, as a general rule, the different segments of the mesosternum appear, to the naked eye, to lose their identity and to fuse into one bone before the age of 25. This process of fusion tends to proceed gradually in a caudo-cephalad direction throughout the years of childhood and adolescence, and is simply occasioned by the mutual growing together of the portions of bone developed from each centre with coincident disappearance of the primary cartilaginous joints between them. It is, therefore, justifiable to suggest that in those cases where a fibrous lamina fails to develop between the manubrium and mesosternum the mutual growing together of the manubrial and first mesosternal ossification centres may proceed so far as to produce fusion across the plane of the usual joint line. In this connexion I consider that we should attach greater importance to Paterson's findings concerning the nature of the manubrio-sternal joint in foetuses than did Paterson himself. He found, from a study of 236 foetal sterna, that the junctional region between manubrium and mesosternum is "fibrous" in 76.4% of cases and "cartilaginous" in 23.6%. The term "cartilaginous" as distinct from "fibrous" implies that the joint is a primary cartilaginous joint in 23.6% of cases. Rarely, as Paterson pointed out, the fibrous lamina across the cartilaginous foetal sternum is found at the level of the third costal cartilage instead of at the level of the second. Paterson attributes the

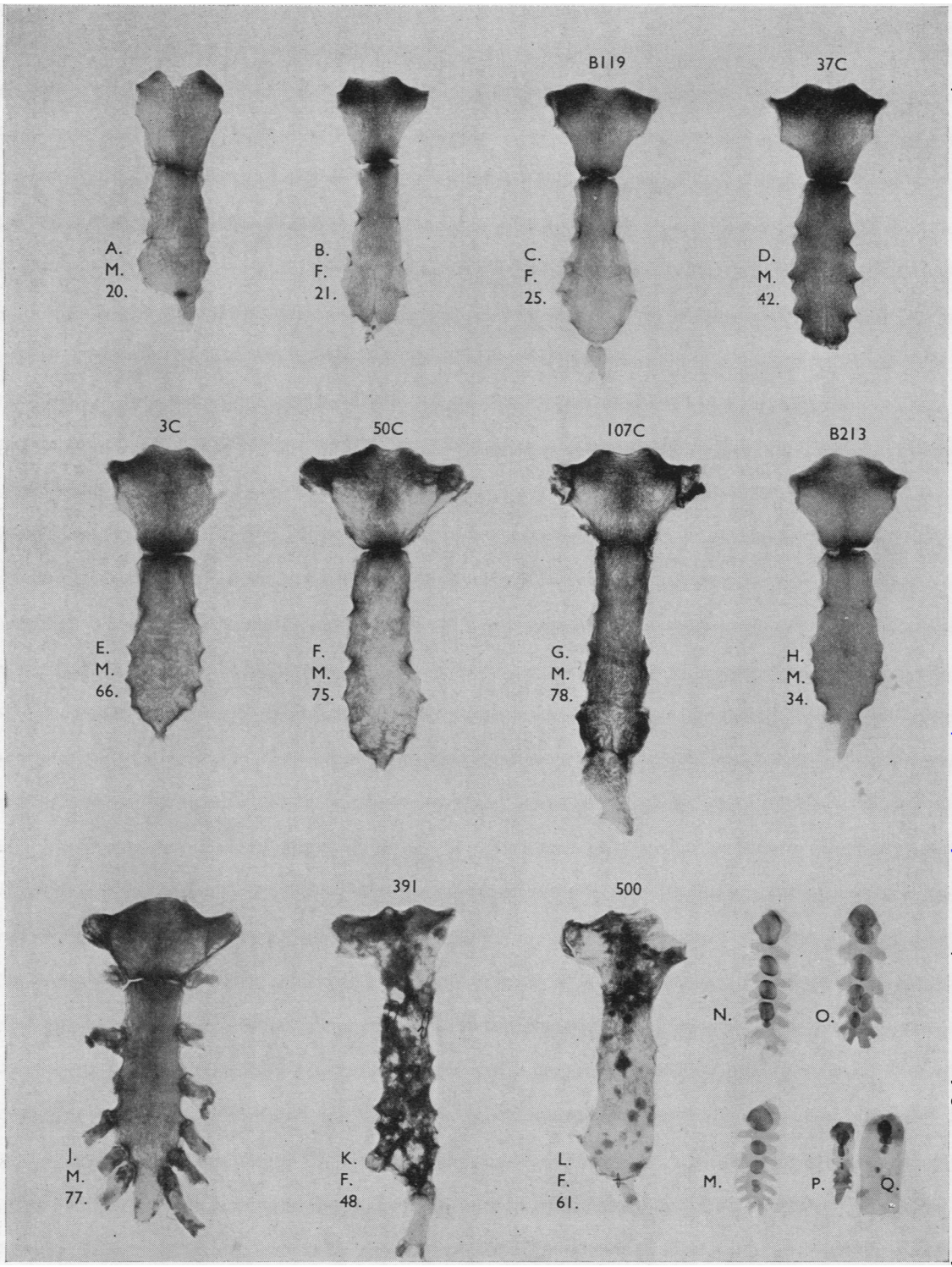

FIG. 2.—A, B, C, D showing examples of normal cortical type of synostosis referred to in the text; E, F, G showing sclerotic synostosis; H showing artificial union by adhesive; J showing osteoarthritic lipping; K, L showing synostosis in pathological specimens; M, N, O, P, Q foetal or infant specimens (for details see text). The age and sex of each specimen are indicated.

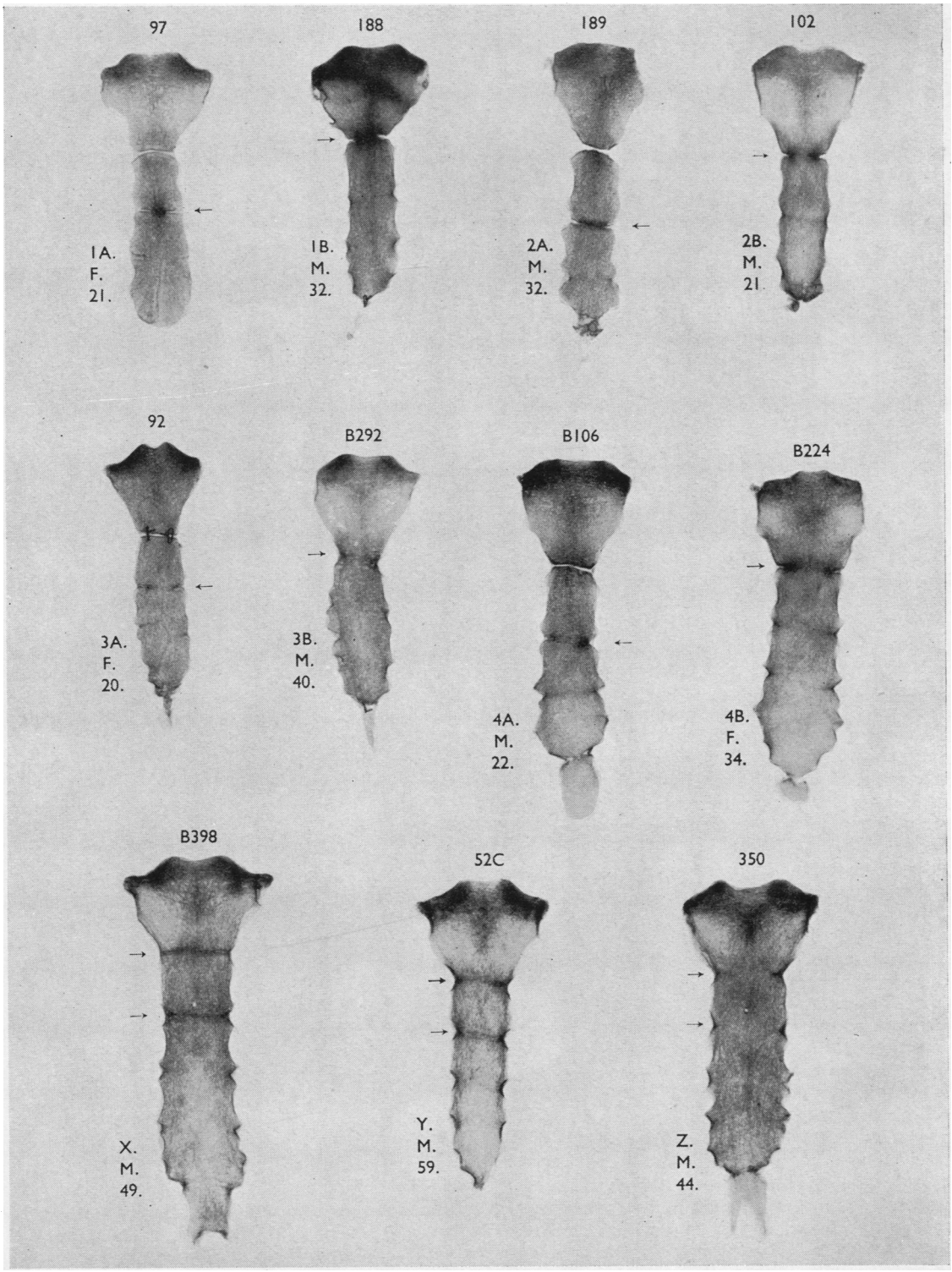

FIG. 3.—Radiographic evidence of the similarity in the nature of normal union between first and second mesosternal segments and abnormal union between manubrium and mesosternum. This is the matrical type of synostosis referred to in the text. The age and sex of each specimen are indicated.

occasional finding of a so-called hylobatian (Keith, 1896) type of sternum in man to this accidental alteration in position of the fibrous lamina. The absence of the lamina at the level of the second costal cartilage permits of fusion between presternum and first mesosternal segment. All such cases I have included, in my series, as showing synostosis between manubrium and mesosternum. This is physiologically wrong but anatomically justified. Paterson expressed the following opinion, " There is, therefore, a possibility at least that all cases of this sort may be congenital in origin." He could have developed this argument further, particularly in view of the opinion expressed by Lane (1887), who from an unstated number of observations reported the finding of synostosis of the manubrio-sternal joint in post-mortem studies of labourers who were used to carrying heavy loads. He made the somewhat unorthodox suggestion that the defect might be transmitted to the progeny of such labourers. His next comment is, however, worthy of more serious consideration: ". . . in such a case the manubrium unites with the gladiolus in the same way as do the separate centres of the gladiolus though at a later period, a joint being at no time developed in this position. The union in such cases takes place before the subject has reached thirty years of age." Lane apparently based this opinion upon observing that " the proportions of such conditions of spontaneous union of the manubrium with the gladiolus appear to be much more commonly present in dissecting-room subjects than they are in the better or less heavily worked class of subjects examined in the post-mortem room of a general hospital." Ignoring the contention that the feature of synostosis at this joint is a transmissible acquired characteristic in labouring families, Lane's conception of the manner of development of synostosis before the age of 30 is fundamentally correct. Evidence for this is to be found in Paterson's observations, if one carries his argument to its logical conclusion. If the absence of a fibrous partition between presternum and first mesosternal segment can lead to fusion of these two elements as Paterson asserts, then absence of a fibrous partition at any level across the sternum can equally well lead to fusion of all elements of the sternum into one bone. This argument is in complete conformity with the accepted anatomical principle that the primary type of cartilaginous joint is, generally speaking, a "temporary" joint, in which the cartilage normally ossifies or calcifies during puberty, adolescence, or early adult life. This type of joint is exemplified by the epiphysial joints of long bones or by the cartilage between the first and second mesosternal segments, and in many cases by the first costal cartilages. The very definite findings of Trotter, van Gelderen and others, supported by my own observations, prove beyond doubt that synostosis of the manubrio-sternal joint is as common in the fourth decade as later in life. This fact may well be due, primarily, to the fact revealed indirectly by Paterson, and elaborated above, that in some 20% of individuals conditions are favourable for synostosis to occur. By this I mean that the primary cartilaginous joint persisting in some 20% of individuals forms no obstacle to the fusion of manubrium and mesosternum, whereas in nearly 80% the " normal " development of a secondary cartilaginous joint will effectively prevent such osseous union, unless pathological processes intervene.

Further, in the younger adult material, radiographs reveal that the appearances of the various stages of fusion between manubrium and mesosternum are strictly comparable to the appearances at corresponding stages in the fusion between first and second mesosternal segments. This point is clearly demonstrated by the series of radiographs shown in Fig. 3. Each sternum figured reveals partial or complete continuity of spongy bone between manubrium and mesosternum, hence I call this type " matrical " synostosis. In each pair of sterna shown, the appearance of the pre-mesosternal joint in (B) should be compared with the appearance of the joint between mesosternal segments 1 and 2 in (A). In the three sterna marked X, Y, and Z on Fig. 3 both joints are synostosed to an equivalent degree in each sample, and the one joint cannot be distinguished from the other either by the extent or the nature of the synostosis.

The matrical type of synostosis occurred in 80% of the cases of synostosis under 60 years, and in only 60% of the cases over 60. The condition in the remaining cases I refer to as the " cortical " type of synostosis. In them, a line or band of compact bones unites the manubrium to the mesosternum, but separates the spongy matrix of the one from the spongy matrix of the other. Examples of this type are shown in Fig. 2 (A–G). The cortical type of union was found in 40% of the cases of synostosis in the over 60s, and in only 20% of those under 60. This type should, I think, be divided into two sub-types, (a) " normal cortical " and (b) " sclerotic " synostosis. In the former, the fusion line on the radiograph is produced by the cortical bone of a healthy manubrium synostosing with the cortical bone of a healthy mesosternum, and probably represents the first stage in fusion

leading to matrical synostosis. In the sclerotic type of fusion one assumes that chronic infection or arteriosclerosis has led to sclerotic change in the opposing bony surfaces, to degeneration and attrition of the fibro-cartilage, and to ultimate loss of movement and synostosis at the joint. Probably, the sclerosed bone at the site of union will remain almost indefinitely in these cases. One cannot always differentiate with certainty between normal cortical and sclerotic types of synostosis, but I have gained the impression that cortical synostosis occurring in younger adults is of the normal type, whereas in older people it is more frequently of the sclerotic type. The radiographs in Fig. 2 (A–G) lend some support to this view.

In two sterna of the Liverpool collection the radiographs indicated that in each the bone had been extensively involved in some pathological process. In these cases the disease may have been the cause of fusion between manubrium and mesosternum. These specimens are shown in Fig. 2 (K, L).

On the basis of the classification outlined above it was found that the more complete (i.e. the matrical) type of synostosis and the normal cortical type of synostosis were found mainly in younger adults, and would seem to be the result of ossification invading and obliterating a primary cartilaginous joint. The sclerotic type of synostosis is more justifiably termed a senile phenomenon and probably results from a variety of causes in which osteoarthritis figures largely (Pässler). Lane (1887) and Pässler have suggested that prolonged heavy work, involving the carrying of loads on the back, may be an aetiological factor in the causation of synostosis of this joint.

We have in the literature several statements concerning manubrio-sternal synostosis, which are worthy of quotation in chronological sequence.

Paterson (1904) said " . . . it is not altogether a senile condition "; van Gelderen (1924) considered that synostosis occurs before the fortieth year, and asserts, " Eine Greisenaltersynostose existiert nicht "; Pässler (1931) recognized an innate tendency for the development of synostosis in some cases, " Das Fehlen der Bandscheiben ist in manchen Fällen die Folge einer sekundär eingetretenen Verknöcherung, in anderen Fällen aber sicher angeboren."

I would go further and assert that in something under 20% of all individuals synostosis of the manubrio-sternal joint will inevitably occur in early adulthood because of the failure of development during foetal life of the fibrous lamina between manubrium and mesosternum.

The relative infrequency of the matrical type of synostosis in the aged at once suggests that individuals whose sterna show this type of synostosis tend to die before reaching old age. The obvious inference is that, either the illness from which the individual suffered caused synostosis of the manubrio-sternal joint, or that an existing synostosis of the manubrio-sternal joint was a factor predisposing to contraction of the specific illness which led to death. I would suggest that the latter alternative is the more acceptable hypothesis. In the first instance, as mentioned above, radiographs of sterna, showing matrical synostosis, present no evidence of local pathological change (see Fig. 3). The synostosis, though its presence is abnormal, nevertheless seems to be formed of perfectly normal bony tissue. Secondly it is a well-recognized fact that absence of mobility at the manubrio-sternal junction interferes with the normal mechanism of respiration (Rothschild, 1907). This interference undoubtedly limits, for example, the force and effectiveness of expectoration. Thirdly, it has been suggested by some observers (Rothschild, 1899; van Gelderen, 1924) that there is a definite connexion between the presence of synostosis at this joint and affliction with pulmonary tuberculosis. Rothschild (1907) even went so far as to advocate operative freeing of a synostosed manubrio-sternal joint in cases where the condition was discovered early. Hart (1907) disagreed with Rothschild's findings. He found only three cases of synostosis in over 400 unselected post-mortem subjects, and attributed two of these to congenital causes. On the other hand, van Gelderen found synostosis in 36% of phthisical subjects.

Unfortunately Paterson left no record of the causes of death in his series, so I am unable to use his material to support either Hart on the one hand or Rothschild and van Gelderen on the other. However, the anatomical findings summarized in this paper warrant an extensive clinico-pathological investigation into a problem which so intimately affects the vital organs of no less than 10% of the population.

Summary

The accepted teaching that synostosis of the manubrio-sternal joint is a senile change should be revised.

Conclusive evidence has accumulated to show that such synostosis is almost equally common in all 10-year age groups after the age of 30.

Synostosis at the manubrio-sternal joint would seem to be of two kinds: (a) primary, " matrical " synostosis, resulting from the obliteration, during

early life, of a primary cartilaginous joint between manubrium and mesosternum, and presumably inevitable; (b) secondary, "sclerotic" synostosis resulting from the obliteration, during late adult life, of a secondary cartilaginous joint between manubrium and mesosternum, and presumably the result of pathological processes.

In 683 sterna of known age the primary or matrical type of synostosis was found three times as commonly as the sclerotic type.

The possibility that the primary or matrical type of synostosis may figure in the aetiology of lung disease, particularly phthisis, is a matter which should be more fully investigated by both clinicians and pathologists.

I wish to thank Professor G. A. G. Mitchell and his staff for much valuable assistance and advice; Professor R. G. Harrison for permitting me to study the Paterson material; Drs. E. L. Patterson and H. Weisl, Miss D. Hahn, Fraulein G. Volken, and Fraulein D. Elst for assistance with translations from Latin and German; Messrs. G. Wild (Uganda), F. L. Newell, G. Graham, and P. Howarth (Manchester) for the radiography and photography; and the staff of the Manchester University Medical School Library for invaluable help with the literature.

BIBLIOGRAPHY

Ashley, G. T. (1951). *J. Anat.*, **85**, 412.
—— (1953). *J. Anat.*, **87**, 439.
Bartholinus, C. (1668). *Anatomy*, p. 353. (Translated into English by N. Culpeper and A. Cole.) London.
Bidloo, G. (1685). *Anatomia Humani Corporis*. Legend to Tab. 95, Fig. V. Amsterdam.
Coiter, V. (1573). Externarum et internarum principalium humani corporis partium tabulae, etc. Cap. 8, pp. 60–61. Nuremburg.
Crooke, H. (1615). *Microcosmographia. A Description of the Body of Man*, p. 743 (collected and translated out of all the best authors of anatomy, especially Caspar Bauhinus and Andreas Laurentius). London.
Eustachius. Cited by Coiter.
Fallopius. Cited by Coiter.
Frey, H. (1935). *Morph. Jb.*, **76**, 516.
Gelderen, C. van (1924). *Z. ges. Anat.*, 2 *Abt. Z. KonstLehre*, **10**, 367.
Grant, J. C. B. (1944). *A Method of Anatomy*, 3rd ed. p. 477. Williams and Wilkins. Baltimore.
Hart, C. (1907). *Berl. klin. Wschr.*, **44**, 842.
Highmore, N. (1651). *Corporis Humani Disquisitio Anatomica*, etc. p. 124. The Hague.
Johnston, T. B., and Whillis, J. (1949). In Gray's *Anatomy*, 30th ed., p. 459. London.
Jones, F. Wood (1949). In Buchanan's *Manual of Anatomy*, 8th ed., p. 145. Baillière, Tindall and Cox, London.
Keith, A. (1896). *J. Anat. Lond.*, **30**, 275.
Lane, W. A. (1887). Ibid., **21**, 586.
Latarjet, A. (1928). In Testut, L., *Traité d'Anatomie Humaine*, 8th ed., vol. 1, p. 565. Paris.
Markowski, J. (1905). *Anat. Anz.*, **26**, 248.
Monro, A. (Primus) (1758). *The Anatomy of the Human Bones and Nerves*, 6th ed., p. 222. Edinburgh.
Pässler, H. W. (1931). *Zeigler's Beitr., path. Anat.*, **87**, 659.
Paterson, A. M. (1904). *The Human Sternum*, Williams and Norgate London.
Rothschild, D. (1899). *Verh. Kongr. inn. Med.*, **17**, 590.
—— (1907). *Berl. klin. Wschr.*, **44**, 836.
Ruge, G. (1880). *Morph. Jb.*, **6**, 362.
Trotter, M. (1934). *Amer. J. phys. Anthrop.*, **18**, 439.
Walmsley, R. (1951). In Cunningham's *Text-book of Anatomy*, 9th ed., ed. Brash, J. C., p. 354, Oxford University Press, London.
Weitbrecht, J. (1742). *Syndesmologia*, Sive Historia Ligamentorum Corporis Humani, p. 120. St. Petersburg.
Winslow, J. B. (1756). *An Anatomical Exposition of the Structure of the Human Body*, vol. 1, p. 149. (Translated by G. Douglas.) 4th ed. London.