



To drain or not to drain? Abscess or empyema?

Helen McDill,¹ Maged Hassan ,² Graham Dack,³ Lindsey Taylor,¹ David Waine,¹ John P Corcoran,¹ Cyrus Daneshvar ¹

ABSTRACT

We present a case posing the clinical dilemma of differentiating a large peripheral lung abscess from an empyema, discussing the imaging and management and the clinical issues posed.

CASE REPORT

Helen McDill (HM): We present a case posing the clinical dilemma of differentiating a large peripheral lung abscess from an empyema. A 71-year-old man attended the emergency department with a 1-week history of sudden onset left-sided chest pain, exacerbated by inspiration and movement. He reported a dry cough, exertional breathlessness and fatigue. He denied fever, weight loss or reduced appetite. He had no significant medical history, but was a 15 pack-year ex-smoker.

On examination, he was stable, afebrile and had poor dentition. Reduced breath sounds and dullness to percussion were noted at the left lung base. Blood tests showed raised inflammatory markers (white cell count (WCC) ($20.7 \times 10^9/\mu\text{L}$), C reactive protein (CRP) (360 mg/L)) with mild anaemia (haemoglobin 101 g/L), hyponatraemia (sodium 130 mmol/L) and acute kidney injury (estimated glomerular filtration rate of 66 mL/min (baseline >90 mL/min)). A chest radiograph showed a large gas-fluid filled cavity in the left mid-zone causing right-sided tracheal shift. Subsequent chest CT demonstrated a 16 cm intrathoracic collection with enhancing borders, occupying most of the left hemithorax (figure 1).

A discussion between the clinical teams ensued to determine whether this was a large peripheral lung abscess or an empyema: the former managed with intravenous antibiotics, postural drainage and consideration of surgical drainage, while the latter requires intercostal chest tube drainage in the first instance. Clinicians were concerned that chest tube drainage could risk a bronchopleural fistula formation if this were to be an abscess.

Cyrus Daneshvar (CD): Patients with lung abscesses and pleural empyema typically present with fever and pleuritic chest pain. Patients with an abscess often report purulent sputum production due to the underlying necrotising lung eroding into the airways. Chest radiographs can appear similar in both conditions with gas-filled cavities identified by an air-fluid level. Cross-sectional imaging is often required to delineate further. Typically, empyemas are described as lentiform and form obtuse angles with the chest wall, whereas a lung abscess tends to be rounded with more acute angles^{1 2}; however, studies show that angle and size of the lesion are unhelpful differentiating between the two

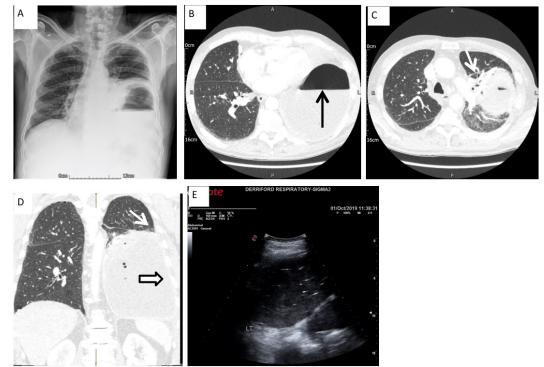


Figure 1 Before percutaneous intervention. (A) Chest radiograph showing a left-sided cavity with air-fluid level and tracheal deviation to the right. (B) Baseline chest CT with contrast, axial cut shows large 16 cm fluid and gas containing cavity occupying most of the left hemithorax with an air-fluid level as shown. (C) Chest CT with contrast, axial cut showing obtuse angle with the lung above the left hilar region and distortion of the pulmonary vasculature and airways (arrow). (D) Baseline chest CT with contrast, coronal cut showing large left collection that is making an acute angle with the chest wall (arrow) and the uniformly thin wall with smooth margins (hollow arrow). (E) Thoracic ultrasound shows multiple hyperechoic shadows inside an echogenic collection above an inverted diaphragm.

pathologies and other factors should be taken into consideration.²

Graham Dack (GD): In addition to the angle and shape of the lesion, cavity wall appearances can be helpful; an abscess wall will typically be thicker and irregular, while the wall of an empyema is usually thinner and smoother.^{1 2} Pleural contrast enhancement can help delineate an empyema resulting in the 'split pleura sign', indicating both visceral and parietal pleura separated by the pleural fluid.² Surrounding lung tissue appearances can also be informative. In empyema, bronchi and vessels of the adjacent pulmonary parenchyma are displaced and compressed around the pleural fluid collection.¹ A lung abscess will cause the bronchi and vessels of the adjacent lung to appear as if they end abruptly at the margins of the abscess.²

HM: In this case, CT appearances were mixed with an acute angle to the chest wall and not following the shape of a pleural-based collection, yet with distortion of the airways and vessels and a thin smooth cavity wall more suspicious of empyema peripherally. Both clinically and radiologically, a large necrotising lung abscess or gas-forming empyema remained differentials. Thoracic ultrasound (TUS) was therefore used to

¹Respiratory Medicine, Plymouth Hospitals NHS Trust, Plymouth, UK

²Chest Diseases Department, Faculty of Medicine, Alexandria University, Alexandria, Egypt

³Radiology, Plymouth Hospitals NHS Trust, Plymouth, UK

Correspondence to

Dr Helen McDill, Respiratory Medicine, Plymouth Hospitals NHS Trust, Plymouth PL6 8DH, UK; h.mcdill@nhs.net

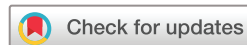Received 7 August 2020

Revised 11 October 2020

Accepted 12 October 2020

Published Online First

11 November 2020



© Author(s) (or their employer(s)) 2021. No commercial re-use. See rights and permissions. Published by BMJ.

To cite: McDill H, Hassan M, Dack G, et al. *Thorax* 2021;**76**:313–315.

try and delineate things further. TUS showed multiple hyperechoic shadows moving within an echogenic fluid collection, with a clear air-fluid level and loss of the curtain sign and lung sliding above this (figure 1).

John P Corcoran (JPC): TUS has changed the way many respiratory and particularly pleural diseases are managed and has many advantages over CT that allows immediate dynamic imaging at the bedside and is now considered a point-of-care test in experienced hands.³ Once only used for detection of pleural fluid, its use has extended recently for detailed examination of the pleural or parietal abnormalities detected on CT, chest wall pathologies, assessment of the pleural space and the underlying lung. When assessing for pleural infection, TUS is helpful to assess the echotexture of the fluid. Homogeneously echogenic effusions tend to occur with haemorrhagic effusions and empyema.³ A less well-known sonographic sign is the 'microbubble' sign, which describes echogenic shadows moving towards the probe and represents air bubbles trapped within the fluid due to either gas-forming organisms in an empyema or the presence of a bronchopleural fistula.³ TUS is also more sensitive than CT at detecting septations in pleural fluid suggesting complex pleural infection.³ TUS can also be used to observe the distal lung parenchyma. Similar to the features on CT, sonographically in the case of an abscess you would observe normal branching airways and airways which would abruptly end at the abscess wall, while in the empyema wall you would only see echogenic compressed lung or distorted airways and vasculature.³ Real-time TUS guidance can be used to direct chest drain placement in experienced hands into the largest locule visualised in complex effusions optimising drainage to prevent the need for surgery and ensuring safe placement; however, this can be more time-consuming and requires more training and experience.³

HM: The constellation of signs seen on CT and thoracic ultrasound continued to give a mixed picture, and the team decided to medically manage the patient as a lung abscess in the first instance. A lung abscess of greater than 6 cm in diameter that has been refractory to medical treatment and/or with the possibility of an underlying bronchopleural fistula should usually be considered for surgical intervention.⁴ Hence, the case was discussed with the cardiothoracic surgical team after clinical and biochemical parameters failed to improve after 5 days on intravenous meropenem. The surgical team felt that surgical intervention of an abscess would possibly lead to a pneumonectomy, with the associated short-term and long-term morbidity and mortality and favoured a conservative strategy in the first instance with chest tube insertion. In discussion with the pleural team, the decision was taken to insert a chest tube under direct ultrasound guidance, accepting the risk of bronchopleural fistula formation and prolonged air leak in the event that this was a lung abscess. A 12F chest tube was inserted and frank pus containing small black fragments of what was taken to be anthracotic lung tissue was drained (figure 2A).

HM: Following the chest drain, the patient developed rigors. His postprocedure chest radiograph showed an appropriately placed chest tube in the pleural space with CT imaging confirming chest tube position, drainage of an empyema and an underlying peripheral lung abscess with necrotising lung (figure 2B). The pleural fluid cultures grew *Parvimonas micra*.

CD: *P. micra* is a Gram-positive anaerobe frequently isolated from dental plaque in patients with chronic periodontitis and is a known cause of lung abscess associated with poor dental hygiene.⁵ This reflects that aspiration of oropharyngeal

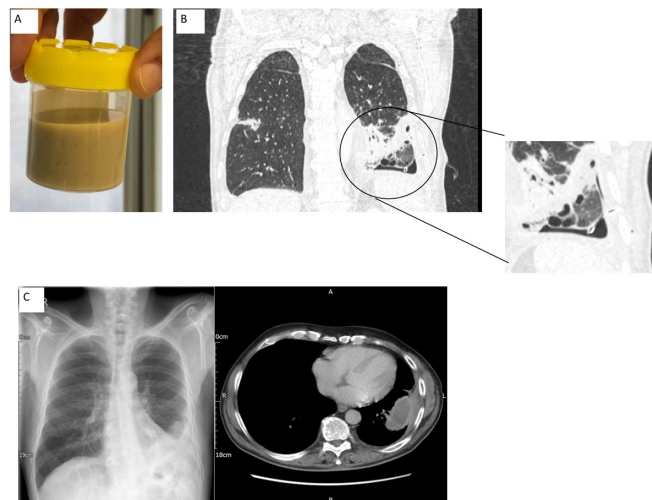


Figure 2 Post percutaneous intervention. (A) Purulent pleural fluid aspirated with anthracotic lung visible. (B) Chest CT with contrast, coronal cut showing chest drain appropriately sited in pleural space with underlying abscess and tissue necrosis. (C) Chest radiograph and axial CT showing excellent resolution with small thick-walled residual collection.

contents is an important risk factor for the development of anaerobic pulmonary infection, compounded by periodontal disease, especially gingivitis that is the most important factor for high-level oral colonisation with anaerobes.

HM: Over the following days, the patient drained 3 L of purulent fluid, while his drain continued to bubble consistent secondary to a bronchopleural fistula. He clinically improved rapidly and his inflammatory markers decreased (CRP 77 mg/L and WCC $9.4 \times 10^9/\mu\text{L}$) by day 6 following intervention. A heimlich flutter valve was fitted to the drain to facilitate discharge from hospital while his bronchopleural fistula healed, the drain was removed 2 weeks following discharge. A total of 3 weeks were spent as an inpatient being treated with intravenous meropenem and percutaneous drainage. He was discharged with an ongoing course of co-amoxiclav to complete 6 weeks and pleural clinic follow-up organised a week after discharge. The duration of antibiotic therapy for both conditions depends on the microbiology, clinical response to drainage and the resolution of the patient's symptoms. While there are no studies directly assessing the length of treatment, expert opinion recommends at least 2–6 weeks for an empyema and 3–6 weeks for a lung abscess taking into consideration the clinical and radiological response in both conditions. At follow-up, his imaging showed excellent resolution of his empyema and lung abscess without the need for further pleural intervention (figure 2C).

CD: This case demonstrated the importance of different imaging modalities to support clinical decision making when delineating between a lung abscess and empyema and how this impacts on management. Prior to draining a lung abscess percutaneously, it is important to know that this is what you are indeed doing and consider options carefully. In this case, a medical strategy resulted in chest tube insertion for a lung abscess that had ruptured into and been contained within the pleural space, resulting in a satisfactory outcome for the patient without the need for more aggressive intervention.

Twitter Maged Hassan @magedhmf

Contributors HM and MH conceived the report. HM, MH, LT, DW, JPC and CD treated the patient. HM and MH collected the images of the report. GD reviewed the radiology of the case. Mr Adrian Marchbank provided the surgical opinion. HM drafted the manuscript. All authors reviewed and approved the final manuscript.

Funding The authors have not declared a specific grant for this research from any funding agency in the public, commercial or not-for-profit sectors.

Competing interests None declared.

Patient consent for publication Obtained.

Provenance and peer review Not commissioned; externally peer reviewed.

ORCID iDs

Maged Hassan <http://orcid.org/0000-0002-8768-6548>

Cyrus Daneshvar <http://orcid.org/0000-0003-0956-8674>

REFERENCES

- 1 McLoud TC, Flower CD. Imaging the pleura: sonography, CT, and MR imaging. *AJR Am J Roentgenol* 1991;156:1145–53.
- 2 Stark DD, Federle MP, Goodman PC, *et al*. Differentiating lung abscess and empyema: radiography and computed tomography. *AJR Am J Roentgenol* 1983;141:163–7.
- 3 Laursen CB, Rahman NM, Volpicelli G. *Thoracic ultrasound (ERS monograph 79)*. Sheffield, UK: European Respiratory Society, 2018.
- 4 Zhang J-H, Yang S-M, How C-H, *et al*. Surgical management of lung abscess: from open drainage to pulmonary resection. *J Vis Surg* 2018;4:224.
- 5 Yun SS, Cho HS, Heo M, *et al*. Lung abscess by *Actinomyces odontolyticus* and *Parvimonas micra* co-infection presenting as acute respiratory failure: a case report. *Medicine* 2019;98:e16911.