



A rare cause of multiple airways narrowing in a 15-year-old girl

Sergio Ghirardo ,¹ Federica Porcaro ,² Maria Beatrice Chiarini Testa,² Maria Giovanna Paglietti,² Nicola Ullmann ,² May El Hachem ,³ Fabrizio De Benedetti ,⁴ Renato Cutrera ²

¹Medicine, Surgery and Health Sciences, University of Trieste, Trieste, Italy

²Pediatric Pulmonology & Respiratory Intermediate Care Unit, Sleep and Long-Term Ventilation Unit, Department of Pediatrics, Bambino Gesù Pediatric Hospital Department of Paediatrics, Roma, Italy

³Dermatology Unit, Bambino Gesù Pediatric Hospital Department of Paediatrics, Roma, Italy

⁴Division of Rheumatology, Bambino Gesù Pediatric Hospital, Roma, Italy

Correspondence to

Dr Sergio Ghirardo, Medicine, Surgery and Health Sciences, University of Trieste, Trieste 34127, Italy; ghirardo.sergio@gmail.com

This case was scheduled for a presentation at American Thoracic Society conference of Philadelphia 2020 but the conference was cancelled due to Covid-19 pandemic.

Received 1 September 2020
Revised 18 November 2020
Accepted 18 November 2020
Published Online First
3 December 2020

Sergio Ghirardo (SG): a 15-year-old girl was first admitted to our unit, with significant dyspnoea and fatigue at rest. Her clinical history was uneventful until she was 14 years old when she was hospitalised twice for respiratory symptoms, interpreted as post viral wheezing. Treatment with intravenous corticosteroids, salbutamol and azithromycin was of little clinical benefit. In the last 6 months, she complained of progressive exercise-induced dyspnoea, and her lung function showed a moderate-to-severe obstructive pattern (forced expiratory volume in one second, FEV1/forced vital capacity, FVC 56.6%), with no response to salbutamol. Her symptoms did not improve with inhaled corticosteroids, long-acting β_2 agonists and montelukast treatment. Clinically, she reported moderate swelling of the nasal dorsum as a consequence of a blow with a ball received 5 months before admission. She had a bilateral transmissive mild hypoacusis and a significant weight loss of 18 kg in only 8 months.

On initial physical examination she appeared pale and tired with a mild redness of the ear helix sparing the lobe and a mild swelling of the nasal dorsum. She was tachypnoeic (20 breaths/min), with normal levels of oxygen saturation. Mild supraclavicular retractions were present during inspiration. On chest auscultation stridor and mild bilateral wheezing were detected. Heart rate was 109 beats/min. The remaining physical examination was normal.

Renato Cutrera (RC): we have a previously healthy female adolescent with a personal history of only partially remitting obstructive dyspnoea suggesting a chronic respiratory infection (like tuberculosis or pulmonary mycosis). However, the fatigue associated with significant weight loss should raise the suspicion of pulmonary hypertension. I suggest performing routine blood tests, chest X-ray, full blood count and cardiological evaluation. At the same time, I would administer oral corticosteroids and antibiotic coverage.

Federica Porcaro (FP): blood tests showed a mild rise of C reactive protein (CRP) 7.2 mg/L (normal range 0–5 mg/L); whereas full blood count, liver and renal function were normal. Interferon-gamma release assay test was negative as was the intradermal tuberculin test. ECG and cardiac ultrasound were normal, with no signs of pulmonary hypertension. Chest X-ray showed only a tracheal narrowing projecting on C5–C7 (figure 1A). Dyspnoea slightly improved after systemic corticosteroids and broad-spectrum antibiotic treatment.

Nicola Ullmann (NU): there are relatively few causes of progressive tracheal narrowing. Medical history rules out traumatic and iatrogenic causes as well as congenital malformations. Unfortunately, radiological images are not suggestive of a specific condition, therefore I believe that a dynamic chest CT scan with contrast enhancement could be helpful at this stage.

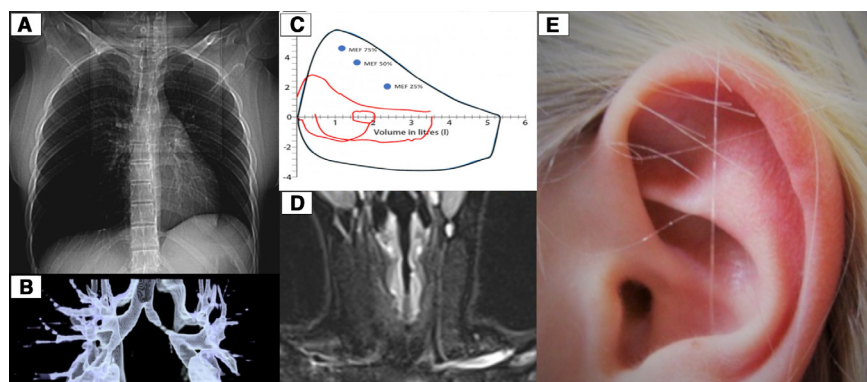
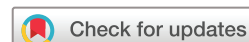

Figure 1 (A) Chest X-ray showing tracheal air column narrowing projecting on C5–C7. (B) CT scan showing narrowing of the tracheal lumen and the nearly complete obstruction of the left main bronchus. (C) Spirometry showing a remarkable involvement of the main airway (red spirometry of the patient and black a normal one for comparison). (D) Magnetic resonance showing hyperintense in T2 paratracheal tissue thickening that progressed to the subglottic area. (E) Redness of the ear helix.



© Author(s) (or their employer(s)) 2021. No commercial re-use. See rights and permissions. Published by BMJ.

To cite: Ghirardo S, Porcaro F, Chiarini Testa MB, et al. *Thorax* 2021;**76**:205–207.

SG: CT showed multiple segmental narrowing of the airways and a tracheal wall thickening was described. Moreover, the left main bronchus collapsed nearly completely in expiration (figure 1B).

Maria Giovanna Paglietti (MGP): multiple airway narrowing can be sustained by several infections such as bronchial anthracosis, rhinoscleroma and fungal tracheobronchitis often due to *Aspergillus fumigatus*. The latter condition typically involves the main airways in a multifocal pattern.¹ Therefore, I recommend performing a bronchoscopy with bronchoalveolar lavage (BAL) and biopsy of the affected tracheal wall.

SG: the bronchoscope did not pass the bronchial stenosis. BAL revealed a mild neutrophilic inflammation (total count of 1.750 cells/mL, neutrophils 70%, macrophages 25%), and *Aspergillus terreus* hyphae were detected. Needle biopsy identified a non-specific lymphocytic infiltrate of the cartilage but were otherwise inconclusive.

MGP: although, in fungal tracheobronchitis, mucosal damage is usually present at bronchoscopy, I consider this diagnosis likely.¹ I suggest starting voriconazole treatment and to ruling out possible congenital or acquired immunodeficiency.

Maria Beatrice Chiarini Testa (MBCT): immune work up showed that she is immunocompetent with normal lymphocyte subset distribution, normal immunoglobulin levels and normal functional antibodies. Functional tests for interleukin-10 (IL-10) and interferon- γ release were normal, as was interferon signature and antineutrophil cytoplasmatic antibodies (ANCA).

SG: unfortunately, her respiratory symptoms did not improve, with worsening of lung volumes (FEV₁/FVC 50%) and a remarkable involvement of the main airways (figure 1C). CRP did not change.

RC: given the clinical worsening despite treatment, I suggest to reconsider neoplastic and rheumatologic causes.

NU: to check airway's evolution and investigate a possible neoplastic disease I would perform a chest magnetic resonance and a positron emission tomography-computed tomography (PET-CT) scan to guide a biopsy where appropriate.

SG: MRI showed a further increase of the paratracheal tissue thickening up to the subglottic area. This area was hyperintense in T2 and FLAIR signals, with DWI restriction (figure 1D). PET-CT scan revealed a hypermetabolic activity of the paratracheal tissue, especially in the subglottic region with no other localisations.

NU: MRI and PET-CT together with the weight loss suggest a primitive or secondary tumour infiltrating the airways' wall, possibly leukaemia or lymphoma. I suggest you perform a biopsy targeting the paratracheal tissue in the subglottic area.

SG: a combined endoscopic and open surgery biopsy confirmed the non-specific lymphocytic infiltrate of the cartilage.

RC: the biopsy results allowed us to rule out an oncological condition and move towards rheumatological diseases.

Fabrizio de Benedetti (FDB): rheumatological causes of bronchial and tracheal thickening are limited to granulomatous diseases, amyloidosis, STING vasculopathy with onset in infancy (SAVI), ANCA vasculitis and relapsing polychondritis (RP). The first two conditions are not likely due to the biopsy appearance and endoscopic findings while the history and the normal interferon signature rule out SAVI. Moreover, ANCA vasculitis are unlikely given negative ANCA blood test and biopsy features. RP is a rare condition with an estimated incidence of less than one case per million adults, slightly higher among Caucasian females.² Children account for <5% of total cases. Young patients more frequently present with airway involvement,³ from 10% at presentation, rising to 50% during

follow-up.⁴ According to clinical presentation and findings, I suggest a dermatological evaluation of ears and nose that may help diagnosis of RP according to the criteria of Michet *et al.*⁵ Moreover, to support the diagnostic hypothesis, I suggest you perform an audiological, rheumatologic and ophthalmologic evaluation.

May El Hachem (MEH): I detected minimal swelling and flattening of the nasal bridge, together with redness of the ear helix sparing the lobe (figure 1E) consistent with a mild chondritis of both sites. The audiological evaluation identified a mild-moderate hearing loss, more severe for high frequencies. Articular and ophthalmologic evaluations were normal.

RC: airway involvement is the leading cause of mortality related to RP in childhood. In all the paediatric cases of RP reported, with isolated airway manifestations, the disease was never correctly diagnosed before the onset of other features, and other cartilage should be evaluated carefully.³ The diagnosis of relapsing polychondritis is based on adult criteria even in the paediatric age group. Depending on the chosen criteria, two or three involved cartilages are required to make a diagnosis of RP in absence of a typical histology.^{2,5} Although the involvement of auricular, nasal and laryngotracheal cartilage is considered pathognomonic, the detection of polyarthritis, ocular inflammation and audio-vestibular damage is often considered as well.²

FDB: relapsing polychondritis is an autoimmune manifestation, mainly directed against collagen II, and matrilin-1 as suggested by animal models. RP is characterised by disease flares causing cartilage damage and disability. Therapeutic approaches vary from non-steroidal anti-inflammatory drugs alone to methyl-prednisone pulses for severe relapses.⁶ Therapeutic regimen outside flares is not standardised, and in most published cases, prednisone is given chronically at the minimum effective dose to pre-empt flares. Several therapeutic approaches use steroid-sparing or steroid-substitutive drugs³ like methotrexate, azathioprine, colchicine, dapsone and ciclosporin, plasmapheresis, autologous stem cells, transplantation and myeloablation.² Treatments with biological drugs like tumour necrosis factor- α blockers (infliximab, etanercept, adalimumab) and IL-1 blockers (anakinra) have been tried, always as a second line therapy.^{2,6} Recently, tocilizumab emerged as the most effective rescue drug in adults; it was also reported in single cases as an effective third-line treatment after infliximab and etanercept failure in paediatric cases.⁶ Nevertheless, the response to tocilizumab or other biological agents seems to be highly unpredictable in RP.

RC: in consideration of onset severity and the need to extinguish cartilage inflammation and possibly reduce the cartilage damage, we administered bolus methylprednisolone (1 g/day for 3 days). Corticosteroid treatment was continued for a week at a dose of 90 mg of prednisone daily (2 mg/kg/day), tapering it down slowly to 0.5 mg/kg/day as maintenance therapy. Just after the steroid boluses, we started oral methotrexate (25 mg weekly) and intravenous tocilizumab (10 mg/kg every 2 weeks).

SG: a moderate improvement of lung function test (FEV₁/FVC 68%) followed the steroid boluses. Since then, the patient has experienced only one episode of dyspnoea, reporting better exercise tolerance in the following 6 months. The Relapsing Polychondritis Damage Index (RPDAI) dropped from 53 to 24 after the eighth infusion of tocilizumab. The effect of steroid boluses may predominate in the short term, and we considered the RPDAI score reduction and the improvement of spirometry to be due to the combination of three drugs. After the eighth dose of tocilizumab, her lung function tests reached stability

and did not improve further. Chest CT at 1-year follow-up did not show any further progression of the disease.

Contributors SG, FP, MGP and MBCT cared the patient. MEH diagnosed the cutaneous aspect of the disease. FDB and RC made the final diagnosis and decided the therapeutic regimen. SG and FP wrote the first draft of the manuscript. MGP and MBCT revised the manuscript. MEH, FDB and RC finally revised and approved the paper.

Funding The authors have not declared a specific grant for this research from any funding agency in the public, commercial or not-for-profit sectors.

Competing interests None declared.

Patient consent for publication Parental/guardian consent obtained.

Provenance and peer review Not commissioned; externally peer reviewed.

ORCID iDs

Sergio Ghirardo <http://orcid.org/0000-0002-6329-4208>

Federica Porcaro <http://orcid.org/0000-0001-7779-728X>

Nicola Ullmann <http://orcid.org/0000-0003-1111-5690>

May El Hachem <http://orcid.org/0000-0002-8145-4797>

Fabrizio De Benedetti <http://orcid.org/0000-0001-8749-8232>

Renato Cutrera <http://orcid.org/0000-0001-7711-5672>

REFERENCES

- 1 Grenier PA, Beigelman-Aubry C, Brillet P-Y. Nonneoplastic tracheal and bronchial stenoses. *Radiol Clin North Am* 2009;47:243–60.
- 2 Kingdon J, Roscamp J, Sangle S, *et al.* Relapsing polychondritis: a clinical review for rheumatologists. *Rheumatology* 2018;57:1525–32.
- 3 Alqanatish JT, Alshanwani JR. Relapsing polychondritis in children: a review. *Mod Rheumatol* 2020;30:788–98.
- 4 de Montmollin N, Dusser D, Lorut C, *et al.* Tracheobronchial involvement of relapsing polychondritis. *Autoimmun Rev* 2019;18:102353.
- 5 Michet CJ, McKenna CH, Luthra HS, *et al.* Relapsing polychondritis. survival and predictive role of early disease manifestations. *Ann Intern Med* 1986;104:74–8.
- 6 Moulis G, Pugnet G, Costedoat-Chalumeau N, *et al.* Efficacy and safety of biologics in relapsing polychondritis: a French national multicentre study. *Ann Rheum Dis* 2018;77:annrheumdis-2017-212705.