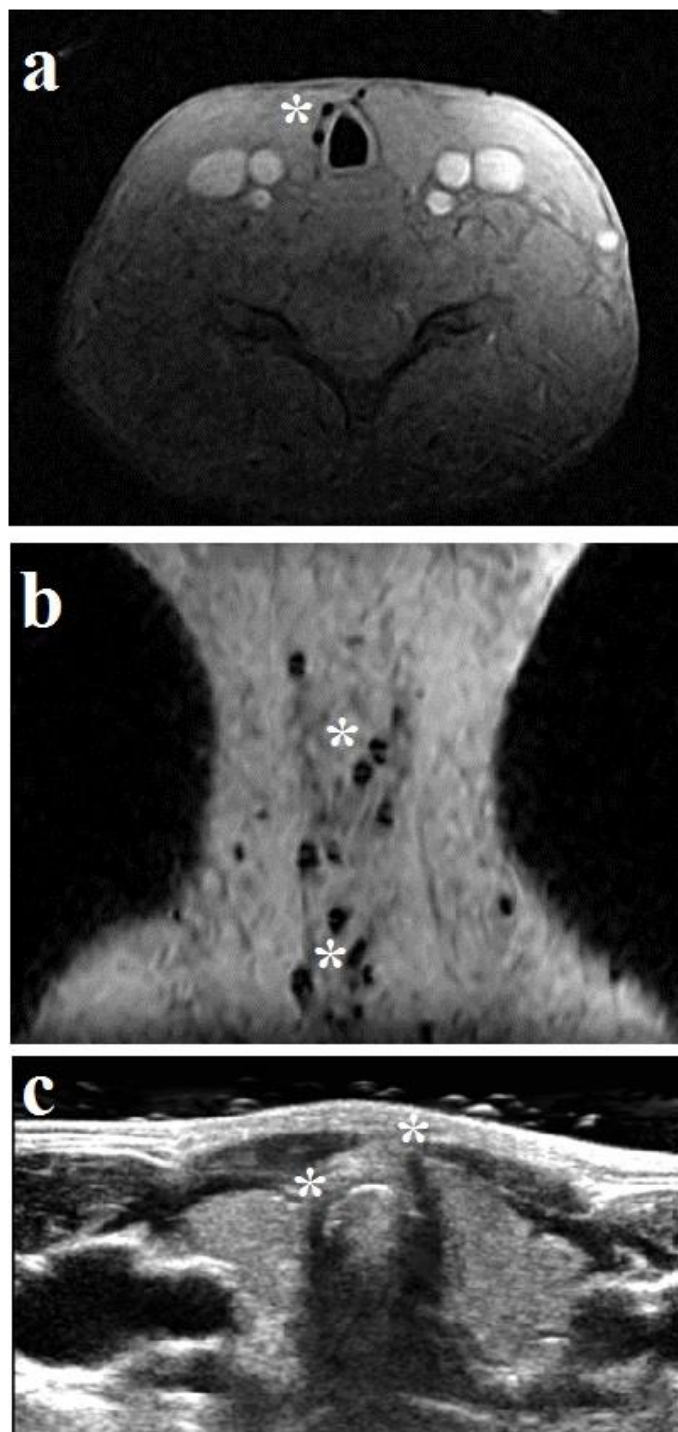


**Online supplement 6:** incidental finding of hypodense regions on proton density imaging

**Online supplement 6:** example of a patient with history of LTS showing an incidental finding of hypodense regions (\*) on axial (A) and sagittal (B) proton density weighted MRI and corresponding ultrasonography (C).