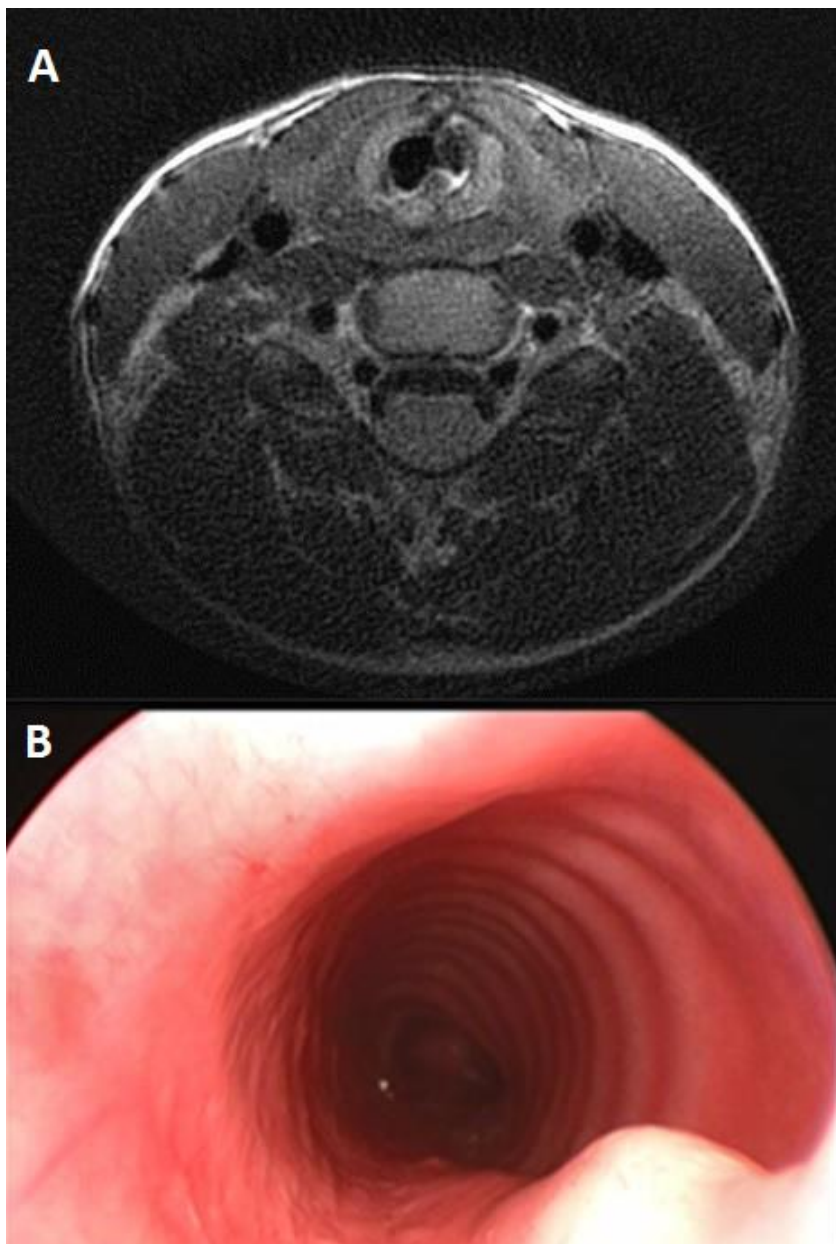


**Online supplement 4:** Example of posterior cartilage graft displacement

**Online supplement 4:** example of a patient with history of LTS showing posterior cartilage graft displacement on an axial T2 weighted MR image (A) and laryngoscopy (B). The MR image is mirrored to correspond to the laryngoscope image.