IMAGES IN THORAX

Higher altitude, bigger bulla

Xian-Ning Wu,[1] Dan Su,[2] Xiao-Feng Zhu,[1] Mei-Qing Xu[1]

[1]Department of Thoracic Surgery, Anhui Provincial Hospital Affiliated to Anhui Medical University, Hefei, China
[2]School of Nursing, Anhui Medical University, Hefei, China

Correspondence to
Dr Xian-Ning Wu, Department of Thoracic Surgery, Anhui Provincial Hospital Affiliated with Anhui Medical University, Hefei 230001, China; 1986wuxianning@163.com

X-NW and DS contributed equally.

Received 9 May 2017
Revised 16 October 2017
Accepted 23 October 2017
Published Online First 16 November 2017

DESCRIPTION

A 28-year-old woman presented to the emergency centre of First People's Hospital of Yunnan Province with a 10-day history of dyspnoea and chest tightness. She had no history of cigarette smoking or drug use and no personal or family history of respiratory diseases. She used to live in Hefei, Anhui Province (with an average altitude of 20 metres). Ten days prior to presentation, she had moved to Kunming, Yunnan Province (a higher altitude area with an average altitude of 1900 metres) to take up a new job. She was in mild distress with an oxygen saturation of 95% while breathing ambient air. The physical examination revealed hyper-resonance and decreased breath sounds in the right hemithorax. The chest X-ray demonstrated a large lucency occupying the entire right hemithorax, with contralateral mediastinal shift (figure 1A). Subsequently, CT of chest revealed no sign of compressed lung tissue on the right (figure 1B). No specific treatment was given. She was urgently transferred to our department (Hefei, Anhui Provincial Hospital) by plane at

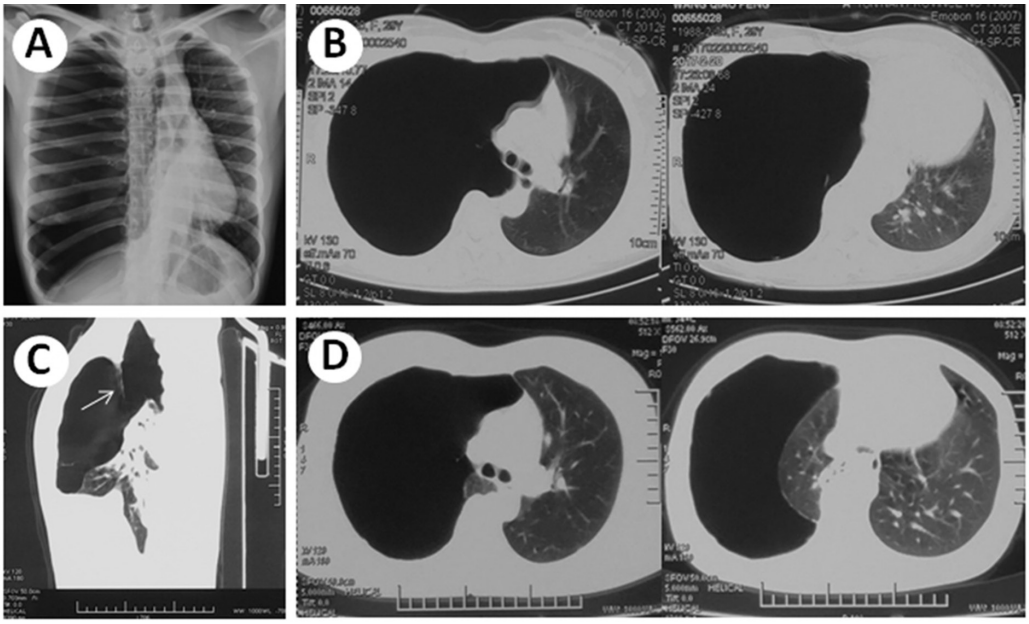

Figure 1 A giant tension bulla with different features seen in the images taken in high-altitude and low-altitude areas. (A) A large lucency occupying the entire right hemithorax, with marked contralateral mediastinal shift, is shown on chest X-ray. No compressed right lung was shown in the CT scan taken in the high altitude area on (B). A repeat CT scan, taken in the low-altitude area, showed a large lucency with a fibrous cord (C). There is also compressive atelectasis with a convex surface affecting the right lung, with improved mediastinal shift and reduced right lung compression compared with figure 1B (D).

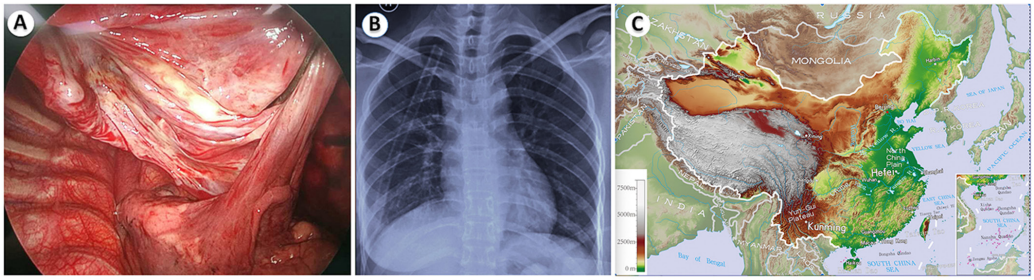

Figure 2 (A) Surgical picture of a giant single tension bulla originated from right upper lobe. (B) Postoperative X-ray showed re-expansion of right lung. (C) Geographical and topographical map illustrates the location and altitude of the patient's different residences.

To cite: Wu X-N, Su D, Zhu X-F, *et al*. *Thorax* 2018;**73**:495–496.

the family's request. The day following the hospital admission, symptoms were improved with an oxygen saturation of 98% while breathing ambient air. Blood tests were unremarkable. Repeat chest CT scan and three-dimensional reconstruction of lung showed a large lucency with a fibrous cord occupying the right hemithorax (figure 1C). There was compressive atelectasis of the right lung, with a convex surface, and improved mediastinal shift compared with the previous CT (figure 1D). The diagnosis of giant tension bulla was considered. We performed video-assisted thoracic surgery through two ports: a utility port for instrumentation and an inferior port for the camera. We found a giant single tension bulla originated from the right upper lobe, 50 cm×37 cm×35 cm in size. The right lung was draped over the bulla toward the ipsilateral hilum (figure 2A). The patient underwent bullectomy with successful re-expansion of the lung (figure 2B). Recovery was uneventful, and the patient was discharged on postoperative day 5.

As altitude increases, barometric pressure and atmospheric PaO_2 of oxygen both decrease. In Kunming (1900 metres above sea level), the actual atmospheric pressure is 598 mm Hg, whereas atmospheric pressure of Hefei (20 metres above sea level) is almost 760 mm Hg (figure 2C). Pressurisation of the cabin on commercial airliners maintains cabin atmospheric pressures around 565 mm Hg. Boyle's law states that the volume of a gas is inversely proportional to the pressure to which it is exposed. The giant tension bulla is closed and does not connect with the air, while the average pressure of lung is almost equal to atmospheric pressure. When the patient travelled from a low-altitude area to a high-altitude area, the pressure difference between tension bulla and normal lung increased dramatically, resulting in expansion of the bulla. This led to further compression of normal lung, mediastinal shift and clinical symptoms. This asymptomatic female with a giant tension bulla felt distress when travelling to a high-altitude area because of increased pressure difference and oxygen reduction. Improved symptoms and imaging findings were observed when she was transferred to a low-altitude area.

Differentiating pneumothorax and a giant bulla can be diagnostically challenging.[1 2]

Generally, lung parenchyma close to the bulla is more likely to show a concave shape on imaging findings; however, in this case, CT scan showed a convex surface. Chest tube insertion is unnecessary and will result in iatrogenic pneumothorax for a patient with a giant bulla.

Contributors All authors cared for the patient. Drafting of the manuscript: X-NW and DS; approval of the final version of the manuscript: X-NW and M-QX.

Competing interests None declared.

Patient consent Obtained.

Ethics approval Research Ethics Committee of Anhui Provincial Hospital.

Provenance and peer review Not commissioned; externally peer reviewed.

REFERENCES

1 Gonzalez M, Krueger T, Ris HB, *et al*. Images in thorax. Tension pneumothorax mimicking giant emphysematous bullae. *Thorax* 2010;65:1028.
2 Vega ME, Civic B. Images in clinical medicine: a tension bulla mimicking tension pneumothorax. *N Engl J Med* 2011;365:1915.