Correlating 3D morphology with molecular pathology: fibrotic remodelling in human lung biopsies

ABSTRACT

Assessing alterations of the parenchymal architecture is essential in understanding fibrosing interstitial lung diseases. Here, we present a novel method to visualise fibrotic remodelling in human lungs and correlate morphological three-dimensional (3D) data with gene and protein expression in the very same sample. The key to our approach is a novel embedding resin that clears samples to full optical transparency and simultaneously allows 3D laser tomography and preparation of sections for histology, immunohistochemistry and RNA isolation. Correlating 3D laser tomography with molecular diagnostic techniques enables new insights into lung diseases. This approach has great potential to become an essential tool in pulmonary research.

"It takes more than cells to make a good lung", as Weibel[1] pointed out. The healthy lung is an efficient organ optimised towards a maximised surface and minimal diffusion barrier for gas exchange. The architecture that facilitates this organisation is based on thin elements of connective tissue providing stability and flexibility. Thus, understanding the three-dimensional (3D) architecture and parenchymal topography is essential to understanding lung function. This is not only true for the healthy lung, but even more so for pulmonary diseases where the 3D architecture is compromised, as, for example, in fibrosing interstitial lung diseases (ILD). Fibrotic changes are generally characterised by a spatially defined gain in tissue thickness due to accumulation of extracellular matrix, produced and modified by aggregates of activated myofibroblasts, as in ILD, for example, idiopathic pulmonary fibrosis or exogenous allergic alveolitis (EAA). Generally, the severity of disease is linked to the histopathological pattern and connectivity of fibrosis, which is responsible for the mechanical impairment of parenchymal dynamics.[2 3] In samples from patients with ILD in areas appearing unaffected in high-resolution CT (HRCT), Coxson and coworkers observed a considerable increase in the thickness of parenchymatous tissue by means of design-based stereology.[4] However, initial changes caused by the disease occur at a cellular level on a scale of microns, which cannot be depicted by HRCT scans and are therefore difficult to study in 3D, particularly in humans. Therefore, the goal of our study was to provide a method to visualise fibrotic remodelling of lung tissue in human lung biopsies and to demonstrate the correlation of morphological 3D data from individual fibrotic areas with gene expression analysis by miRNA or mRNA and immunohistochemistry.

Crucial for the analysis was the development of a novel embedding technique that combines different resins in order to clear the embedded samples to full optical transparency. With this novel technical approach the very same biopsy can be used for 3D tomography using scanning laser optical tomography (SLOT) and preparation of thin sections for histology, immunohistochemistry and RNA isolation after laser-assisted microdissection. Using SLOT the lung architecture can be visualised via endogenous absorption and fluorescence characteristics.[5]

Thereby, 3D imaging at a resolution of 10–12 μm was demonstrated in biopsies of a human lung explant from a patient suffering from end-stage EAA (figure 1). It was possible to identify areas of individual fibrotic remodelling and describe their morphological complexity through intensity, thickness and branching analysis based on absorption data sets. These 3D results of

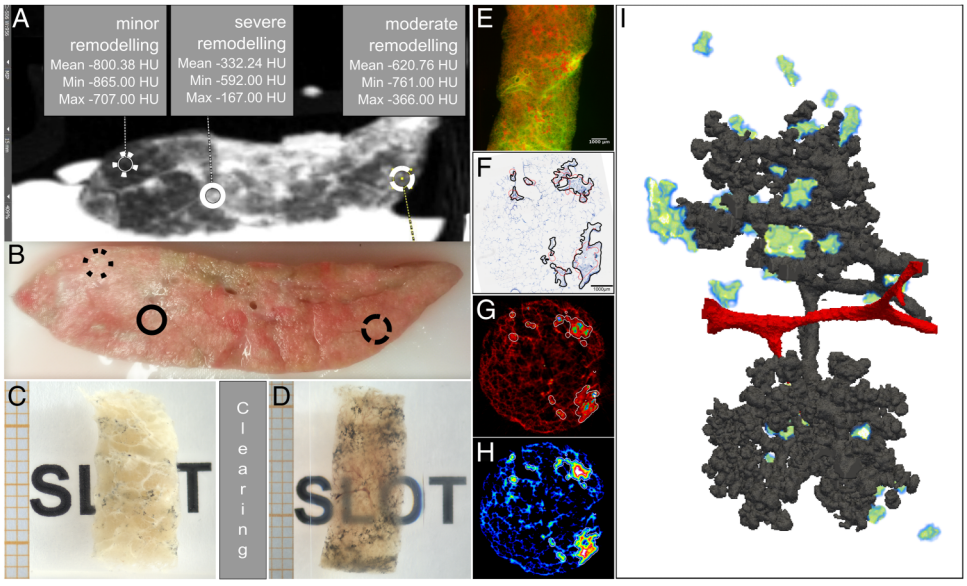

Figure 1 Analysis of the fibrotic architecture in human lungs. Via high-resolution CT scanning of a fresh explanted lung, grading of remodelling intensity was performed (A). Based on this grading, samples were taken at indicated sites and used for solid-block clearing (B). For this, extracted human lung biopsies were fixated (C) and cleared in the resin mixture (D). Scanning laser optical tomography (SLOT) scanning: 800 projection images were taken at a wavelength of 532 nm. (E) shows one of these images combining autofluorescence (green) and absorption (red) signals. Subsequently, histopathological evaluation of the same sample was performed (F) and areas of fibrotic remodelling (black lines) were compared with areas identified as pathological via thickness analysis (red lines represent areas exceeding 300 μm in diameter). The distance cut-off model was based on a thickness analysis of the SLOT data sets (G) and correlated well with an increased absorption of the tissue (H). Segmentation model of airways (grey) and blood vessels (red) in the same sample showing fibrotic areas identified by the distance cut-off model from (F) to (H) in the three-dimensional context (I). For a virtual bronchoscopy through this model, as well as movies of the SLOT projection data sets, distance analysis and the animated segmentation model, see online supplementary movies S1–4.

Thorax: first published as 10.1136/thoraxjnl-2015-207131 on 24 June 2015. Downloaded from http://thorax.bmj.com/ on April 24, 2024 by guest. Protected by copyright.

individual fibrotic areas were then correlated with conventional histopathology and gene expression profiles. Finally, virtual endoscopy based on the absorption data set from small bronchi via terminal bronchioles into the alveoli is feasible. For study details, see online supplementary material.

In summary, optically cleared biopsies from human lung explants can be used to visualise the lung architecture in health and disease. By correlating high-resolution 3D information with histology, immunohistochemistry, mRNA and miRNA expression analysis, new insights into the different stages of (fibrotic) human lung diseases are possible. This diagnostic approach has great potential to become an essential tool in lung research.

Manuela Kellner,[1,2] Judith Wehling,[2,3] Gregor Warnecke,[2,4] Marko Heidrich,[5] Nicole Izykowski,[2,3] Jens Vogel-Claussen,[2,6] Raoul-Amadeus Lorbeer,[5] Georgios Antonopoulos,[5] Sabina Janciauskiene,[2,7,8] Roman Grothausmann,[1,8] Lars Knudsen,[1,2] Tammo Ripken,[5] Heiko Meyer,[4,5] Hans Kreipe,[2,3] Matthias Ochs,[1,2,8] Danny Jonigk,[2,3] Mark Philipp Kühnel[1,2,8]

[1]Institute of Functional and Applied Anatomy, Hannover Medical School, Hannover, Germany
[2]Biomedical Research in Endstage and Obstructive Lung Disease Hannover (BREATH), Member of the German Center for Lung Research (DZL), Hannover, Germany
[3]Institute for Pathology, Hannover Medical School, Hannover, Germany
[4]Department of Cardiothoracic, Transplantation and Vascular Surgery (HTTG), Hannover Medical School, Hannover, Germany
[5]Biomedical Optics Department, Laser Zentrum Hannover e.V., Hannover, Germany
[6]Department of Radiology, Hannover Medical School, Hannover, Germany
[7]Department of Experimental Pneumology, Hannover Medical School, Hannover, Germany
[8]REBIRTH Cluster of Excellence, Hannover Medical School, Hannover, Germany

Correspondence to Dr Mark Philipp Kühnel, Institute of Functional and Applied Anatomy, Hannover Medical School, Carl-Neuberg-Straße 1, Hannover 30625, Germany; kuehnel.mark@mh-hannover.de

Acknowledgements We would like to express our sincere gratitude to Susanne Kuhlmann and Regina Engelhardt for their excellent technical assistance, as well as Gareth Griffiths and Sheila Fryk for revising the text. Additionally, we would like to thank the developers and mailing list members of the open-source programmes Fiji (fiji.sc/Fiji), ITK-SNAP (itksnap.org/pmwiki/pmwiki.php), Paraview (paraview.org), ITK (itk.org), VTK (vtk.org), VMTK (vmtk.org), ImageMagick (imagemagick.org) and mencoder (mplayerhq.hu).

Contributors MK and JW contributed equally to this study and share first authorship. DJ and MPK contributed equally to this study and share senior authorship. MK, JW, DJ and MPK conceived and designed research; MK, JW, GW, MH, NI and MPK performed experiments; MK, JW, JV-C, HM, TR, DJ and MPK analysed data; MK, JW, DJ and MPK interpreted results of experiments; MK, JW, RG and MPK prepared figures; MK and RG prepared movies; MK, JW, DJ and MPK drafted manuscript; MK, JW, GW, MH, NI, JV-C, R-AL, GA, SJ, RG, LK, TR, HM, HK, MO, DJ and MPK edited and revised manuscript; MK, JW, GW, MH, NI, JV-C, R-AL, GA, SJ, RG, LK, TR, HM, HK, MO, DJ and MPK approved final version of manuscript.

Funding The REBIRTH Cluster of Excellence, German Center for Lung Research (DZL) and a habilitation grant from TUI and DFG (grant 30743/1).

Competing interests MH, MK, MPK, R-AL, DJ, NI and HM are involved in a pending patent application for the sample preparation procedure (DE 102014108642.2). Parts of the SLOT imaging technique are patented by the Laser Zentrum Hannover e.V. and are invented by MH, R-AL and HM (among others).

Patient consent Obtained.

Ethics approval Ethikvotum-Nr. 2050-2013 by the ethics committee of the Medical School of Hannover.

Provenance and peer review Not commissioned; externally peer reviewed.

► Additional material is published online only. To view please visit the journal online (http://dx.doi.org/10.1136/thoraxjnl-2015-207131).

To cite Kellner M, Wehling J, Warnecke G, *et al*. *Thorax* 2015;**70**:1197–1198.

Received 31 March 2015
Revised 28 April 2015
Accepted 30 May 2015
Published Online First 24 June 2015

Thorax 2015;**70**:1197–1198.
doi:10.1136/thoraxjnl-2015-207131

REFERENCES

1 Weibel ER. It takes more than cells to make a good lung. *Am J Respir Crit Care Med* 2013;187:342–6.
2 Cool CD, Groshong SD, Rai PR, *et al*. Fibroblast foci are not discrete sites of lung injury or repair: the fibroblast reticulum. *Am J Respir Crit Care Med* 2006;174:654–8.
3 Bates JHT, Davis GS, Majumdar A, *et al*. Linking parenchymal disease progression to changes in lung mechanical function by percolation. *Am J Respir Crit Care Med* 2007;176:617–23.
4 Coxson HO, Hogg JC, Mayo JR, *et al*. Quantification of idiopathic pulmonary fibrosis using computed tomography and histology. *Am J Respir Crit Care Med* 1997;155:1649–56.
5 Kellner M, Heidrich M, Beigel R, *et al*. Imaging of the mouse lung with scanning laser optical tomography (SLOT). *J Appl Physiol* 2012;113:975–83.

Thorax: first published as 10.1136/thoraxjnl-2015-207131 on 24 June 2015. Downloaded from http://thorax.bmj.com/ on April 24, 2024 by guest. Protected by copyright.