

## 'White out': a rare cause



A patient in their mid-40s presented with a history of worsening dyspnoea. The patient had neurofibromatosis type 1 and had previous spinal surgery for kyphoscoliosis.

A chest x-ray showed a right sided 'white out', thought to be a pleural effusion (figure 1A). CT thorax showed a thoracic scoliosis with internal fixation and a large fluid collection within the right hemithorax. A chest drain was scheduled to be inserted.

However, further review of the CT images identified an unusual abnormality within the right hemithorax. Several of the thoracic spinal pedicles were absent and there was communication of fluid from a dilated spinal canal to the large fluid collection within the right hemithorax (figure 1B).

A thoracic MR image confirmed the appearance was due to a large cerebrospinal fluid collection within the right hemithorax, which directly communicated to the right side of the spinal canal (figure 1C). The appearances were due to a huge intrathoracic meningocele rather than a pleural effusion.

An intrathoracic meningocele is a rare abnormality due to herniation of spinal meninges through an intervertebral foramen or bony deformity, producing a cerebrospinal fluid filled sac.<sup>1</sup> Despite being rare, it is often associated with neurofibromatosis type 1.<sup>2</sup>

Failure to recognise this rare presentation may have resulted in inappropriate chest drain insertion with potentially disastrous consequences.

## Learning points

- ▶ This case illustrates a rare cause of 'white out' of the lung and highlights the importance of recognising an intrathoracic meningocele in the context of neurofibromatosis type 1.
- ▶ This extremely rare abnormality could easily have been misinterpreted as a large pleural effusion which if drained may have led to potentially fatal consequences.

**Gurinder Tack,<sup>1</sup> Dhakshinamoorthy Ganeshan,<sup>2</sup> Jonathan Wide,<sup>2</sup> Paul Stockton<sup>1</sup>**

<sup>1</sup>Respiratory Medicine, St Helens and Knowsley Teaching Hospitals NHS Trust, Prescot, UK; <sup>2</sup>Radiology Department, St Helens and Knowsley Teaching Hospitals NHS Trust, Prescot, UK

**Correspondence to** Dr Gurinder Tack, Respiratory Medicine, St Helens and Knowsley Teaching Hospitals NHS Trust, Prescot, UK; g.tack@nhs.net

**Competing interests** None.

**Patient consent** Detail has been removed from this case description. The editors and reviewers have seen the detailed information available and are satisfied that the information backs up the case the authors are making.

**Provenance and peer review** Not commissioned; internally peer reviewed.

Received 23 November 2011

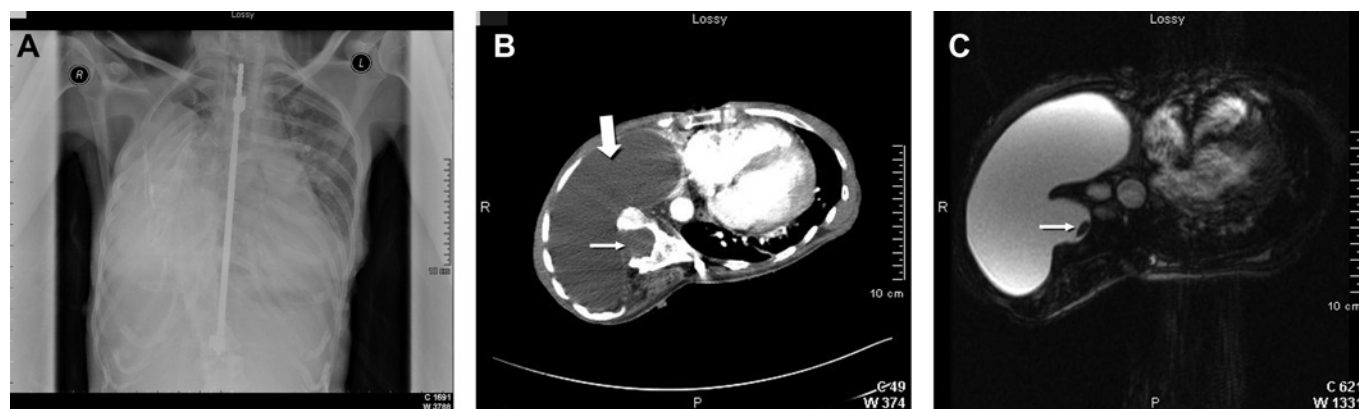
Accepted 19 January 2012

Published Online First 14 February 2012

*Thorax* 2012;**67**:757. doi:10.1136/thoraxjnl-2011-201409

## REFERENCES

1. **Gutierrez FR**, Woodard PK, Fleishman MJ, *et al*. Normal anatomy and congenital anomalies of the spine and spinal cord. In: Osborn AG, Maack H, eds. *Diagnostic Neuroradiology*. 1st edn. St. Louis: Mosby, 1994:785–819.
2. **Andrade GC**, Braga OP, Hisatogo MK, *et al*. Giant intrathoracic meningoceles associated with cutaneous neurofibromatosis type 1. *Ar Neuropsiquiatr* 2003;**61**:677–81.



**Figure 1** (A) Chest x-ray showing marked scoliosis with internal fixation and a 'white out' of the right hemithorax. (B) Axial CT image demonstrating a grossly widened right thoracic intervertebral foramina (thin arrow) with a large meningocele (thick arrow). (C) Axial T2 weighted MR image demonstrating the large meningocele in the right chest and also showing the cord within the spinal canal (arrow).