

Broncholithiasis mimicking a bronchial carcinoid tumour

A 29-year-old woman was transferred to our unit with a diagnosis of bronchial carcinoid tumour. She complained of chest pain, dyspnoea, cough and haemoptysis. She smoked 20 cigarettes per day and denied any history of tuberculosis, histoplasmosis or occupational exposure and her family history was strongly positive for cancer. She had undergone a contrast-enhanced CT scan of the chest in the endocrinology unit which showed a partially calcified mass in the left hilum (fig 1A, arrow). Further pulmonary scintigraphy with ¹¹¹In-octreotide showed a concentration of the isotope in the left hilar region (fig 1B, arrow) and a positron emission tomographic scan with ¹⁸F-FDG (FDG-PET) showed that the mass had an uptake suggestive of bronchial carcinoid tumour (fig 1C, arrow). Carcinoembryonal antigen (CEA) and tissue-specific polypeptide (TSP) levels were 7.9 ng/ml (normal 0–4) and 122.0 U/l (normal 0–80), respectively. Fiberoptic bronchoscopy revealed a pedunculated mass which bled easily occluding the left upper bronchus (fig 1D), and a CT-guided fine needle aspiration of the mass yielded inconclusive results. The patient underwent a left superior lobectomy with mediastinal lymphadenectomy. At gross examination, the mass measured 2.5 cm and appeared solid and pale. The histological diagnosis was broncholithiasis of the left upper bronchus (fig 2). One year later the patient is in good health with no sign of recurrence.

It is noteworthy that the mass showed significant FDG activity on the PET scan¹ and concentration of ¹¹¹In-octreotide on scintigraphy. Furthermore, the values of CEA and TSP were

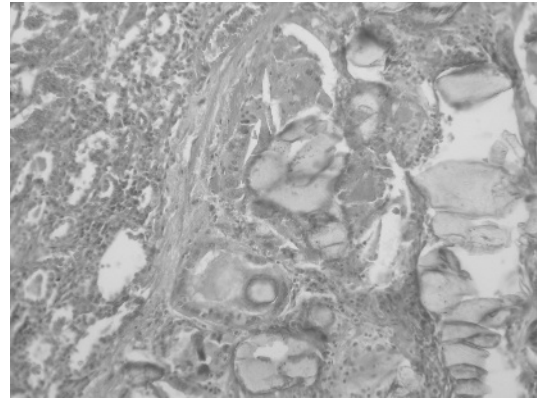


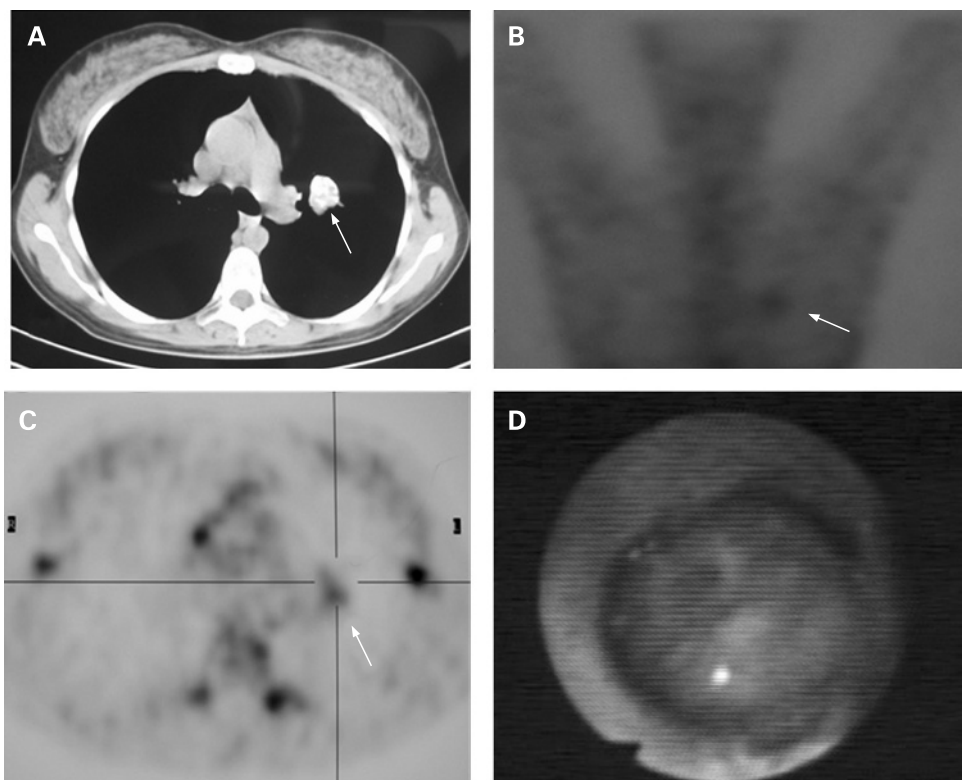
Figure 2 Histiocytes with foreign body reaction, rare giant cells and calcific lesions. Lymphocytes with reactive fibrous tissue can be seen at the periphery of the lesion.

abnormally high, and bronchoscopy revealed an easily bleeding mass suggestive of bronchial carcinoid tumour.

Learning points

- ▶ Broncholithiasis as a diagnostic possibility is rarely considered in patients with calcified granulomas on chest radiographs or chronic cough.
- ▶ To prevent serious complications such as massive haemoptysis and fistula with the oesophagus or mediastinum, immediate treatment is essential.

Figure 1 (A) CT scan showing the mass in the left hilar region (arrow). (B) Concentration of ¹¹¹In-octreotide in the same region (arrow). (C) FDG-PET scan showing lesion in the left hilar region (arrow). (D) The bleeding mass at bronchoscopy.



Broncholithiasis is a rare disease with varying clinical presentations.² Despite its rarity, it should also form part of the differential diagnosis of pulmonary opacities with high FDG uptake on PET and concentration of In-octreotide on pulmonary scintigraphy.

P Stassano,¹ S Griffo,² L Di Tommaso,¹ A Luciano²

¹ University Federico II, School of Medicine, Naples, Italy; ² Istituto Clinico Pineta Grande, Castelvoturno (CE), Italy

Correspondence to: Dr P Stassano, University Federico II, School of Medicine, Naples, Italy; pstassano@libero.it

Patient consent: Obtained.

Thorax 2009;**64**:551–552. doi:10.1136/thx.2008.104208

REFERENCES

1. **Chang ET**, Wang AH, Lin CB, *et al*. Pulmonary cryptococcosis mimicking solitary lung cancer in an immunocompetent patient. *Thorax* 2008;**63**:478.
2. **Olson EJ**, Utz JP, Prakash UBS. Therapeutic bronchoscopy in broncholithiasis. *Am J Respir Crit Care Med* 1999;**160**:766–70.

Lung alert

Mepolizumab in corticosteroid-resistant eosinophilic asthma

Eosinophils have long been regarded as a key inflammatory cell mediator in the pathogenesis of asthma, although their exact role is unclear. Downregulation of eosinophil activity via targeted interleukin 5 (IL5) inhibition (a pro-eosinophilic cytokine) in the study of heterogeneous populations of subjects with asthma has yielded disappointing results.

Two recent well-designed randomised controlled trials have investigated the safety and efficacy of selected IL5 inhibition with mepolizumab (monoclonal antibody against IL5) in a subset of patients with corticosteroid-resistant eosinophilic asthma. These patients represent a minority of patients with asthma.

In the first study, patients were stratified into two groups according to their daily dose of prednisolone (<10 mg or >10 mg), then randomised to receive either mepolizumab (750 mg intravenously, n = 9) or placebo (150 ml 0.9% saline, n = 11) as five monthly infusions. After a 6-week run-in period, prednisolone dose reduction was attempted according to a predefined protocol.

The second study had a run-in period of 2 weeks prednisolone (1 mg/kg to a maximum of 40 mg), following which 61 patients were randomised to receive 12 infusions of either mepolizumab (750 mg intravenously, n = 29) or placebo (150 ml 0.9% saline, n = 32) at monthly intervals.

Both studies demonstrated a statistically significant reduction in asthma exacerbation frequency accompanied by a significant reduction in blood and sputum eosinophils. Despite this, neither study identified any clinically meaningful improvement in symptoms, forced expiratory volume in 1 s or asthma control. No serious adverse events were recorded in either study population.

Improvement in asthma lung function and symptoms was demonstrated with corticosteroid therapy alone, reflecting the heterogeneity of this disease and implying a complex interaction of a host of inflammatory cell types, of which eosinophils play just one part. In summary, these studies do suggest that, in a subgroup of patients, eosinophils are an important contributor to the pathophysiology of asthmatic exacerbations. These patients may benefit from targeted IL5 therapy with mepolizumab.

- ▶ Nair P, Pizzichini MMM, Kjargaard M, *et al*. Mepolizumab for prednisolone-dependent asthma with sputum eosinophilia. *N Engl J Med* 2009;**360**:985–93.
- ▶ Haldar P, Brightling CE, Hargadon B, *et al*. Mepolizumab and exacerbations of refractory eosinophilic asthma. *N Engl J Med* 2009;**360**:973–84.

S Barratt

Correspondence to: Dr S Barratt, Specialist Registrar, Musgrove Park Hospital, Taunton and Somerset NHS Trust, Taunton, UK; shaneybarratt@hotmail.com