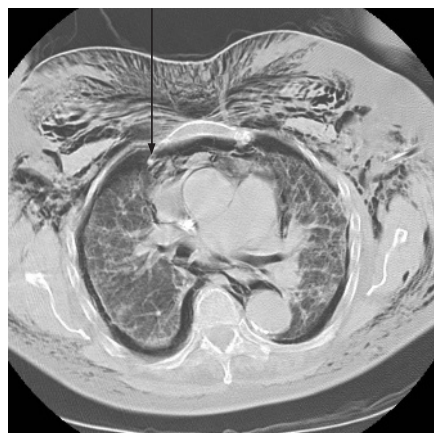

Recurrence after resection of NSCLC

Surgical resection is the treatment of choice for early non-small cell lung cancer (NSCLC) and these patients have the best prognosis. However, local recurrence is a common cause of death in this group and the course and predictors of post-recurrence survival in resected stage I NSCLC have not been studied. In this month's *Thorax*, Hung and colleagues studied local recurrence and its outlook in stage I NSCLC. The hazard of death was greater with large tumour size. Patients who were operated on again had the best outcome. These results are discussed in an accompanying editorial by Pham and Harpole, who remind us that our success rate with the management of stage I NSCLC can be improved. *See pages 185 and 192*



CT chest performed 2 days post bronchoscopy shows bilateral extrapleural air collection with right internal mammary artery traversing the collection (arrow), multiple fibrous septae within the collection and extensive surgical emphysema. *See Image page 276.*

Bronchiectasis in children

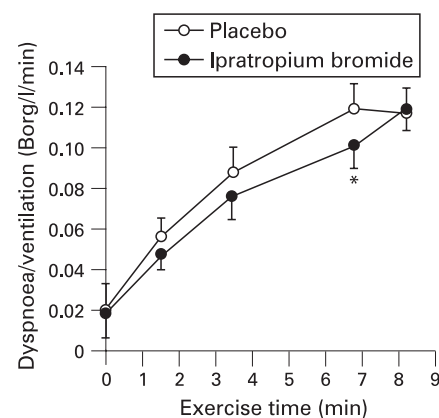
Although the incidence of non-cystic fibrosis (CF) bronchiectasis has largely fallen over the past 100 years, the widespread use of high resolution CT scanning has led to easier and more accurate diagnosis of this condition. In this month's *Thorax*, Bastardo and colleagues describe the natural history of childhood bronchiectasis and show that lung function stabilises but does not normalise with treatment. Children with non-CF bronchiectasis show adequate growth over time and this study emphasises the need for early detection of the condition with appropriate treatment and careful follow up. *See page 246*

Childhood OSA and cardiac function

Another childhood condition that is being increasingly recognised is obstructive sleep apnoea (OSA) and estimates are that its prevalence is between 2–4% in the paediatric population. Earlier studies have suggested that severe childhood OSA could lead to heart failure. In this issue, Chan and colleagues report a study of cardiac structure and function in a childhood OSA cohort in the community and assess the affect of intervention. Left and right ventricular dysfunction were documented with remodelling in children with moderate to severe OSA. The apnoea-hypopnea index was associated with cardiac dysfunction and, following effective treatment, the abnormalities described improved. This study shows the importance of awareness of OSA in children and further studies are required to ascertain how these cardiac abnormalities influence cardiovascular risk in adult life. *See page 233*

Bronchodilator reversibility in GOLD stage I COPD

Patients with GOLD stage I chronic obstructive pulmonary disease (COPD) have relatively preserved spirometric results but may already have significant small airway dysfunction and this can lead to dyspnoea. Although smoking cessation is the only known intervention to improve patients with mild COPD, bronchodilators may be beneficial but need more complex evaluation of lung function. In this month's *Thorax*, O'Donnell and colleagues present an elegant study showing that the inhaled anticholinergic bronchodilator ipratropium is associated with improvements in airway function, operating lung volumes and dyspnoea during exercise. These results suggest that a trial of bronchodilator treatment should now be considered in patients with mild COPD who have developed symptomatic exercise-related dyspnoea. *See page 216*



Ratings of dyspnoea intensity expressed relative to ventilation against exercise time during constant load cycle testing. Ipratropium bromide vs placebo $p < 0.05$.