

- 16 **Freeman D**, Norrie J, Caslake M, *et al*. C-reactive protein is an independent predictor of risk for the development of diabetes in the West of Scotland Coronary Prevention Study. *Diabetes* 2002;**51**:1596–600.
- 17 **Donaldson G**, Seemungal T, Patel I, *et al*. Airway and systemic inflammation and decline in lung function in patients with COPD. *Thorax* 2005;**128**:1995–2004.
- 18 **Thyagarajan B**, Jacobs D, Apostol G, *et al*. Plasma fibrinogen and lung function: the CARDIA study. *Int J Epidemiol* 2006;**35**:1001–8.
- 19 **Coxson H**, Chan I, Mayo J, *et al*. Early emphysema in patients with anorexia nervosa. *Am J Respir Crit Care Med* 2004;**170**:748–52.
- 20 **Burge P**, Calverley P, Jones P, *et al*. Randomised, double-blind, placebo controlled study of fluticasone propionate in patients with moderate to severe chronic obstructive pulmonary disease. *BMJ* 2000;**320**:1297–303.
- 21 **Pauwels R**, Lofdahl C-G, Laitinen L, *et al*. Long-term treatment with inhaled budesonide in persons with mild chronic obstructive pulmonary disease who continue smoking. *N Engl J Med* 1999;**340**:1948–53.
- 22 **The Lung Health Study Research Group**. Effect of inhaled triamcinolone on the decline in pulmonary function in chronic obstructive pulmonary disease. *N Engl J Med* 2000;**343**:1902–9.
- 23 **Vestbo J**, Sorensen T, Lange P, *et al*. Long term effect of inhaled budesonide in mild and moderate chronic obstructive pulmonary disease: a randomised controlled trial. *Lancet* 1999;**353**:1819–23.
- 24 **Highland K**, Strange C, Heffner J. Long-term effects of inhaled corticosteroids on FEV₁ in patients with chronic obstructive pulmonary disease. *Ann Intern Med* 2003;**138**:969–73.
- 25 **Clark D**, Lipworth B. Adrenal suppression with chronic dosing of fluticasone propionate compared with budesonide in adult asthmatic patients. *Thorax* 1997;**52**:55–8.
- 26 **Lapperre T**, Snoeck-Stroband J, Gosman M, and GLUCOLD Study Group, *et al*. Dissociation of lung function and airway inflammation in chronic obstructive pulmonary disease. *Am J Respir Crit Care Med* 2004;**170**:499–504.
- 27 **Fletcher C**, Peto R, Tinker C, *et al*. Factors related to the development of airflow obstruction. In: *The natural history of chronic bronchitis and emphysema*. 1st ed. Oxford: Oxford University Press, 1976:70–102.
- 28 **Sattar N**, McConnachie A, O'Reilly D, *et al*. Inverse association between birth weight and C-reactive protein concentrations in the MIDSPAN family study. *Arterioscler Thromb Vasc Biol* 2004;**24**:583–7.
- 29 **Barker D**, Godfrey K, Fall C, *et al*. Relation of birth weight and childhood respiratory disease to adult lung function and death from chronic obstructive airways disease. *BMJ* 1991;**303**:671–5.

PULMONARY PUZZLE

Respiratory disease in the ophthalmology department

Clinical presentation

A 24-year-old Indian doctor presented to the ophthalmology department complaining of bright lights in his field of vision during the preceding 6 months. He had previously been diagnosed with inferior branch retinal vein occlusion in his right eye and undergone laser treatment. On examination his visual acuities were 6/4 in the right and 6/5+ in the left eye. On fundoscopy there were multiple areas of sheathing of the retinal veins in both eyes, with small branch retinal vein occlusion in the right eye (fig 1).

Question

What is your differential diagnosis?

See page 526

This case was submitted by:

J K Quint

Department of Academic Respiratory Medicine, Royal Free and University College Medical School, London, UK

A Elsheikh, B Yung, J Samuel, D K Mukherjee

Department of Respiratory Medicine, Basildon and Thurrock University Hospital, Essex, UK

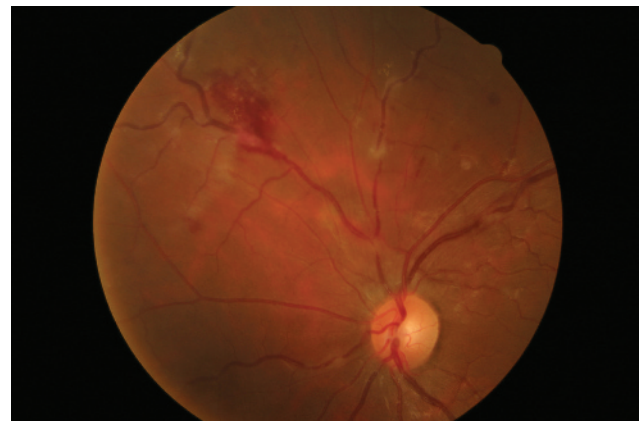


Figure 1 On fundoscopy; multiple areas of sheathing of the retinal veins, with small branch retinal vein occlusion.

Correspondence to: Dr Jennifer Quint, Department of Academic Respiratory Medicine, Royal Free and University College Medical School, Rowland Hill St, Hampstead, London NW3 2PF, UK; j.quint@medsch.ucl.ac.uk

doi: 10.1136/thx.2007.082578