

Images in *Thorax*

Tuberculous pulmonary pneumatocele communicating extrathoracically

A 40 year old man presented with swelling over his right upper chest for the previous 8 months. He had also had low grade fever, cough with mucoid expectoration, weight loss, and breathlessness on exertion for 2 months. The swelling initially appeared in the right infraclavicular region and gradually increased in size. The swelling could be decreased in size on application of local pressure, but it regained its original size when the pressure was released. He had been treated elsewhere for pulmonary tuberculosis (TB) 3 years previously and had had an abscess below the right clavicle drained 1 year earlier.

Examination revealed a 20 × 18 cm smooth swelling in the right pectoral region (fig 1) with a ragged scar just below the right sternoclavicular joint. The swelling was soft, compressible, transilluminant, and became tense on coughing and deep inspiration. A chest radiograph (fig 2) revealed a large multiloculated radiolucent area in the right lung field extending out of the chest wall with crowding of the right upper ribs, airspace consolidation involving the right lung and left upper lobe, and an air fluid level in the lower compartment of the extrathoracic pneumatocele suggestive of pulmonary TB with infected extrathoracic pneumatocele. A CT scan (fig 3) suggested an extrathoracic air filled compartment in communication with the right lung, without evidence of pneumothorax. The sputum was positive for *Mycobacterium tuberculosis*. After 8 weeks of antituberculous treatment the patient showed a remarkable clinical and radiological improvement. The swelling reduced to one third of the original size with partial resolution of the consolidation and pneumatocele together with absence of air fluid level.

Although *Mycobacterium tuberculosis* has been implicated as one of the many causative agents responsible for pulmonary

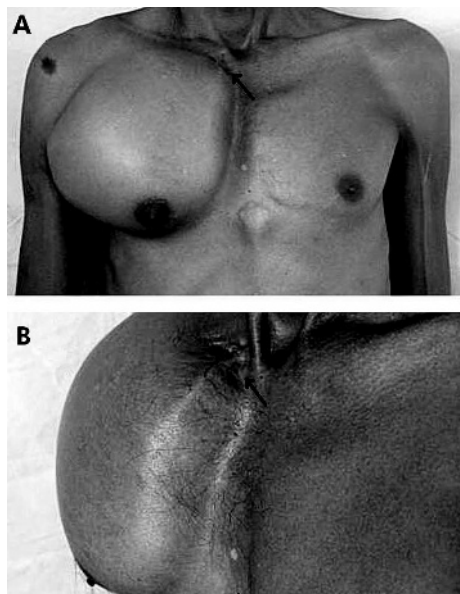


Figure 1 (A) Anterior and (B) tangential view of the chest showing the swelling over the right pectoral region and a ragged scar (arrow) below the right sternoclavicular joint.

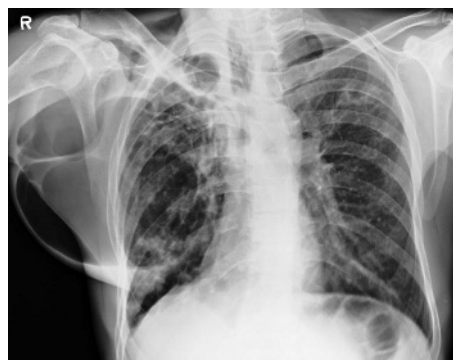

Figure 2 Chest radiograph showing bilateral airspace consolidation with multiloculated radiolucent area in the right lung field and an extrathoracic extension containing a fluid level.

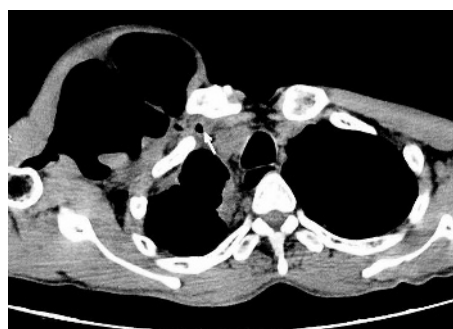

Figure 3 CT scan of chest showing extrathoracic air filled compartment in communication with the right lung (arrow) at the level of the body of the T4 vertebra.

Learning points

- Tuberculous pulmonary pneumatocele may have an extrathoracic extension through a parietal weakness.
- Antituberculous drug therapy is curative.

pneumatocele, its extrathoracic extension has not been previously reported in the literature. Drainage of a probable cold abscess, as indicated by the scar, may have been responsible for a potential weakness in the chest wall musculature leading to the development of extrathoracic pneumatocele.

D D Duttaroy, J Jagtap, U Bansal

Department of Surgery, Government Medical College and Sir Sayajirao General Hospital, Baroda, Gujarat, India

B Duttaroy

Department of Microbiology, Government Medical College and Sir Sayajirao General Hospital, Baroda, Gujarat, India

Correspondence to: Dr D D Duttaroy, Department of Surgery, Government Medical College and Sir Sayajirao General Hospital, Baroda, Gujarat, India 390001; drduttaroy@gmail.com