

## SARCOIDOSIS

# Pulmonary hypertension associated with sarcoidosis: mechanisms, haemodynamics and prognosis

H Nunes, M Humbert, F Capron, M Brauner, O Sitbon, J-P Battesti, G Simonneau, D Valeyre



Thorax 2006;61:68–74. doi: 10.1136/thx.2005.042838

See end of article for authors' affiliations

Correspondence to:  
Dr H Nunes, Service de  
Pneumologie, Hôpital  
Avicenne, 125 rue de  
Stalingrad, 93009  
Bobigny, France; hilario.  
nunes@avc.ap-hop-paris.  
fr

Received 23 February 2005  
Accepted  
28 September 2005  
Published Online First  
14 October 2005

**Background:** Pulmonary hypertension (PH) is a rare complication of sarcoidosis, although it is not uncommon in advanced disease.

**Methods:** A retrospective series of 22 sarcoidosis patients (16 men) of mean (SD) age 46 (13) years with PH was divided into two groups depending on the absence (stage 0: n = 2, stage II: n = 4, stage III: n = 1) or presence (n = 15) of radiographic pulmonary fibrosis at the time of PH diagnosis.

**Results:** In both groups PH was moderate to severe and there was no response to acute vasodilator challenge. In non-fibrotic cases no other cause of PH was found, suggesting a specific sarcoidosis vasculopathy, although no histological specimens were available. In cases with fibrosis there was no correlation between haemodynamics and lung volumes or arterial oxygen tensions, suggesting other mechanisms for PH in addition to pulmonary destruction and hypoxaemia. These included extrinsic arterial compression by lymphadenopathies in three cases and histologically proven pulmonary veno-occlusive disease in the five patients who underwent lung transplantation. Ten patients received high doses of oral prednisone for PH (stage 0: n = 1, stage II: n = 4 and stage IV: n = 5); three patients without pulmonary fibrosis experienced a sustained haemodynamic response. Survival of the overall population was poor (59% at 5 years). Mortality was associated with NYHA functional class IV but not with haemodynamic parameters or with lung function.

**Conclusion:** Two very different phenotypes of sarcoidosis combined with PH are observed depending on the presence or absence of pulmonary fibrosis. PH is a severe complication of sarcoidosis.

Pulmonary hypertension (PH) is a well recognised complication of sarcoidosis with a prevalence not exceeding 5% of all sarcoidosis patients,<sup>1–4</sup> although in advanced disease it is not uncommon.<sup>5</sup> PH is usually attributed to the destruction of the distal capillary bed by fibrotic processes and/or to the resultant chronic hypoxaemia.<sup>1–4</sup> However, the severity of PH does not correlate well with the degree of pulmonary fibrosis and blood gas tensions,<sup>6</sup> and PH has also been reported as an early primary manifestation of sarcoidosis, suggesting that other mechanisms may contribute to the development of PH in patients with sarcoidosis. Such mechanisms include extrinsic compression of large pulmonary arteries by mediastinal or hilar adenopathies or fibrosis,<sup>2–7</sup> specific granulomatous vascular involvement<sup>2–8–12</sup> which sometimes simulates secondary pulmonary veno-occlusive disease (PVOD),<sup>11–12</sup> and pulmonary vasoconstriction by vasoactive factors.<sup>13–14</sup> Uncommonly, portal hypertension secondary to liver sarcoidosis can also provoke PH.<sup>15</sup>

PH is known to have an extremely poor prognosis in patients with sarcoidosis,<sup>16–17</sup> but the response of patients with sarcoidosis and PH to corticosteroids is unclear. We report a large retrospective series of 22 consecutive patients with sarcoidosis and PH. The objectives of the study were (1) to evaluate baseline pulmonary haemodynamics in these patients, (2) to discuss the underlying mechanisms of PH, and (3) to assess the efficacy of corticosteroids and the prognosis of affected patients.

## METHODS

### Patients

This retrospective study was conducted in two centres, Avicenne and Antoine Béclère hospitals. Patients with a

history of sarcoidosis and PH observed between January 1988 and December 2002 were evaluated. Complete information was obtained from hospital and referring physician medical records and reviewed by two of the authors (HN and DV). The diagnosis of sarcoidosis was established by pathological examination and compatible clinical and radiographic features. PH was defined as a mean resting pulmonary artery pressure (mPAP) of  $\geq 25$  mm Hg and normal pulmonary wedge pressure (PWP  $\leq 12$  mm Hg) during right heart catheterisation. The haemodynamic study was performed at the Antoine Béclère Hospital (MH, OS, GS) as described elsewhere.<sup>18</sup> Other causes of precapillary PH including thromboembolic disease, appetite suppressant ingestion, portal hypertension, connective tissue disease, HIV infection, sickle cell disease, and congenital heart disease were excluded on the results of history, physical examination, ventilation-perfusion lung scan and/or pulmonary angiography, Doppler echocardiography, abdominal Doppler echography, HIV serology, and antinuclear antibody.

Twenty five consecutive patients with sarcoidosis and PH were reviewed. Three were excluded from the study: one patient with splenectomy had chronic thromboembolic disease, one had evidence of mixed connective tissue disease and had also taken fenfluramine, and one had portal

**Abbreviations:** CI, cardiac index; FEV<sub>1</sub>, forced expiratory volume in 1 second; FVC, forced vital capacity; mRAP, mean right atrial pressure; KCO, carbon monoxide transfer coefficient; mPAP, mean pulmonary artery pressure; PaO<sub>2</sub>, arterial oxygen tension at room air; PH, pulmonary hypertension; PVOD, pulmonary veno-occlusive disease; PVRI, pulmonary vascular resistance index; PWP, pulmonary wedge pressure; SACE, serum angiotensin converting enzyme; SvO<sub>2</sub>, mixed venous oxygen saturation. TLC, total lung capacity; TLCO, carbon monoxide transfer factor

hypertension. The 22 studied patients underwent a standard evaluation during first right heart catheterisation including chest radiography, pulmonary function tests as recommended,<sup>19</sup> contrast enhanced high resolution computed tomographic (HRCT) scanning, and measurement of serum angiotensin converting enzyme (SACE).

### Controls

Patients with sarcoidosis and PH were compared with control patients with sarcoidosis without PH on Doppler echocardiography. Each patient was matched with two controls for sex, age, and radiographic stage. The pneumology department of Avicenne Hospital is highly specialised in sarcoidosis and has a unique and large cohort of patients with the condition. Each patient with sarcoidosis referred to the department is registered according to the date of admission, age, sex, and radiographic stage and is assigned a recruitment number according to the date of admission. Controls were selected by two steps: (1) for each patient with sarcoidosis and PH the two sarcoidosis patients whose number was immediately before and after and who had the same sex, age ( $\pm 5$  years), and radiographic stage were reviewed; (2) the sarcoidosis patient was selected as a control if a Doppler echocardiograph was available in his chart and had no evidence of PH. If not, the following sarcoidosis patient according to his recruitment number was reviewed, and so forth.

### Analysis of HRCT scans

The scans of the patients and controls were randomly reviewed by one chest radiologist who was blind to the diagnoses (MB). They were analysed for the presence or absence of pulmonary elementary lesions as previously described.<sup>20, 21</sup>

### Statistical analysis

Analysis was performed using the Statview version 5.0 statistical package (SAS Institute, Cary, NC, USA). Results are expressed as mean (SD). Groups were compared by unpaired Student's *t* test and  $\chi^2$  test as appropriate. Simple regression analysis was used for correlations. The probability of survival of patients and controls was estimated by the Kaplan-Meier method and compared using the log rank test. Survival was calculated from PH diagnosis for patients and from normal Doppler echocardiography for controls until the end of the follow up period. Transplanted patients were considered as censored at the date of transplantation. Univariate analysis was based on the proportional hazards model. The results are expressed as hazard ratios with 95% confidence intervals.

## RESULTS

### Clinical findings

The study population included 22 patients (16 men and 6 women) of mean (SD) age 46 (13) years. Seventeen patients were referred because of detection of PH by Doppler echocardiography while they had increased dyspnoea; five were referred for lung transplantation and systematic right heart catheterisation evidence of PH. The patients were divided into two groups according to the absence (group A) or presence (group B) of pulmonary fibrosis on the chest radiograph. Group A consisted of seven patients (two with stage 0 disease, four with stage II, and one with stage III). Group B comprised 15 patients (all with stage IV disease).

The demographic and clinical characteristics of the patients are shown in table 1. Sarcoidosis involved at least one extrapulmonary organ in 11 of the 22 patients (skin (n = 6), liver (n = 4), peripheral adenopathy (n = 3), spleen (n = 1), articular (n = 1), eye (n = 1), and stomach (n = 1)) and one patient had hypercalcaemia. Sarcoidosis and PH were

**Table 1** Demographic, clinical, and haemodynamic characteristics of patients at the time of PH diagnosis

	Group A (n = 7)	Group B (n = 15)
Age (years)	48 (13)	45 (13)
M/F	3/4	13/2
White/black	4/3	13/2
Non/ex/current smokers	4/3/0	6/7/2
Mean (SD) time interval between sarcoidosis and PH (years)*	3.7 (3.1)	12.5 (6.2)
NYHA functional class, n (%)		
I	1 (14.3)	
II	4 (57.1)	2 (13.3)
III	2 (28.6)	8 (53.3)
IV		5 (33.3)
Right heart failure, n (%)	1 (14.3)	4 (26.7)
Near syncope, n (%)	0	3 (20)
Mean (SD) baseline haemodynamics		
mRAP (mm Hg)	7.3 (4.2)	6.4 (6.7)
mPAP (mm Hg)	51.7 (16.0)	40.1 (11.6)
PWP (mm Hg)	8.8 (2.3)	8.1 (3.6)
CI (l/min/m <sup>2</sup> )	2.45 (0.69)	3.26 (0.09)
PVRI (IU/m <sup>2</sup> )	23.0 (10.4)	14.6 (8.9)
SvO <sub>2</sub> (%)	63 (16)	68 (9)
Acute vasodilator response, n (%)†±0 (0)		0 (0)

Group A, patients without pulmonary fibrosis on the chest radiograph; group B, patients with pulmonary fibrosis on the chest radiograph; mRAP, mean right atrial pressure; mPAP, mean pulmonary artery pressure; PWP, pulmonary wedge pressure; CI, cardiac index; PVRI, pulmonary vascular resistance index; SvO<sub>2</sub>, mixed venous oxygen saturation.

\*Time interval between the first symptoms related to sarcoidosis and the diagnosis of PH.

†Acute vasodilator response was tested with a short term intravenous infusion of epoprostenol or inhaled nitric oxide. A positive response was defined by a fall both in mPAP and PVRI of  $\geq 20\%$ .

‡Nine patients in group B were not tested.

diagnosed simultaneously in one patient in group A with radiographic stage II disease. One patient in group A had symptoms of Raynaud's disease.

Two patients had radiographic stage 0 disease at the time of PH diagnosis. The first was a 55 year old woman with known sarcoidosis affecting the skin and the stomach and hypercalcaemia. We had no information about her chest radiograph until she developed exertional dyspnoea 10 months after corticosteroids were stopped. At that time the chest radiograph was unremarkable but Doppler echocardiography revealed severe PH which was reversible when treated with corticosteroids but relapsed 12 months after they were tapered off, concomitantly with an increase in SACE at twice the upper limit of normal value. The chest radiograph remained normal. The patient was then referred for haemodynamic investigation. The second stage 0 patient was a 37 year old woman who was discovered with a stage II disease on routine chest radiography while she was clinically asymptomatic. She was placed on corticosteroids for 20 months and her chest radiograph normalised. Six months later she complained of increasing shortness of breath. The chest radiograph remained normal but Doppler echocardiography detected severe PH. SACE measurements were not available. The patient was then referred for haemodynamic investigation.

The controls were well matched with regard to their demographic characteristics (32 men and 12 women, mean (SD) age 46 (13) years, 75% white and 25% Afro-Caribbean) and extrapulmonary manifestations of sarcoidosis.

### Haemodynamic findings

The results are shown in table 1. PH tended to be more severe in group A patients (mPAP 51.7 (16.0) mm Hg *v* 40.1 (11.6) mm Hg, *p* = 0.07, and pulmonary vascular resistance index (PVRI) 23.0 (10.4) IU/m<sup>2</sup> *v* 14.6 (8.9) IU/m<sup>2</sup>, *p* = 0.06).

**Table 2** Functional ventilatory characteristics of patients at the time of PH diagnosis

	Group A (n = 7)	Controls (n = 14)	p value*	Group B (n = 15)	Controls (n = 30)	p value†
Pao <sub>2</sub> (kPa)	8.4 (2.3)	10.4 (1.1)	0.024	7.9 (1.5)	10.5 (1.5)	<0.0001
FEV <sub>1</sub> (ml)	2141 (481)	2504 (865)	0.329	1233 (482)	2030 (794)	0.001
FEV <sub>1</sub> (% pred)	75 (20)	84 (11)	0.204	38 (18)	56 (21)	0.01
FEV <sub>1</sub> /FVC (%)	75 (8)	72 (9)	0.483	63 (14)	67 (17)	0.449
FVC (ml)	2851 (649)	3648 (1269)	0.143	2051 (659)	3105 (1171)	0.003
FVC (% pred)	82 (18)	93 (9)	0.07	50 (16)	71 (23)	0.004
TLC (ml)	4688 (1022)	5247 (1312)	0.348	4198 (1109)	4827 (1465)	0.165
TLC (% pred)	84 (13)	92 (13)	0.235	67 (13)	73 (18)	0.265
Tlco (% pred)‡	39 (28)	86 (20)	0.0009	38 (10)	57 (19)	0.002
Kco (% pred)‡	41 (29)	88 (18)	0.0005	58 (19)	77 (22)	0.01

Group A, patients without pulmonary fibrosis on the chest radiograph; group B, patients with pulmonary fibrosis on the chest radiograph; Pao<sub>2</sub>, arterial oxygen tension at room air; FEV<sub>1</sub>, forced expiratory volume in 1 second; FVC, forced vital capacity; TLC, total lung capacity; Tlco, carbon monoxide transfer factor; Kco, carbon monoxide transfer coefficient.

Comparison with matched controls with sarcoidosis without PH.

\*Comparison between patients in group A and controls.

†Comparison between patients in group B and controls.

‡Tlco and Kco were not available in one patient in group A and two patients in group B.

PH was moderate (mPAP <35 mm Hg) in one patient in group A (14.3%) and in seven patients in group B (46.7%),  $p = NS$ .

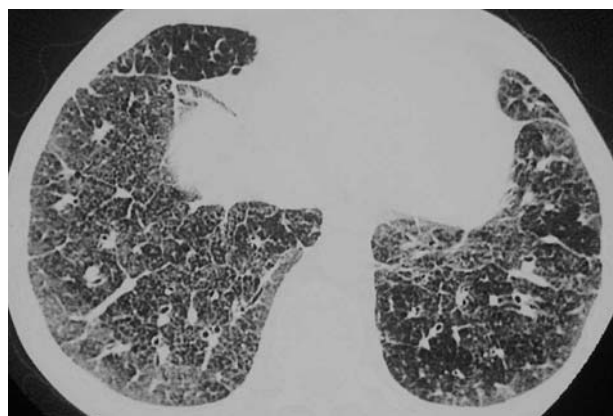
### Functional ventilatory findings

The results are shown in table 2. Patients in group A had nearly normal spirometric parameters or only a mild restrictive defect but a severe decrease in carbon monoxide transfer factor (Tlco) and carbon monoxide transfer coefficient (Kco). Two patients (28.6%) had significant hypoxaemia of  $\leq 55$  mm Hg, one of whom had right-to-left intracardiac shunting through a patent foramen ovale. No significant difference in lung volumes and flows were found between patients in group A and controls, but Tlco, Kco, and Pao<sub>2</sub> were significantly lower in patients with sarcoidosis and PH (table 2).

Pulmonary function was markedly changed in patients in group B (table 1). Pao<sub>2</sub> was  $\leq 7.3$  kPa in six patients (40.0%). All parameters were significantly more reduced in patients in group B than in controls, except for total lung capacity (TLC) and FEV<sub>1</sub>/FVC which were similar (table 2).

### HRCT findings

An HRCT scan was unavailable in one patient in group B. The occurrence of ground glass attenuation in patients in group A was significantly higher than in controls (85.7%  $\nu$  14.3%,



**Figure 1** HRCT pattern of sarcoidosis with pulmonary hypertension showing septal reticulations and ground glass attenuation in a patient with radiographic stage IV sarcoidosis. The scan shows septal lines that are frequently deformed and form a polygonal network in association with ground glass attenuation.

$p < 0.01$ ). Patients in group B had a significantly higher frequency of septal lines than controls (78.6%  $\nu$  46.4%,  $p = 0.047$ ), particularly when polygonal reticulations were drawn (71.4%  $\nu$  25%,  $p = 0.004$ ; fig 1). Extrinsic compression of large pulmonary arteries by adenopathies, defined as a reduction in the vascular lumen by over 50% after injection of contrast material, did not occur in group A and was present in three patients in group B (21.4%) at the mediastinal or hilar level. In these patients extrinsic arterial compression was established by pulmonary angiography. There was no evidence of pulmonary venous compression on the HRCT scans.

### Serum angiotensin converting enzyme

SACE was measured in 18 patients at the time of PH diagnosis; it was increased in three of five cases in group A and in three of 13 cases in group B.

### Correlations between haemodynamic and functional ventilatory findings

In each group we attempted to correlate mPAP and PVRI with the following pulmonary function parameters (% predicted): FEV<sub>1</sub>, FVC, TLC, FEV<sub>1</sub>/FVC%, Tlco, Kco, and Pao<sub>2</sub> on room air. In group A mPAP was only correlated significantly with Tlco ( $r = 0.847$ ,  $p = 0.03$ ) and tended to correlate with Kco without reaching the level of significance ( $r = 0.762$ ,  $p = 0.08$ ). PVRI was only significantly correlated with Pao<sub>2</sub> ( $r = 0.775$ ,  $p = 0.04$ ). In group B mPAP was only significantly correlated with Tlco ( $r = 0.684$ ,  $p = 0.01$ ) and there was a trend for mPAP to correlate with Kco ( $r = 0.521$ ,  $p = 0.07$ ). No relation was found between PVRI and any pulmonary function parameters.

### Treatment

Fourteen patients (63.6 %) were treated with long term oxygen and six received warfarin. No patient was given long term systemic vasodilator agents. One patient with radiographic stage IV disease received nebulised iloprost without any clinical benefit and died within 4 months while on the lung transplant waiting list.

### Patients treated with corticosteroids

Specific treatment for sarcoidosis was instituted because of PH in 10 patients (stage 0 (n = 1), stage II (n = 4), stage IV (n = 5)), all of whom were given high doses of oral prednisone ranging from 0.5 to 1 mg/kg/day combined with methotrexate 15 mg weekly in one case and with 3 monthly boluses of cyclophosphamide in another case. At the start of

**Table 3** Patients treated with corticosteroids for sarcoidosis and PH\*

Sex/age	Chest radiographic stage	Associated treatment	Systolic PAP		
			Baseline	3–6 months	Last evaluation
F/55	0	Methotrexate	66	35	<30 mm Hg at 12 months
M/61	II	Oxygen, warfarin	121	125†	Dead at 11 months
F/52	II	–	60	40	30 mm Hg at 14 months
M/28	II	–	77	60†	30 mm Hg at 36 months
M/63	II	–	80	82	Dead at 18 months
M/55	IV	–	50	55	Not re-evaluated
F/62	IV	–	45	45†	50 mm Hg at 18 months†
M/57	IV	Oxygen	80	85	Transplanted at 14 months
M/47	IV	–	83	100	Transplanted at 39 months
M/42	IV	Oxygen, Cyc	56	59	91 mm Hg at 48 months†

Cyc, intravenous cyclophosphamide.

\*Whatever the treatment at the time of PH diagnosis, each patient received at least high doses of oral prednisone (0.5–1 mg/kg).

†In these patients the measure obtained by Doppler echocardiography was confirmed by right heart catheterisation.

treatment the patients underwent right heart catheterisation and concurrent Doppler echocardiography. Systolic PAP was estimated as previously described.<sup>22</sup> The echocardiographic measures of systolic PAP were in good agreement with those obtained invasively ( $r = 0.967$ ,  $p < 0.0001$ ). The therapeutic response was evaluated after 3 or 6 months by Doppler echocardiography performed by the same cardiologist in all cases and also by right heart catheterisation in three cases. The results are shown in table 3. Systolic PAP remained stable or increased in seven patients (two with stage II disease and five with stage IV) and decreased more than 20% from baseline in the three remaining cases (one stage 0 and two stage II). In these three patients, corticosteroids were maintained at low doses and Doppler echocardiography totally normalised at 12, 14, and 36 months, respectively. Interestingly, before being referred to our centre, one of these three patients already had a history of sarcoidosis with PH that was reversed with corticosteroids but relapsed after the treatment was stopped (see above).

### Mortality and survival

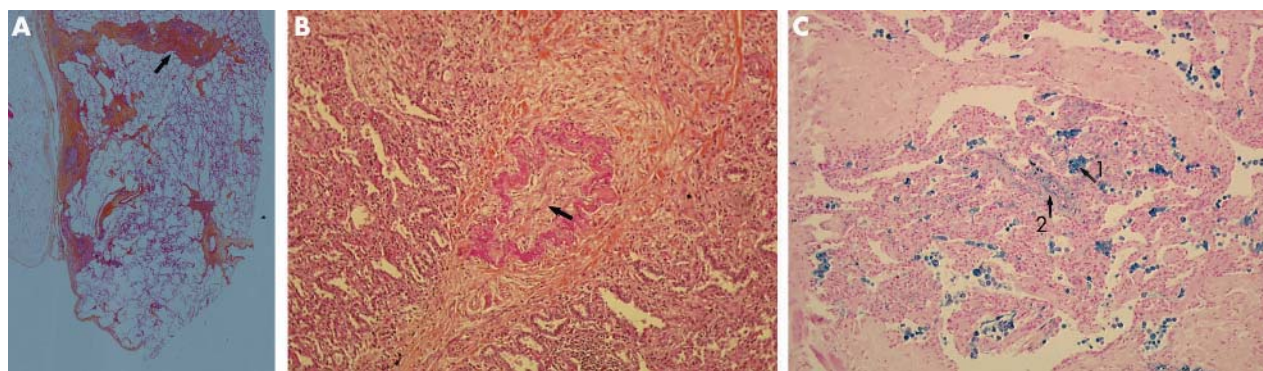
Patients were observed for 3.7 (3.5) years. At the end of the follow up period 10 patients were alive, seven had died, and five were transplanted (five stage IV). The causes of mortality were right ventricular failure in three cases (two stage II, one stage IV), sudden death in one (stage IV), end stage respiratory insufficiency in one (stage IV), pulmonary cancer in one (stage IV), and the cause was unknown in the remaining case (stage IV). Controls were observed for 7.5 (4.6) years. Two of them died (one of pulmonary cancer and

one from a surgery complication) and none was transplanted. The probability of survival of patients was significantly poorer than that of controls at 1, 2, and 5 years (84.8% *v* 100%, 73.5% *v* 96.4%, and 59.0% *v* 96.4%, respectively;  $p = 0.003$ ).

Univariate analysis was used to examine the relationship between survival and selected variables measured at initial right heart catheterisation. Mortality was not associated with patient age, sex, radiographic stage IV, any pulmonary function test including FEV<sub>1</sub> % predicted, FEV<sub>1</sub>/FVC%, FVC % predicted, TLC % predicted, Tlco % predicted, Kco % predicted, and Pao<sub>2</sub>, 6 minute walk test, and any haemodynamic parameters including mRAP, mPAP, CI, and PVRI. Only NYHA functional class IV was significantly related to an increased risk of death (15.15 (95% CI 2.77 to 83.33),  $p = 0.002$ ).

### Histopathology

Native lungs were obtained from the five transplanted patients. Pulmonary explants were examined after endobronchial formalin fixation; 22–30 tissue blocks were processed. Paraffin sections were studied with haematoxylin/eosin, elastic and iron stains. The main histological findings are summarised in table 4 and fig 2. In all cases sarcoidosis granulomas were fibrotic and scattered, and were not observed on each block. They were present in the parenchyma in all cases and in the mediastinal lymph nodes in three of the five cases. The vascular location of the granulomas was predominantly the veins (four of the five cases), while arterial granulomas were seen in only two cases and neither venous nor arterial granulomas could be found in



**Figure 2** Pulmonary explant, peripheral specimen, paraffin section. (A) Homogenous fibrosis of visceral pleura, interlobular septa (arrow) and perivascular spaces (magnification  $\times 2.5$ ; H&E stain). (B) Interlobular septal vein with occlusive intimal fibrosis (arrow) (magnification  $\times 20$ ; H&E stain). (C) Alveolar haemosiderosis (arrow 1) and iron deposits on elastic laminae (arrow 2) (magnification  $\times 20$ , iron stain).

**Table 4** Histological findings on native lungs obtained from the five transplanted patients\*

Sex/age	Haemodynamics		Sarcoidosis granulomas			Vascular lesions			Veins			Arteries			Perivascular fibrosis	Haemosiderosis
	mPAP (mm Hg)	PVRI (IU/m)	Nodes	Parenchyma	Arteries	Veins	Intimal fibrosis and/or medial hypertrophy	Plexiform lesions	Obliteration	Intimal fibrosis	Perivascular fibrosis	Haemosiderosis				
M/57	52	30.4	-	+	-	-	+	-	+	+	+	+	+	+	+	
M/39	33	7.3	+	+	-	+	+	-	+	+	+	+	+	+	+	
M/47	67	33.5	+	+	-	+	+	-	+	+	+	+	+	+	+	
M/39	51	19.1	-	+	+	+	+	-	+	+	+	+	+	+	+	
F/27	29	5	+	+	+	+	+	-	+	+	+	+	+	+	+	

\*All the patients had radiographic stage IV and severe pulmonary fibrosis on HRCT scanning.

†Histological vascular changes are recorded qualitatively: -, absent; +, present.

mPAP, mean pulmonary artery pressure; PVRI, pulmonary vascular resistance index.

one patient. Besides granulomatous involvement, occlusive venopathy consisting of occlusive intimal fibrosis and recanalisation was found in all cases (fig 2), while arterial lesions were minor with no plexiform or thrombotic lesions. All cases had evidence of chronic haemosiderosis and iron deposits on elastic laminae. Parenchymal changes were present in all cases and were homogenous within all blocks: fibrosis occurred in the subpleural space, interlobular septa and peribronchovascular sheets (fig 2).

## DISCUSSION

This study is the first to provide a comprehensive analysis of the underlying mechanisms of PH in a series of patients with sarcoidosis and PH. The results suggest that (1) sarcoidosis and PH can have two very different phenotypes depending on the presence or absence of pulmonary fibrosis; (2) specific mechanisms of PH can be multiple and vary from case to case, particularly in the presence of fibrotic disease; and (3) sarcoidosis and PH confers a severe vital prognosis.

Surprisingly, 31.8% of our patients developed PH in the absence of pulmonary fibrosis. In these patients the changes in lung function were mild, but mean TLCO was low and two patients had severe hypoxaemia ( $\leq 7.3$  kPa). Mean PAP was significantly correlated with TLCO and PVRI with Pao<sub>2</sub>. However, Pao<sub>2</sub> and TLCO were preserved or only slightly decreased in controls without PH, which suggests that hypoxaemia was the consequence rather than the cause of PH. In addition, no other cause of secondary PH was found. A fortuitous association between sarcoidosis and idiopathic PH cannot be definitively ruled out but seems unlikely because of the low incidence of each disease. Even if there is no histological proof, our findings strongly support the role of specific pulmonary vasculopathy, which presumably also induces the severe reduction in TLCO. Only a few similar cases have been reported in the literature,<sup>7 8 10-13 23</sup> two of whom had striking evidence of a histological pattern of granulomatous PVOD.<sup>11 12</sup> The two most typical HRCT features of PVOD are septal lines and ground glass attenuation.<sup>24 25</sup> Although these signs can also be seen in pulmonary sarcoidosis, our patients with non-fibrotic sarcoidosis and PH differed significantly from controls with sarcoidosis without PH in the very high frequency of ground glass attenuation (85.7% *v* 14.3%, *p*<0.01), which may possibly reflect the presence of PVOD. Interestingly, two of our patients had radiographic stage 0 disease at the time of PH diagnosis. In one previously reported case, comparisons of subsequent specimens obtained before and after established PH showed a clear progression in pulmonary vascular involvement while the parenchymal lesions of sarcoidosis remained relatively stable with corticosteroid treatment.<sup>10</sup> Similarly, in our two stage 0 patients we speculate that a pre-existing parenchymal component either responded to corticosteroid treatment or improved spontaneously while the vascular involvement worsened.

Most of the patients with sarcoidosis and PH had radiographic stage IV disease (68.2%). Pulmonary function, particularly Pao<sub>2</sub>, was significantly more changed in these patients than in controls without PH. A recent study by Shorr and colleagues<sup>5</sup> in a large cohort of patients with advanced sarcoidosis listed for lung transplantation showed that patients with PH have similar pulmonary function but require more supplemental oxygen than patients without PH. The discrepancy between these findings may result from the different selection methods. We failed to find a correlation between mPAP or PVRI and pulmonary function or Pao<sub>2</sub>, except mPAP with TLCO. Furthermore, mPAP was over 35 mm Hg in 53.3% of our patients, which was certainly out of proportion with the changes in lung mechanics.<sup>26</sup> Taken together, these findings suggest that—at least in some

stage IV cases—PH is not exclusively explained by the destruction of the vascular bed or hypoxaemia and that other mechanisms may also be involved. Extrinsic compression of large pulmonary arteries by mediastinal or hilar adenopathies was seen in 21.4% of our patients with pulmonary fibrosis and may be responsible for PH. With regard to the HRCT findings, our patients with fibrotic sarcoidosis and PH (group B) significantly differed from controls without PH in the frequency of septal lines (78.6% v 46.4%,  $p = 0.047$ ), particularly when they drew a polygonal network (71.4% v 25.0%,  $p = 0.004$ ), which raised the possibility of PVOD.

Vascular involvement is very common in pulmonary sarcoidosis, occurring in 69–100% of cases in pathological studies,<sup>27, 28</sup> and consists of occlusive or destructive lesions due to the invasion of vessel walls by granulomas or to the perivascular fibrosis. These changes can be observed at all levels from large branches of the pulmonary arteries to small veins, but are predominantly on the venous side.<sup>27, 28</sup> Despite frequent vascular involvement, however, PH is rare.<sup>28</sup> In our five transplanted patients with sarcoidosis and PH, examination of the lung revealed an original intrinsic venopathy with marked lesions of intimal fibrosis (fig 2). The role of this venopathy and its part in the development of PH is difficult to confirm since all these patients had advanced pulmonary fibrosis. Nevertheless, this hypothesis is supported by the fact that the venous lesions were occlusive, as indicated by the associated chronic haemosiderosis (fig 2C) in the absence of another cause of venous hypertension including proximal venous obstruction and mitral stenosis.<sup>29</sup>

PH is known to have a severe effect on outcome and to be a predictor of mortality in patients with sarcoidosis listed for lung transplantation.<sup>16, 17</sup> In our population survival was poor with a rate of 59.0% at 5 years after the diagnosis of PH and may have been overestimated since transplanted patients were considered as censored at the date of transplantation. Survival was significantly worse than in controls without PH. PH was the cause of 57.1% of deaths, but haemodynamic measures were not found to be associated with mortality. NYHA functional class IV was the only predictor of mortality. However, the statistical analysis was limited by the small number of patients in the study.

These results support treating PH in patients with pulmonary sarcoidosis, but the appropriate management of such a complication is not well defined. Little has been written about the benefits of corticosteroids in patients with sarcoidosis and PH, and the published data are somewhat discordant with some studies showing that PH can worsen despite corticosteroid treatment<sup>7, 10, 12, 13</sup> while others have reported a dramatic improvement.<sup>9, 23</sup> Gluskowski and colleagues studied the effects of corticosteroid treatment for 12 months on pulmonary haemodynamics in 24 patients with pulmonary sarcoidosis, three of whom had resting PH and 18 had an abnormal increase in mPAP on exercise.<sup>30</sup> Regression of the radiological changes and an improvement in lung function was observed in almost all patients, but this was accompanied by an improvement in the pulmonary haemodynamics in only half of them.<sup>30</sup> We found that corticosteroids had no effect in patients with pulmonary fibrosis but allowed a substantial and sustained improvement in PH in three of the five cases without pulmonary fibrosis, either alone or in association with methotrexate in one case. Interestingly, in one case with radiographic stage 0, PH recurred concomitantly with the reappearance of signs of sarcoidosis activity after corticosteroid treatment was stopped and was reversed when it was reintroduced. Pulmonary vasodilator therapy, including the use of new agents, has been successfully undertaken in patients with PH secondary to pulmonary fibrosis,<sup>31, 32</sup> but little is known about its

usefulness in the context of sarcoidosis and PH.<sup>14, 33</sup> In the small series studied by Preston and colleagues,<sup>14</sup> five patients with sarcoidosis and PH received long term inhaled nitric oxide (in addition to intravenous epoprostenol in one case) and two patients received long term oral calcium channel blockers, but the results were not convincing.

Our study therefore indicates that there are two very distinct phenotypes of sarcoidosis and PH depending on the presence or absence of pulmonary fibrosis. Cases with pulmonary fibrosis are not preceded by a prior history of PH without pulmonary fibrosis. Specific vasculopathy seems the sole mechanism of non-fibrotic sarcoidosis and PH but gives rise to a higher level of mPAP and sometimes responds to corticosteroid treatment. Combined with reports in the literature, these findings suggest that vasculopathy may differ between patients without or with pulmonary fibrosis. On the one hand, PVOD may result from an active granulomatous involvement of venous walls and, on the other, from an authentic intrinsic venopathy. Interestingly, pulmonary intrinsic venopathy has already been described in another granulomatous disorder, pulmonary histiocytosis X.<sup>34</sup>

The limitations of the study are that (1) it is a retrospective analysis; (2) the two participant centres are highly specialised in sarcoidosis (Avicenne Hospital) and pulmonary vascular disease (Antoine Béclère Hospital) which creates a selection bias and makes it impossible to evaluate the prevalence of PH in the general sarcoidosis population; and (3) the pathological material is limited and was not available for patients with non-fibrotic sarcoidosis and PH. However, we think it would have been unethical and risky to perform a lung biopsy in such cases.

We conclude that PH is a severe complication of sarcoidosis which has two very different phenotypes. In the absence of pulmonary fibrosis, treatment with an oral corticosteroid should be considered to treat PH complicating sarcoidosis since it may sometimes be efficacious. In patients with fibrotic disease, corticosteroids seem to be inactive and physicians may prefer to consider lung transplantation sooner than they would have done solely on the basis of lung function. Systemic vasodilator therapy should be used with caution in patients with sarcoidosis and PH because of its potential risk of precipitating pulmonary oedema in cases of PVOD.

#### Authors' affiliations

**H Nunes, M Brauner, J-P Battesti, D Valeyre**, UPRES EA 2363, Service de Pneumologie, Service de Radiologie, Hôpital Avicenne, Assistance Publique-Hôpitaux de Paris, Université Paris 13, Bobigny, France  
**H Nunes, M Humbert, F Capron, O Sitbon, G Simonneau**, UPRES EA 2705, Centre des Maladies Vasculaires Pulmonaires, Service de Pneumologie et Réanimation Respiratoire, Service d'Anatomie Pathologique, Hôpital Antoine Béclère, Assistance Publique-Hôpitaux de Paris, Université Paris Sud, Clamart, France

MH, OS and GS are supported by grants from Université Paris-Sud, Legs Poix, INSERM and AFM.

Competing interests: none.

#### REFERENCES

- 1 **Mayock RL**, Bertrand P, Morrison CE, *et al*. Manifestations of sarcoidosis: analysis of 145 patients, with a review of nine series selected from the literature. *Am J Med* 1963;**35**:67–89.
- 2 **Battesti J-P**, Georges R, Basset F, *et al*. Chronic cor pulmonale in pulmonary sarcoidosis. *Thorax* 1978;**33**:76–84.
- 3 **Rizzato G**, Pezzano A, Sala G, *et al*. Right heart impairment in sarcoidosis: haemodynamic and echocardiographic study. *Eur J Respir Dis* 1983;**64**:121–8.
- 4 **Gluskowski J**, Hawrylkiewicz I, Zych D, *et al*. Pulmonary haemodynamics at rest and during exercise in patients with sarcoidosis. *Respiration* 1984;**46**:26–32.

- 5 **Shorr AF**, Helman DL, Davies DB, *et al*. Pulmonary hypertension in advanced sarcoidosis: epidemiology and clinical characteristics. *Eur Respir J* 2005;**25**:783-8.
- 6 **Emirgil C**, Sobol BJ, Herbert WH, *et al*. The lesser circulation in pulmonary fibrosis secondary to sarcoidosis and its relationship to respiratory function. *Chest* 1971;**60**:371-8.
- 7 **Damuth TE**, Bower JS, Cho K, *et al*. Major pulmonary artery stenosis causing pulmonary hypertension in sarcoidosis. *Chest* 1980;**78**:888-91.
- 8 **Levine BW**, Saldana M, Hutter AM. Pulmonary hypertension in sarcoidosis. A case report of a rare but potentially treatable cause. *Am Rev Respir Dis* 1971;**103**:413-7.
- 9 **Davies J**, Nellen M, Goodwin JF. Reversible pulmonary hypertension in sarcoidosis. *Postgrad Med J* 1982;**58**:282-5.
- 10 **Smith LJ**, Lawrence JB, Katzenstein AL. Vascular sarcoidosis: a rare cause of pulmonary hypertension. *Am J Med Sci* 1983;**285**:38-44.
- 11 **Hoffstein V**, Ranganathan N, Mullen JBM. Sarcoidosis simulating pulmonary veno-occlusive disease. *Am Rev Respir Dis* 1986;**134**:809-11.
- 12 **Portier F**, Lerebourg-Pigeonniere G, Thiberville L, *et al*. Sarcoidosis simulating pulmonary veno-occlusive disease. *Rev Mal Respir* 1991;**8**:101-2.
- 13 **Barst RJ**, Ratner SJ. Sarcoidosis and reactive pulmonary hypertension. *Arch Intern Med* 1985;**145**:2112-4.
- 14 **Preston IR**, Klinger JR, Landzberg MJ, *et al*. Vasoresponsiveness of sarcoidosis-associated pulmonary hypertension. *Chest* 2001;**120**:866-72.
- 15 **Salazar A**, Mana J, Sala J, *et al*. Combined portal and pulmonary hypertension in sarcoidosis. *Respiration* 1994;**61**:117-9.
- 16 **Neville E**, Walker AN, James DG. Prognostic factors predicting the outcome of sarcoidosis: an analysis of 818 patients. *Q J Med* 1983;**52**:525-33.
- 17 **Shorr AF**, Davies DB, Nathan SD. Predicting mortality in patients with sarcoidosis awaiting lung transplantation. *Chest* 2003;**124**:922-8.
- 18 **Sitbon O**, Humbert M, Jagot J-L, *et al*. Inhaled nitric oxide as a screening agent to safely identify responders to oral calcium-channel blockers in primary pulmonary hypertension. *Eur Respir J* 1998;**12**:265-70.
- 19 **Quanjer PH**. Standardized lung function testing. *Eur Respir J* 1993;**6**(Suppl.16):3-102.
- 20 **Brauner MW**, Grenier P, Mompoin D, *et al*. Pulmonary sarcoidosis: evaluation with high-resolution CT. *Radiology* 1989;**172**:467-71.
- 21 **Abehsera M**, Valeyre D, Grenier P, *et al*. Sarcoidosis with pulmonary fibrosis: CT patterns and correlation with pulmonary function. *AJR Am J Roentgenol* 2000;**174**:1751-7.
- 22 **Currie PJ**, Seward JB, Chan KL, *et al*. Continuous wave Doppler determination of right ventricular pressure: a simultaneous Doppler-catheterization study in 127 patients. *J Am Coll Cardiol* 1985;**6**:750-6.
- 23 **Rodman DM**, Lindenfeld J. Successful treatment of sarcoidosis-associated pulmonary hypertension with corticosteroids. *Chest* 1990;**97**:500-2.
- 24 **Holcomb BW Jr**, Loyd JE, Ely EW, *et al*. Pulmonary veno-occlusive disease: a case series and new observations. *Chest* 2000;**118**:1671-9.
- 25 **Resten A**, Maitre S, Humbert M, *et al*. Pulmonary hypertension: CT of the chest in pulmonary venoocclusive disease. *AJR Am J Roentgenol* 2004;**183**:65-70.
- 26 **Weitzenblum E**, Ehrhart M, Rasaholinjanahary J, *et al*. Pulmonary hemodynamics in idiopathic pulmonary fibrosis and other interstitial pulmonary diseases. *Respiration* 1983;**44**:118-27.
- 27 **Rosen Y**, Moon S, Huang CT, *et al*. Granulomatous pulmonary angiitis in sarcoidosis. *Arch Pathol Lab Med* 1977;**101**:170-4.
- 28 **Takemura T**, Matsui Y, Saiki S, *et al*. Pulmonary vascular involvement in sarcoidosis: a report of 40 autopsy cases. *Hum Pathol* 1992;**23**:1216-23.
- 29 **Chazova I**, Robbins I, Loyd J, *et al*. Venous and arterial changes in pulmonary veno-occlusive disease, mitral stenosis and fibrosing mediastinitis. *Eur Respir J* 2000;**15**:116-22.
- 30 **Gluskowski J**, Hawrylkiewicz I, Zych D, *et al*. Effects of corticosteroid treatment on pulmonary haemodynamics in patients with sarcoidosis. *Eur Respir J* 1990;**3**:403-7.
- 31 **Olschewski H**, Ghofrani HA, Walmrath D, *et al*. Inhaled prostacyclin and iloprost in severe pulmonary hypertension secondary to lung fibrosis. *Am J Respir Crit Care Med* 1999;**160**:600-7.
- 32 **Ghofrani HA**, Wiedemann R, Rose F, *et al*. Sildenafil for treatment of lung fibrosis and pulmonary hypertension: a randomised controlled trial. *Lancet* 2002;**360**:895-900.
- 33 **Humbert M**, Sitbon O, Simonneau G. Treatment of pulmonary arterial hypertension. *N Engl J Med* 2004;**351**:1425-36.
- 34 **Fartoukh M**, Humbert M, Capron F, *et al*. Severe pulmonary hypertension in histiocytosis X. *Am J Respir Crit Care Med* 2000;**161**:216-23.