PostScript

LETTERS TO THE EDITOR

If you have a burning desire to respond to a paper published in *Thorax*, why not make use of our ''rapid response'' option?

Log on to our website (www.thoraxjnl.com), find the paper that interests you, and send your response via email by clicking on the ''eLetters'' option in the box at the top right hand corner.

Providing it isn't libellous or obscene, it will be posted within seven days. You can retrieve it by clicking on ''read eletters'' on our homepage.

The editors will decide as before whether to also publish it in a future paper issue.

VEGF in idiopathic ILD

Simler *et al* raise an interesting possibility of the prognostic value of plasma VEGF in interstitial lung disease.[1] Meyer *et al*[2] in a previous study did not find any difference in serum VEGF165 levels in patients with diffuse parenchymal lung disease. It would have been interesting to know the bronchoalveolar lavage (BAL) fluid levels of VEGF in these patients as Meyer *et al*[2] and Koyama *et al*[3] have shown reduced BAL fluid VEGF levels in interstitial lung disease. This might simply reflect damage to the alveolar epithelium (a known major source) in this disease or, indeed, VEGF may have an important role in the pathogenesis of interstitial disease. Interestingly, VEGF receptor blockade has been shown to lead to an induction of apoptosis and an emphysema-like histological appearance in rats but with no evidence of fibrosis or inflammatory cells.[4]

In addition, it is interesting to speculate on the cellular source of the increased plasma levels of VEGF in the more fibrotic patients. Could this represent alveolar-capillary membrane damage with leakage of intra-alveolar VEGF which is known to be compartmentalised and hence lower BAL fluid levels as described in the previous studies?[5] Or does it represent an inflammatory cell source of systemic VEGF correlating with an inflammatory response that is here associated with a poorer outcome? Or is there some other mechanism?

Finally, Koyama *et al*[3] have shown that smokers also have reduced BAL fluid levels of VEGF and this may be of relevance (if intrapulmonary VEGF is postulated as having a role in this disease), given that the patients with desquamative interstitial pneumonia had all smoked compared with 50% of those with non-specific interstitial pneumonia and only 20% of the controls.

A R L Medford
Lung Research Group, Division of Medicine, Southmead Hospital, Bristol BS8 3LP, UK; andrew.medford@bristol.ac.uk

References

1 **Simler NR**, Brenchley PE, Horrocks AW, *et al*. Angiogenic cytokines in patients with idiopathic interstitial pneumonia. *Thorax* 2004;**59**:581–5.
2 **Meyer KC**, Cardoni A, Xiang ZZ. Vascular endothelial growth factor in bronchoalveolar lavage from normal subjects and patients with diffuse parenchymal lung disease. *J Lab Clin Med* 2000;**135**:332–8.
3 **Koyama S**, Sato E, Haniuda M, *et al*. Decreased level of vascular endothelial growth factor in bronchoalveolar lavage fluid of normal smokers and patients with pulmonary fibrosis. *Am J Respir Crit Care Med* 2002;**166**:382–5.
4 **Kasahara Y**, Tuder RM, Taraseviciene-Stewart L, *et al*. Inhibition of VEGF receptors causes lung cell apoptosis and emphysema. *J Clin Invest* 2000;**106**:1311–9.
5 **Kaner RJ**, Crystal RG. Compartmentalization of vascular endothelial growth factor to the epithelial surface of the human lung. *Mol Med* 2001;**7**:240–6.

Authors' reply

Dr Medford laudably highlights the interesting findings of other authors regarding levels of vascular endothelial growth factor (VEGF) in idiopathic interstitial pneumonia (IIP). Indeed, our data reflect the findings of Meyer *et al* who studied 11 patients with IIP.[1] We extend their observations in a larger cohort of patients (n = 49) and specifically relate plasma VEGF levels to disease progression and extent of fibrosis on HRCT scanning.[2] Indeed, HRCT scanning is perhaps the most reliable surrogate for the extent of disease.[3] Like Meyer *et al*, we observed reduced median bronchoalveolar lavage (BAL) fluid levels of VEGF in patients with IIP (91 pg/ml) compared with controls (204 pg/ml). The reduction in the BAL fluid level of VEGF may reflect the absence of angiogenesis in that specific part of the lung, with the plasma VEGF level identifying a secondary phenomenon of compensatory angiogenesis in alternative areas of the lung. Alternatively, VEGF levels appear to be higher in epithelial surface fluid than in the serum, suggesting vectorial intraluminal secretion and the existence of a concentration gradient from air spaces to intravascular spaces.[1]

Thickett *et al*[4] are correct in their quotation of the normal range for VEGF in plasma (36–76 pg/ml) as measured by the R&D Systems Quantikine ELISA kit. They point out that this range is quoted by the kit manufacturers and is consistent with their own data and, indeed, with our data in other studies.[5–7] We did not use the Quantikine kit in this study but stated clearly that: ''The ELISA capture and detection antibodies for assaying IL-8 and VEGF were selected paired reagents optimised for ELISA performance from R&D Systems''. R&D currently sell these paired reagents under the name ''Duoset''.

Different ELISA formats for VEGF quantitation using recombinant VEGF165 as standard are available. Capture reagent: (1) rabbit polyclonal antiVEGF (in house); (2) soluble flt-1 (Sflt-1); (3) Quantikine kit, mouse anti-VEGF; (4) Duoset, mouse anti-VEGF. Detection reagent: (1) mouse anti-VEGF (Genetech 4.6.1);[8] (2) rabbit anti-VEGF;[5] (3) mouse anti-VEGF;[5 7 9] (4) mouse anti-VEGF.[2] Not surprisingly, each assay reports a different normal range. In our experience the Quantikine kit measures low (with up to a third of samples having undetectable levels) and the Duoset combination measures high, as we reported in the article (648 pg/ml). The other assays report intermediate values.

A number of possibilities exist as to why these assays read differently. It is unlikely to be due to platelet release as suggested.[5] The greatest difference in VEGF levels that is detected between paired serum (complete platelet release of VEGF) and standard plasma samples (low platelet VEGF release) is at most only three to four fold. Similarly, the difference in VEGF between paired platelet poor and platelet rich plasma samples is of the same order of magnitude. To demonstrate this one has to spin plasma samples at 2700*g* for 15 min to prepare platelet poor samples. In our experience it is important to use plasma rather than serum samples to quantitate VEGF and to treat each study sample similarly in terms of centrifugation—whether it be 300*g* for 12 min, 1000*g* for 15 min, or 2700*g* for 15 min. This will minimise variation in the study samples due to the ''platelet release effect''.

There are possible explanations for the VEGF immunoassays reading differently in plasma. It may be a combination of at least two effects—the nature of the epitope detected and the presence of other competing ligands in the sample. Different antibodies raised to VEGF will react variably with available epitopes on the ligand. This can be quite striking with monoclonal antibodies to different epitopes of a ligand when they are used as ELISA capture reagents. Assuming antibody A reacts with an epitope on VEGF that is close to or part of the flt-1 receptor binding site and the other antibody B reacts with an epitope well removed from this site, with an identical absolute amount of VEGF in the plasma sample, antibody A would read low or negative and antibody B would read high in relation to the amount of sflt-1 present in the plasma sample. We have in fact shown that the capture antibody used in the Quantikine VEGF ELISA is, indeed, sensitive to the presence of sflt-1.[5]

In addition to this potential variation in the level of free VEGF and VEGF-sflt-1 complexes in plasma samples, a further confounding species is the amount of placenta growth factor (PLGF). VEGF is a natural homodimer but it does form heterodimers with PLGF and we have detected such complexes.[10] Antibodies detecting epitopes that are variably modulated by the binding of PLGF to VEGF will read low or high depending on the PLGF concentration. This focuses on the nature of the R&D Systems monoclonal antibodies to VEGF—one in the Quantikine kit and the other part of the Duoset. Following the recognition of a difference in performance of these two assays, we contacted R&D Systems for information concerning the nature of these antibodies. We were interested to know if the same antibody or different antibodies were used and what information was available on their specificity. The response from R&D Systems was that the capture antibodies were different, so the scenario outlined above is a possible explanation.

It is important to appreciate the difficulties in interpreting absolute levels of VEGF in complex media such as plasma. To do this rigorously one ought to quantitate not only free VEGF but also VEGF complexes with sflt-1, sKDR, and PLGF to understand how one immunoassay measures against another, and currently this is not possible. It would be simplistic to think that the Quantikine kit values are the ''true'' VEGF values and the Duoset assay values artefactual. It might simply reflect the fact that the Quantikine values are free VEGF and the Duoset values total VEGF (free VEGF plus VEGF complexes).

The important observation in our study is not the absolute VEGF plasma values but the relative differences in VEGF levels between patients and control samples over time, where the sampling issues have been fully appreciated and rigorously controlled to allow clinical interpretation of the results. We have emphasised the prognostic value of plasma VEGF in idiopathic pulmonary fibrosis and have shown a significant positive relationship between the HRCT fibrosis score and the plasma concentration of VEGF. A comparison with acute respiratory distress syndrome (ARDS) is not useful and perpetuates the concept that ARDS equates with chronic idiopathic pulmonary fibrosis, which is not the case.

In relation to the point about quantitating local VEGF concentrations in the lung where the influence of epithelial sflt-1 might be greater, it is to be expected that different assays could lead to a variation in reported VEGF levels for the reasons already discussed.

In conclusion, we have complete confidence in the validity and reproducibility of the VEGF data presented. In a situation of excess VEGF production which could potentially be driving an angiogenic fibrotic pathology in the lung, we suggest it is entirely appropriate to contemplate antagonising excess VEGF in order to control the disease pathophysiology. Overdosing on VEGF antagonist is clearly counterproductive and, as stated, could lead to the apoptosis of both epithelial and endothelial cells. Clearly, it is a case of restoring homeostasis.

I Saleem
Department of Respiratory Medicine, Mater Misericordiae Hospital, University College Dublin, Dublin 7, Ireland

P E Brenchley
Renal Research Laboratory, Manchester Royal Infirmary, Manchester M13 9WL, UK

N R Simler
Royal Brompton Hospital, London, UK

J J Egan
Department of Respiratory Medicine, Mater Misericordiae Hospital and St Vincents University Hospital, University College Dublin, Dublin 7, Ireland

Correspondence to: Dr J J Egan, Advanced Lung Disease and Lung Transplant Program, Dublin Molecular Medicine Center, The Mater Misericordiae Hospital and St Vincent's University Hospital, University College Dublin, Dublin 7, Ireland; jegan@mater.ie

References

1 **Meyer KC**, Cardoni A, Xiang ZZ. Vascular endothelial growth factor in bronchoalveolar lavage from normal subjects and patients with diffuse parenchymal lung disease. *J Lab Clin Med* 2000;**135**:332–8.
2 **Simler NR**, Brenchley PE, Horrocks AW, *et al.* Proinflammatory and angiogenic cytokines in patients with idiopathic interstitial pneumonia. *Thorax* 2004;**59**:581–5.
3 **Gay SE**, Kazerooni EA, Ttoews GB, *et al.* Idiopathic pulmonary fibrosis. Predicting response to therapy and survival. *Am J Respir Crit Care Med* 1998;**157**:1063–72.
4 **Thickett DR**, Armstrong L, Christie SJ, *et al.* Vascular endothelial growth factor may contribute to increased vascular permeability in acute respiratory distress syndrome. *Am J Respir Crit Care Med* 2001;**164**:1601–5.
5 **Webb NJA**, Bottomley MJ, Watson CJ, *et al.* VEGF is released from platelets on blood clotting: implications for the measurement of VEGF in clinical disease. *Clin Sci* 1998;**94**:395–404.
6 **Webb NJA**, Watson CJ, Roberts ISD, *et al.* Circulating VEGF is not increased during relapses of steroid sensitive nephrotic syndrome. *Kidney Int* 1999;**55**:1063–71.
7 **Young HS**, Summers AM, Bhushan M, *et al.* Single nucleotide polymorphisms of VEGF in psoriasis of early onset. *J Invest Dermatol* 2004;**122**:209–15.
8 **Webb NJA**, Myers CR, Watson CJ, *et al.* Activated human neutrophils express vascular endothelial growth factor (VEGF). *Cytokine* 1998;**10**:254–7.
9 **Watson CJ**, Webb NJA, Bottomley MJ, *et al.* Identification of polymorphisms within the vascular endothelial growth factor gene: correlation with variation in VEGF protein production. *Cytokine* 2000;**12**:1232–5.
10 **Bottomley MJ**, Webb N, Watson CJ, *et al.* Placenta growth factor (PLGF) induces VEGF secretion from mononuclear cells and is co-expressed with VEGF in synovial fluid. *Clin Exp Immunol* 2000;**119**:182–8.

CARD 15 gene mutations in sarcoidosis

In the last few years substantial progress has been made in unravelling the genetic basis of susceptibility to Crohn's disease. Three CARD 15 (previously called NOB_2) genetic variants, resulting in proteins with modified carboxy terminal regions, have been implicated.[1 2] 43% of patients with Crohn's disease carry at least one of these CARD 15 mutations (compared with 15% of healthy controls).[1] Mutations in CARD 15 have also been identified in affected members of families with Blau syndrome.[3 4] This is a rare autosomal dominant disorder, sometimes referred to as familial sarcoidosis, characterised by granuloma formation in joints, skin, and uvea.

Card 15 is a microbial sensing protein involved in innate immunity. It recognises conserved structural components of microorganisms (bacterial muramyl dipeptide, MDP and peptidoglycan, PGN) and is part of the danger signal pattern recognition network which forms the front line of protective immunity. Mutations associated with Crohn's disease render the molecule insensitive to MDP and interfere with the downstream activation of NF-κB. One potential result of this may be the persistence of an antigen resulting in engagement of other arms of the adaptive immune system and formation of granulomas. Expression of CARD 15 in monocytes (precursors of macrophages and granulomas) further supports its potential role in granuloma formation. We hypothesised that mutations in CARD 15 may be a unifying defect in the multisystemic granulomatous diseases of Crohn's disease, sarcoidosis, and Blau syndrome.

To investigate this we recruited a cohort of 29 patients with sarcoidosis from the Oxford Centre for Respiratory Medicine. All had a typical clinical picture of sarcoidosis and either histologically proven disease or characteristic Lofgren's syndrome (defined as an acute onset of disease with erythema nodosum, joint pains, and bilateral hilar lymphadenopathy). The diagnosis of sarcoidosis was also supported by the characteristic appearance of the lungs on a high resolution computed tomographic (CT) scan in all patients. The definition and diagnosis of sarcoidosis adheres to the statement on sarcoidosis adopted by the joint committees of WASOG/ATS/ERS.[5] The patients were first diagnosed between the ages of 25 and 40 years and had been followed up for at least 1 year before recruitment. All were white and one third presented with Lofgren's syndrome. Written informed consent was obtained for genetic analysis and the study was approved by the local ethics committee.

The entire coding region of CARD 15 (11 exons and flanking intronic sequences) was screened for the presence of mutations. In brief, the CARD 15 gene was amplified from the genomic DNA samples by polymerase chain reaction (PCR) using primers as previously described[6] and sequenced on an ABI 377 automated sequencer using a Dye Terminator Cycle Sequencing Ready reaction kit (Perkin Elmer Applied Biosystems, CA, USA). Sequence data were then aligned using the Sequence Navigator analysis software Version 1.0.1 (Perkin Elmer Applied Biosystems) and compared with the known CARD 15 sequence (EMBL accession number AJ303140).

435 sequence analyses were performed in the 29 patients. We were therefore able to detect new alleles putatively associated with the sarcoidosis phenotype with frequencies as low as 2%. The three mutations associated with Crohn's disease were specifically examined. The R702W mutation was observed in one patient with sarcoidosis while the G908R and the 1007fs mutations were not found. These results were not different from those reported previously in control populations where the mutations R702W, G908R and 1007fs were present in 4%, 1%, and 2% of 103 European healthy controls.[6] Furthermore, they do not differ from data derived from healthy controls recruited in the UK.[7 8] The codons 334 and 469 reported to be involved in Blau syndrome were also carefully scrutinised but we did not detect any genetic variation in our sarcoidosis patients. No additional mutations were seen within the rest of the coding region of the gene, suggesting that there were no specific alternative CARD 15 mutations associated with sarcoidosis. Schurmann and colleagues[9] recently found no correlation between specific CARD 15 polymorphic alleles and patients with sarcoidosis from families with more than one member afflicted by the disease. This study provides evidence that CARD 15 is not associated with non-familial sarcoidosis (in patients with a white ethnic background) and that there are no mutations in any part of the coding region of the CARD 15 gene in these patients.

There is little doubt that there is a genetic predisposition in sarcoidosis, as indicated by the presence of familial clustering, ethnic susceptibility, and recent evidence of an association with HLA-DRB1.[10] The search for this susceptibility gene(s) has recurrently pointed to a locus near the HLA DR region on chromosome 6. This and the exclusion of the NOD2 locus has focused attention on abnormalities in antigen presentation and cytokine/chemokine receptors as a potential basis for the aetiology of sarcoidosis.

L-P Ho, A J McMichael
MRC Human Immunology Unit, Weatherall Institute of Molecular Medicine, Oxford University, Oxford OX3 9DS, UK

L-P Ho, R J O Davies
Oxford Centre for Respiratory Medicine, Churchill Hospital, Oxford OX3 7LJ, UK

K Gaber
Royal Devon and Exeter Hospital, Exeter EX2 5DW, UK

J-P Hugot, F Merlin
Fondation Jean Dausset/CEPH, Paris, France

J-P Hugot
INSERM U458, Hopital Robert Debré, AP-HP, Paris, France

Correspondence to: Dr L-P Ho, MRC Human Immunology Unit, Weatherall Institute of Molecular Medicine, The John Radcliffe Hospital, Oxford OX3 9DS, UK; ling-pei.ho@imm.ox.ac.uk

This study received funding from the MRC (UK), Oxfordshire Health Research Committee, the fondation Jean Dausset, and the Institut National de le Santé et de la Recherche Médicale. Dr L P Ho is a recipient of an MRC Fellowship.

References

1 **Hugot JP**, Chamaillard M, Zouali, et al. Association of NOD2 leucine-rich repeat variants with susceptibility to Crohn's disease. *Nature* 2001;**411**:599–603.
2 **Ogura Y**, Bonen DK, Inohara N, *et al*. A frameshift mutation in NOD2 associated with susceptibility to Crohn's disease. *Nature* 2001;**411**:603–6.
3 **Miceli-Richard C**, Lesage S, Rybojad M, *et al*. CARD15 mutations in Blau syndrome. *Nat Genet* 2001;**29**:19–20.
4 **Wang X**, Kuivaniemi H, Bonavita G, *et al*. CARD15 mutations in familial granulomatosis syndromes: a study of the original Blau syndrome kindred and other families with large-vessel arteritis and cranial neuropathy. *Arthritis Rheum* 2002;**46**:3041–5.
5 **Anon**. Statement on sarcoidosis. *Am J Respir Crit Care Med* 1999;**160**:736–55.
6 **Lesage S**, Zouali H, Cezard JP, *et al*. CARD15/NOD2 mutational analysis and genotype-phenotype correlation in 612 patients with inflammatory bowel disease. *Am J Hum Genet* 2002;**70**:845–57.
7 **Cuthbert AP**, Fisher SA, Mirza MM, *et al*. The contribution of NOD2 gene mutations to the risk and site of disease in inflammatory bowel disease. *Gastroenterology* 2002;**122**:867–74.
8 **Ahmad T**, Armuzzi A, Bunce M, *et al*. The molecular classification of the clinical manifestations of Crohn's disease. *Gastroenterology* 2002;**122**:854–66.
9 **Schurmann M**, Valentonyte R, Hampe J, *et al*. CARD 15 gene mutations in sarcoidosis. *Eur Respir J* 2003;**22**:748–54.
10 **Rossman MD**, Thompson B, Frederick M, *et al*. HLA-DRB1*1101: a significant risk factor for sarcoidosis in blacks and whites. *Am J Hum Genet* 2003;**73**:729–35.

Infected pulmonary sequestration caused by *Mycobacterium kansasii*

Mycobacterium kansasii is the second most common non-tuberculous mycobacterium associated with lung disease in the United States.[1] Diseases are almost always cavitary, involving the upper lobes with fibrosis and infiltrations. Underlying pulmonary diseases associated with *M kansasii* infection include pneumoconiosis, chronic obstructive lung disease, AIDS and malignancy. To our knowledge, *M kansasii* has never been reported in the English literature in the aetiology of infected pulmonary sequestration. We report a case of intralobar sequestration complicated by infection with *M kansasii*.

A 33 year old man was previously healthy. An abnormal finding on the chest radiograph had been noted at a routine health check 1.5 years earlier. He had no history of medical illness and no risk factors for HIV infection. No symptoms attributed to his respiratory system, such as cough, haemoptysis or dyspnoea, were noted. Constitutional symptoms including malaise, fever, night sweats, anorexia, or weight loss were lacking. Physical examination revealed systolic bruit at the left basal lung. There was neither cyanosis nor digital clubbing. Oxygen saturation by pulse oximetry was 99% while breathing room air. Blood laboratory studies disclosed a white blood cell (WBC) count of 7.4×10^9/l (neutrophils 60.7%, lymphocytes 13.6%), and the level of carcinoembryonic antigen (CEA) was 1.33 ng/ml (reference value <3 ng/ml). Sputum acid-fast stain and mycobacterial cultures were all negative. Bronchoscopic examination showed no endobronchial abnormality. A chest radiograph taken at admission and a computed tomographic scan showed a patchy consolidation over the left basal lung. Magnetic resonance imaging (MRI) and angiography of the chest showed that an aberrant bronchial artery had arisen from the left side of the thoracic aorta and crossed the territory of the consolidation patch, but the venous drainage could not be visualised clearly (fig 1).

The patient underwent lobectomy of the left lower lobe by video-assisted thoracoscopic surgery (VATS). A 14×10 cm area of consolidation over the left lower lobe was noted and cystic formation and profuse sputum were found within the lesion. The three feeding arteries from the aorta at the level of the 10th thoracic spine were seen. Microscopically, the parenchyma revealed bronchiolitis and microabscess formation. Granulomatous inflammation was also present, but no organisms were identified by acid fast and Grocott's methenamine silver (GMS) stains (fig 2). The biopsy tissue was ground and inoculated onto Lowenstein-Jensen slant (BBL Microbiology Systems, Cockeysville, MD, USA) and cultured at 35℃ in a CO_2 incubator. After 19 days of incubation the culture yielded a photochromogen which was later identified as *M kansasii* using conventional biochemical methods. The patient had an uneventful postoperative course and was discharged soon after operation. No anti-mycobacterial regimen was administered after the diagnosis was made and the patient's clinical status remained uneventful at the 3 month follow up.

Pulmonary sequestration is a congenital malformation characterised by the presence of lung tissue with abnormal or absent communication with the bronchial tree and arterial blood supply from the systemic circulation. Despite the high frequency of infection, few data are available regarding specific infecting organisms. Acute infections due to bacteria such as *Staphylococcus* and *Pseudomonas* have been reported,[2] and some chronic infections due to *Aspergillus*[3] and *Nocardia*[4] have also been described. Infected pulmonary sequestration due to mycobacteria including *M tuberculosis*[5] and *M avium-intracellulare*[6] have been reported only rarely. In our case, *M kansasii* was the first organism thought to be responsible for the infection of pulmonary sequestration in the absence of other pulmonary or extrapulmonary involvement. It is assumed that the organism reaches the sequestration through Kohn's pore without causing evident disease in the normal lung parenchyma.

The combination of isoniazid, rifampin, and ethambutol was recommended for treatment of *M kansasii* pulmonary disease.[1] However, surgical removal should be advocated in both asymptomatic and symptomatic cases of pulmonary sequestration and the benefit of a period of preoperative antimicrobial treatment in infected pulmonary sequestration has been debated.[7] Our patient simply underwent a surgical resection and did not receive any anti-mycobacterial agents.

We have reported the unique occurrence of pulmonary sequestrartion with *M kansasii* infection. Surgical resection allows establishment of the exact diagnosis and immediate removal of the infectious focus, thus preventing complications related to the infection or to the malformation itself.

Figure 1 Magnetic resonance imaging (MRI) and angiography of chest showing the aberrant bronchial artery (arrow) arising from the thoracic aorta crossing the consolidation.

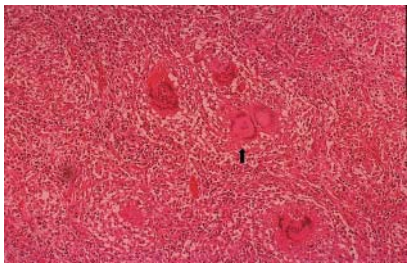

Figure 2 Microscopic section of the lung parenchyma showing microabscesses and granulomatous inflammation (arrow).

S H Lin
Department of Internal Medicine, Far Eastern Memorial Hospital, Taipei County, Taiwan

L N Lee, Y L Chang, Y C Lee, L W Ding, P R Hsueh
Departments of Internal Medicine, Laboratory Medicine, Pathology, and Surgery, National Taiwan University Hospital, National Taiwan University College of Medicine, Taipei, Taiwan

Correspondence to: Dr P R Hsueh, Departments of Laboratory Medicine and Internal Medicine, National Taiwan University Hospital, No 7, Chung-Shan South Road, 100 Taipei, Taiwan; hsporen@ha.mc.ntu.edu.tw

References

1 **American Thoracic Society**. Diagnosis and treatment of disease caused by nontuberculous mycobacteria. *Am J Respir Crit Care Med* 1997;**156**:S21–5.
2 **Collin PP**, Desjardins JD, Khan AH. Pulmonary sequestration. *J Pediatr Surg* 1987;**22**:750–3.
3 **Tanaka M**, Miyamoto H, Sakao Y, *et al*. A case report of intralobar sequestration associated with lung aspergillus. *Nippon Kyobu Gekkai Zasshi* 1995;**43**:366–70.
4 **Shihbli M**, Connery C, Shapiro JM. Intralobar and extralobar bronchopulmonary sequestration complicated by Nocardia asteroids infection. *South Med J* 2003;**96**:78–80.
5 **Elia S**, Alifano M, Gentile M, *et al*. Infection with Mycobacterium tuberculosis complicating a pulmonary sequestration. *Ann Thorac Surg* 1998;**66**:566–7.
6 **Shiota Y**, Arikita H, Aoyama K, *et al*. Pulmonary sequestration associated by Mycobacterium intracellulare infection. *Intern Med* 2002;**41**:990–2.
7 **Laberge JM**, Bratu I, Flageole H. The management of asymptomatic congenital lung malformations. *Paediatr Respir Rev* 2004;**5**(Suppl A):S305–12.