

CASE REPORT

Pulmonary vein thrombosis after bilobectomy and development of collateral circulation

P R Genta, N Ho, R Beyruti, T Yae Takagaki, M Terra-Filho

Thorax 2003;58:550–551

Pulmonary vein thrombosis is a rare but potentially life threatening complication following lobectomy or bilobectomy. We present a case of right upper pulmonary vein thrombosis after a middle and lower lobectomy diagnosed at transoesophageal echocardiography. The patient was treated with antibiotics and anticoagulation with good recovery. Pulmonary angiography was performed 35 days after surgery and revealed the venous return of the right lung through the intercostal veins. Despite double venous drainage of the lungs consisting of bronchial and pulmonary veins, pulmonary to systemic collaterals following pulmonary vein thrombosis have not previously been reported. The development of this shunt can prevent gangrene, and surgical resection of the lung segment involved can be avoided.

Pulmonary vein thrombosis has been observed in several situations including neoplasia, fibrosing mediastinitis, pulmonary veno-occlusive disease, hilar torsion, and after lung transplantation.^{1–3} Pulmonary vein thrombosis following lung lobectomy or bilobectomy is rare, and a high index of suspicion is necessary to diagnose this condition.^{2–6} The development of collateral circulation has been demonstrated in animal models after acute occlusion of pulmonary veins but has never been documented in humans.^{2–8}

Case report

A 29 year old white man underwent right middle and lower lobectomy to resect a well differentiated neuroendocrine carcinoma (atypical carcinoid tumour). An invasion of the right inferior pulmonary vein was detected and partial resection of the left atrium was necessary. The patient had an

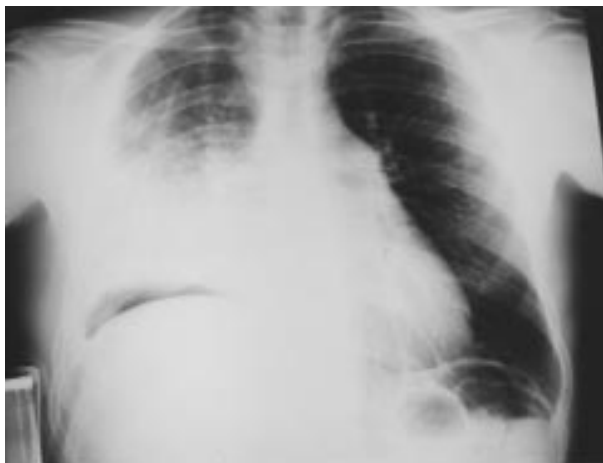

Figure 1 Chest radiograph obtained on the first postoperative day showing an infiltrate in the lower half of the right upper lobe.

uneventful immediate postoperative period and a chest radiograph showed a well aerated right upper lobe with elevation of the right hemidiaphragm. He developed fever on the first postoperative day and his chest radiograph revealed opacification of the lower half of the right upper lobe (fig 1). Intravenous ciprofloxacin was administered with good clinical improvement but with persistence of the lung infiltrate. Pulmonary vein thrombosis was suspected, and a transoesophageal echocardiogram did not detect flow in the right upper pulmonary vein. It also disclosed pulmonary hypertension with an estimated mean pulmonary arterial pressure of 46.5 mm Hg. Anticoagulation was then started. Pulmonary angiography performed 35 days after surgery showed preferential contrast flow to the left lung. This finding might indicate the development of a regimen of increased pressure at the right vascular bed. The right upper pulmonary vein was not visualised in the venous phase; instead, the venous return was seen through the intercostal veins (fig 2). Eighteen months after surgery the patient is in excellent condition without any restriction to physical activity. His current arterial blood gas analysis is pH 7.41, P_{O_2} 11.5 kPa, P_{CO_2} 5.2 kPa, SO_2 95.5%, bicarbonate 24 mmol/l, base excess 0. Anticoagulation with warfarin was maintained. His current estimated mean pulmonary artery pressure is 49 mm Hg.

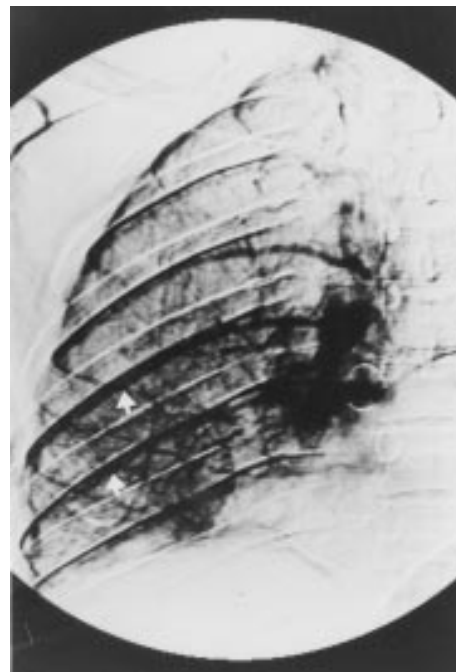


Figure 2 Venous phase of the pulmonary angiography showing venous return through the intercostal veins (white arrows).

DISCUSSION

Pulmonary vein thrombosis is a rare complication following lobectomy or bilobectomy. Signs and symptoms of this condition may include dyspnoea, haemoptysis, chest pain, fever, and hypoxaemia. Chest radiographic abnormalities include consolidation of the lung and pleural effusion. Diagnosis can be made by transoesophageal echocardiography, contrast enhanced helical computed tomography, ECG gated magnetic resonance imaging, or pulmonary angiography.¹⁻⁶

Six cases of pulmonary vein thrombosis after lobectomy have been reported in the literature.²⁻⁶ Four occurred after right middle and lower bilobectomies as in this case,^{2-4,6} one after right superior lobectomy,³ and one after left superior lobectomy.⁶ In five cases resection of the affected segment was undertaken (right superior lobectomy in three cases,^{2,5,6} middle lobectomy in one,³ and left inferior lobectomy in the other⁶). Reoperation was performed because of lack of clinical improvement and the possibility of pulmonary gangrene. Two patients died in the postoperative period.^{3,5} In only one patient was clinical observation alone chosen with no signs of pulmonary gangrene at follow up.⁴ Pulmonary angiography was performed in four of the six patients reported in the literature. A venous phase could not be detected in any case.^{2-4,6}

Acute pulmonary vein occlusion has been extensively studied in animal models. Survival of the animals was possible only when antibiotics were administered. Hurwitz *et al*⁷ demonstrated the development of an extensive collateral circulation through bronchial veins and pleural adhesions. Liebow⁸ showed a double venous drainage in normal human lungs consisting of pulmonary and bronchial veins which intercommunicate between each other. Proximal bronchial veins drain into the azygos, hemiazygos and intercostal veins and pulmonary veins drain into the left atrium. Under certain circumstances new connections between the pulmonary and systemic circulations can develop. After ligation of the pulmonary veins in dogs, adhesions between the chest wall and the lung in the region of the surgical incision are penetrated by venules that connect the intercostal with the pulmonary veins.^{7,8}

A high index of suspicion is necessary to make the diagnosis of pulmonary vein thrombosis. The occurrence of this complication after lobectomy or bilobectomy is rare but potentially

life threatening. Antibiotics are generally necessary because of secondary infection of the lung segment involved. Although surgical resection was undertaken in five of six cases reported in the literature, it may not be necessary in all cases. Failure of clinical improvement or suspicion of gangrene should lead to pulmonary resection. In our patient the response to antibiotics and anticoagulation allowed us to treat the patient conservatively.

Pulmonary to systemic collaterals via intercostal veins have not previously been reported after acute pulmonary vein thrombosis. The development of this shunt can prevent gangrene. The use of anticoagulants is uncertain but can avoid clot development in the left atrium and possibly promote recanalisation of the affected pulmonary vein.

Authors' affiliations

P R Genta, N Ho, R Beyruti, T Yae Takagaki, M Terra-Filho, Division of Respiratory Diseases, Heart Institute (InCor), University of São Paulo School of Medicine, São Paulo, Brazil

Correspondence to: Dr P R Genta, Rua General Mena Barreto 616, São Paulo, SP, CEP 01433-010, Brazil; prgenta@usp.br

Accepted for publication 8 April 2002

REFERENCES

- 1 **Selvidge SDD**, Gavanti ML. Idiopathic pulmonary vein thrombosis: detection by CT and MR imaging. *AJR* 1999;**172**:1639-41.
- 2 **Venter CP**, Dannheimer IPL. Pulmonary venous thrombosis complicating lobectomy. *S Afr Med J* 1973;**47**:2339-42.
- 3 **Urschel JD**. Venous thrombosis of the middle lobe after upper lobectomy. *Can Assoc Radiol J* 1993;**44**:133-4.
- 4 **Hovaguimian H**, Morris JF, Gately HL, *et al*. Pulmonary vein thrombosis following bilobectomy. *Chest* 1991;**99**:1515-6.
- 5 **Aldana-Díaz EM**, Fernández-Torres B, Herrera-Saval JC, *et al*. Unilateral pulmonary edema due to pulmonary vein thrombosis after bilateral lobectomy. *Rev Esp Anestesiol Reanim* 1996;**43**:375-8.
- 6 **Gyves-Ray KM**, Spizarny DL, Gross BH. Unilateral pulmonary edema due to postlobectomy pulmonary vein thrombosis. *AJR* 1987;**148**:1079-80.
- 7 **Hurwitz A**, Calabresi M, Cooke RW, *et al*. An experimental study of the venous collateral circulation of the lung: functional observations. *J Thorac Surg* 1954;**28**:241-6.
- 8 **Liebow AA**. The bronchopulmonary venous collateral circulation with special reference to emphysema. *Am J Pathol* 1953;**29**:251-89.