

## CASE REPORT

# Primary pleural lymphomas

H Ahmad, J Pawade, S Falk, J A Morgan, L Balacumaraswami

*Thorax* 2003;58:908–909

Two patients are presented with primary low grade pleural B cell lymphomas with no history of a pyothorax.

Pleural disease in non-Hodgkin's lymphoma is well documented and commonly presents with pleural effusions in 20% of patients.<sup>1</sup> However, solid pleural involvement is less common and is usually a secondary event. Primary pleural lymphomas are extremely rare and, in a series reported by Burgener and Hamlin, pleural plaques were seen in less than 4% of cases.<sup>2</sup>

Two types of primary pleural lymphomas have been described—the body cavity based lymphoma in patients with HIV and the pyothorax associated pleural lymphoma in those with tuberculosis. Primary pleural non-Hodgkin's lymphoma in an immunocompetent patient without a history of chronic pyothorax is extremely rare.

### CASE HISTORY 1

A 59 year old man presented with a 4 month history of gradually increasing shortness of breath and left sided chest pain. He was a non-smoker with a history of occupational exposure to asbestos (he had worked in power stations for over 30 years). On examination, air entry over the left side of his chest was diminished.

Investigations showed a normal full blood count, urea and electrolytes. His chest radiograph revealed a left sided pleural effusion. A chest drain was therefore inserted and approximately 7 litres of serous fluid were drained. A computed tomographic (CT) scan of the thorax showed a left pleural effusion with irregular thickening of the adjacent parietal pleura, extending medially to displace the aorta. Bilateral pleural calcification suggestive of asbestos exposure was also seen. No significant lymphadenopathy was noted. A bone marrow biopsy performed during this admission did not show any evidence of lymphoma. Video assisted thoracoscopy showed diffuse involvement of the parietal pleura from which biopsy samples were taken. Light microscopy showed lymphoid infiltration with a hint of nodularity. Isolated reactive germinal centres were buried within the infiltrate of medium sized lymphoid cells and mononuclear blasts (fig 1). Mitotic figures were easily visible. Immunohistochemical staining confirmed the dominant B cell nature of the infiltrate. The phenotype of the B cells was confirmed as CD43, CD23 and BCL-2 positive, and CD5 and CD10 negative. Follicular dendritic cells in lymphoid nodules were highlighted with CD23 and CD21, confirming follicular colonisation. Ki67 labelling was observed in 30% of the tumour population. These findings supported a diagnosis of low grade marginal zone lymphoma of the pleura. Also present in the sample were hyalinised plaques infiltrated by lymphoma on one surface.

DNA was extracted from paraffin embedded material and PCR was performed by standard methods using primers for the FR2 and FR3 regions of immunoglobulin heavy chain.

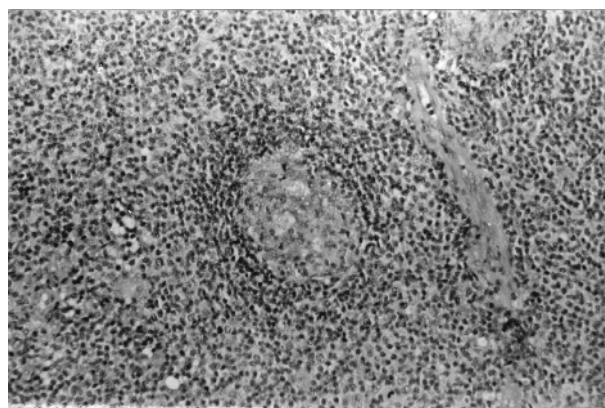
This showed a band, in keeping with the monoclonal nature of the disease. Pleurodesis with 5-fluorouracil was performed and the chest drain was eventually removed. The patient was treated with chlorambucil. Follow up at 18 months showed no evidence of lymphadenopathy or recurrence of the effusion.

### CASE HISTORY 2

A 49 year old non-smoker was admitted with a 4 month history of gradually increasing shortness of breath, an unproductive cough, and weight loss. His past medical history included tuberculosis diagnosed at the age of 18, the primary site of which was unknown. He was treated with streptomycin and followed up for 2 years with no further complications. On examination he was afebrile with no evidence of lymphadenopathy. Auscultation of his chest revealed reduced breath sounds on the left.

On admission his urea, electrolytes, and full blood count were essentially normal. A chest radiograph confirmed a left pleural effusion. Pleural fluid was therefore aspirated and cytological examination showed a cellular preparation rich in medium sized lymphocyte cells with smooth chromatin, a large number of plasma cells, and occasional mononuclear blasts. A population of smaller lymphocytes and mesothelial cells was also present. These features are in keeping with a low grade lymphoma. A CT scan of his thorax showed subcarinal nodes and a left pleural effusion. There was collapse of the upper lobe with the suggestion of a mass lesion which was thought to be thickened pleura. In addition, a bone marrow aspirate revealed normal haemopoietic tissue with no evidence of lymphoma.

On clinical grounds, the patient was started on antituberculous treatment with Rifinah and pyrazinamide. As he remained well he was discharged home with an appointment for video assisted thoracoscopy (VATS). During the VATS pleural biopsy more than 2.5 litres of clear fluid were drained. There was fibrin covering the parietal layers and dense adhesions were excised to free the upper lobe. Several pleural



**Figure 1** Histological photograph showing a germinal centre with surrounding mantle and an expanded marginal zone.

biopsy specimens were taken, including some from the mass like lesion. Histological examination showed a diffuse infiltrate of lymphoid cells underlying a layer of pleura. Residual germinal centres were identified within this material. The appearance of the infiltrate and immunotyping were identical to case 1, except that this low grade marginal zone pleural lymphoma was CD23 negative and CD79a positive. PCR analysis showed a monoclonal band. The patient was commenced on chemotherapy with chlorambucil and prednisolone and showed no lymphadenopathy or recurrence of the effusion at 14 months.

## DISCUSSION

Two types of primary pleural lymphomas have been described. The body cavity based lymphoma is seen in patients with HIV and presents with pleural, peritoneal, or pericardial effusions in the absence of an identifiable tumour mass. It is a high grade lymphoma with a B cell or null cell phenotype.

The second entity is the rare pyothorax associated pleural lymphoma. The association of extranodal lymphomas in a background of chronic inflammation is well established—for example, the association of *Helicobacter pylori* infection and gastric lymphoma. In a similar scenario, this primary pleural lymphoma is associated with a history of chronic pyothorax (2.2% of cases),<sup>3</sup> or as a result of chronic inflammation of the pleura due to a previous artificial pneumothorax to treat tuberculosis. It is thought that long standing pleural inflammation is an important factor in the development of these lymphomas. Epstein-Barr virus and inflammatory cytokine stimulation are also thought to play a role. Pyothorax associated pleural lymphomas tend to present as a mass lesion consisting of a high grade non-Hodgkin's lymphoma of B cell origin. Most cases have been described in Japan and Tazuko *et al* have experienced only six cases in 18 years.<sup>3</sup>

Primary pleural non-Hodgkin's lymphoma in an immunocompetent patient without a history of chronic pyothorax is extremely rare. To our knowledge, only two previous cases have been reported; both were high grade B cell non-Hodgkin's lymphomas.<sup>4 5</sup>

In our report both patients had a low grade marginal zone lymphoma of the pleura in the absence of a pyothorax. However, the previous exposure to asbestos and tuberculosis may have provided an important focus of inflammation. The history of asbestos exposure suggested mesothelioma as the

most likely diagnosis. The association between lymphoid malignancy and asbestos exposure has been documented in the literature. For example, Jacobson *et al*<sup>6</sup> reported 16 asbestos workers who developed non-Hodgkin's lymphomas. It has been postulated that the intense stimulation of B lymphocytes by asbestos and the decrease in the number of circulating T lymphocytes may lead to lymphoid/plasma cell hyperplasia.

Patient 2 was diagnosed with tuberculosis at the age of 18. He remained asymptomatic for 32 years with no evidence of a pyothorax, and then presented with a left sided effusion. However, the site of the primary tuberculosis is not known and therefore its role in the development of the subsequent lymphoma is unclear.

In conclusion, we have described two cases of non-pyothorax associated low grade non-Hodgkin's lymphoma, one with a background of exposure to asbestos and the other with a history of tuberculosis.

## Authors' affiliations

**H Ahmad, J Pawade**, Department of Pathology, Bristol Royal Infirmary, Bristol, UK

**S Falk**, Department of Oncology, Bristol Royal Infirmary, Bristol, UK

**J A Morgan, L Balacumaraswami**, Department of Thoracic Surgery, Bristol Royal Infirmary, Bristol, UK

Correspondence to: Dr H Ahmad, Okus Road, Swindon SN1 4JN, UK; hasinaa100@hotmail.com

Revised version received 20 May 2002

Accepted for publication 14 June 2002

## REFERENCES

- 1 **Elis A**, Blickstein D, Mulchanov I, *et al*. Pleural effusion in patients with non-Hodgkin's lymphoma: a case controlled study. *Cancer* 1998;**83**: 1607–11.
- 2 **Parnell AP**, Frew I. Case report: non-Hodgkin's lymphoma presenting as an encasing pleural mass. *Br J Radiol* 1995;**68**:926–7.
- 3 **Tazuko I**, Masashi F, Yukiko H, *et al*. Pyothorax-associated pleural lymphoma. *Cancer* 1994;**73**:738–44.
- 4 **Keung YIK**, Cobos E, Morgan D, *et al*. Non-pyothorax-associated primary pleural lymphoma with complex karyotypic abnormalities. *Leukemia and Lymphoma* 1996;**23**:621–4.
- 5 **Kanno M**, Nakamura S, Uotani C, *et al*. Primary pleural non-Hodgkin's lymphoma without chronic pyothorax. *Rinsho Ketsueki (Jpn J Clin Hematol)* 1999;**40**:678–84.
- 6 **Jacobson RJ**, Memoli D, Kagan E. Malignant lymphomas in asbestos workers: clinico-pathological features and concerns about bleomycin. *Hematol Rev Commun* 1990;**4**:217–27.