

Case reports

Anaemia in lung transplant patient caused by parvovirus B19

H H Kariyawasam, K M Gyi, M E Hodson, B J Cohen

Abstract

The case history is presented of a lung transplant patient who developed prolonged parvovirus B19 infection with severe transfusion dependent anaemia. The patient was treated with intravenous immunoglobulin after which the haemoglobin rose, together with a reticulocytosis. The patient then remained transfusion free and the virus cleared more than three months after the initial immunoglobulin treatment. The clinical and social implications for this group of patients are discussed.

(Thorax 2000;55:619–620)

Keywords: parvovirus B19; lung transplantation; immunoglobulin therapy

Case history

The patient had undergone lung transplantation for cystic fibrosis and was maintained on FK506, azathioprine, and prednisolone immunosuppression. In addition, she had undergone total lymphoid irradiation for obliterative bronchiolitis. The patient presented (day 1) with severe shortness of breath and dizziness. The haemoglobin level was 3.5 g/dl and she was normocytic with reticulocytopenia and a normal white cell and platelet count. Blood parameters were normal and a bone marrow aspirate confirmed red cell aplasia.

The serum on day 1 was positive for parvovirus B19 DNA by dot blot DNA hybridisation¹ and polymerase chain reaction (PCR).² There was no humoral response to the infection as evidenced by a negative IgM and IgG response. Parvovirus B19 IgM was tested

by radioimmunoassay³ and IgG by ELISA (Biotrin International, Dublin, Ireland or Denka Seiken, Tokyo, Japan).

Following a blood transfusion the haemoglobin level rose to 10 g/dl (day 3). It then started to fall with a sustained reticulocytopenia and 56 days after the initial presentation the haemoglobin level was 6.3 g/dl with a reticulocyte percentage of 0.1. The patient was again transfused, having required two transfusions on days 17 and 30 after the initial transfusion.

At day 23 after her presentation the patient still had a high viral load and had failed to mount an IgM antibody response. There was, however, an equivocal reaction for parvovirus B19 specific IgG which was probably due to the passive transfer of antibody during the course of blood transfusions.

The patient's haemoglobin again fell from 12.7 g/dl on day 62 to 9.5 g/dl on day 79 after the initial presentation and she was treated with intravenous Sandoglobulin in a total daily dose of 0.4 g/kg.⁴ However, because of chronic renal impairment secondary to the previous use of cyclosporin and FK506, we used only one quarter of the total dose on day 79, half the total dose on day 80, and three quarters of the total dose on day 81. The total dose of 0.4 g/kg was given only on day 82 after ensuring that renal function remained stable. The treatment was discontinued after six days because of deteriorating renal function. Serum taken before treatment showed a high viral load and equivocal IgG level. Parvovirus B19 IgM was positive, indicating that the patient was mounting an early response to the virus. An impressive reticulocytosis was seen on the second day of immunoglobulin therapy and a week later was 10.3% (fig 1).

Serum analysed after immunoglobulin therapy on day 84 was negative for parvovirus B19 by DNA dot blot hybridisation but remained PCR positive, indicating a persistent

Department of Cystic Fibrosis, Royal Brompton Hospital, London SW3 6NP, UK
H H Kariyawasam
K M Gyi
M E Hodson

Central Public Health Laboratory, Virus Reference Division, London NW9 5HT, UK
B J Cohen

Correspondence to:
Dr K M Gyi
email:
k.gyi@rbh.nthames.nhs.uk

Received 20 January 1999
Accepted for publication
14 September 1999

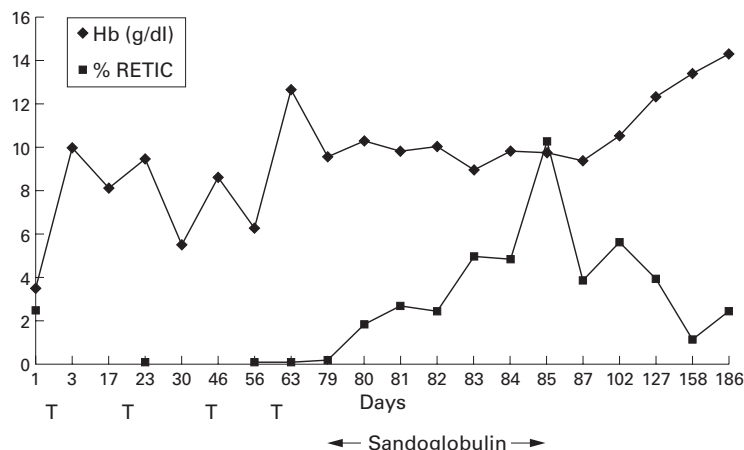


Figure 1 Duration of anaemia. Hb = haemoglobin; RETIC = reticulocytosis.

Table 1 Parvovirus B19 test results

Day	IgM	IgG	Dot blot	PCR
2	<1	0.176	+ve	+ve
23	<1	0.275	+ve	+ve
79	3.1	0.309	+ve	+ve
84	7.8	2.513	-ve	+ve
102	1.4	1.234	-ve	+ve
140	<1	1.316	-ve	+ve
192	<1	0.606	-ve	-ve

Sandoglobulin given on days 79, 80, 81, 82, 83, and 84.

IgM: <1 negative; >3 positive; 1–3 equivocal.

IgG: <0.80 negative; >1 positive; 0.8–1 equivocal.

viraemia but a low viral load. The IgM level was increased (table 1) and indicated an active immune response against the virus. The positive IgG at this stage, however, probably reflected passive transfer of antibody from the commercial immunoglobulin preparation.

The haemoglobin level was maintained at a value greater than 10 g/dl. The viral load remained low one month after treatment and, after a further three months, the haemoglobin level rose to 14 g/dl and the patient became PCR negative, indicating clearance of viraemia. The relatively lower levels of B19 IgG on days 140 and 192 represent a decline in the passive antibody received during treatment. B19 IgM became undetectable by day 140.

Discussion

This case emphasises the importance of including parvovirus B19 infection in the differential diagnosis of unexplained anaemia with reticulocytopenia in any patient following solid organ transplantation. It is a treatable cause of anaemia and minimises the use of any uncomfortable and unnecessary procedures for the patient.

It may be that the total lymphoid irradiation contributed to the prolonged course of the parvovirus B19 infection. Total lymphoid irradiation is known to be associated with the development of viral infections such as herpes simplex and cytomegalovirus.⁵

It is also important to prevent exposure of other people at risk of severe parvovirus B19 infection. Since 50% of the adult population lack antibodies and remain susceptible, contact with pregnant women and other immunosuppressed patients was avoided until the immu-

noglobulin therapy was completed and the dot blot DNA hybridisation was negative. There is evidence that treatment with immunoglobulin decreases viral shedding in respiratory secretions a million-fold so that infectivity is significantly lowered.⁶ This is therefore another indication for instigating immunoglobulin therapy in patients with prolonged B19 infection.

At present the patient remains well. Despite the clearance of viraemia, parvovirus B19 may remain in the bone marrow⁷ and thus has the potential to recur. This has serious implications for the patient should she be considered for retransplantation for her obliterative bronchiolitis in the future.

The authors thank Dr John Burman for carrying out the bone marrow aspiration, Dr Nay Win for his advice, and Mrs Jayshree Gandhi and Mr Stuart Beard of the PHLS Enteric and Respiratory Virus Laboratory for performing the parvovirus B19 tests.

- 1 Hicks KE, Beard S, Cohen BJ, et al. A simple and sensitive DNA hybridisation assay used for the routine diagnosis of human parvovirus B19 infection. *J Clin Microbiol* 1995;33:2473-5.
- 2 Clewley JP. PCR detection of parvovirus B19. In: Persing DH, Smith TF, Tenover FC, White TJ, eds. *Diagnostic molecular microbiology: principles and applications*. Washington, DC: American Society for Microbiology, 1993:367-73.
- 3 Cohen BJ. Detection of parvovirus B19-specific IgM by antibody capture radioimmunoassay. *J Virol Methods* 1997; 66:1-4.
- 4 Ramage JK, Hale A, Gane E, et al. Parvovirus B19 induced red cell aplasia treated with plasmapheresis and immunoglobulin. *Lancet* 1994;343:667-8.
- 5 Valentine VG, Robbins RC, Wehner JH, et al. Total lymphoid irradiation for refractory acute rejection in heart-lung and lung allografts. *Chest* 1996;109:1184-9.
- 6 Frickhofen N, Abkowitz JL, Safford M, et al. Persistent B19 parvovirus infection in patients infected with human immunodeficiency virus type 1 (HIV-1): a treatable cause of anaemia in AIDS. *Ann Intern Med* 1990;113:926-33.
- 7 Cassinoti P, Burtonboy G, Fopp M, et al. Evidence for persistence of human parvovirus B19 DNA in bone marrow. *J Med Virol* 1997;53:229-32.

Thorax 2000;55:620-622

Pneumothorax in adults with cystic fibrosis dependent on nasal intermittent positive pressure ventilation (NIPPV): a management dilemma

C S Haworth, M E Dodd, M Atkins, A A Woodcock, A K Webb

Abstract

The management of pneumothorax in three adult patients with cystic fibrosis dependent on nasal intermittent positive pressure ventilation is described.

(*Thorax* 2000;55:620-623)

Keywords: cystic fibrosis; nasal intermittent positive pressure ventilation (NIPPV); pneumothorax

Transplant listed patients with cystic fibrosis who develop hypercapnic hypoxic (type 2) respiratory failure can be kept alive until donor

organs become available with the introduction of nasal intermittent positive pressure ventilation (NIPPV).¹ We describe the management of three transplant listed cystic fibrosis patients who developed pneumothoraces while dependent on NIPPV.

Case reports

A 20 year old man awaiting double lung transplantation was established on NIPPV because of deterioration in his spirometric values and blood gas tensions. He was infected with *Burkholderia cepacia*, had a forced expiratory

Manchester Adult
Cystic Fibrosis Unit,
South Manchester
University Hospitals
NHS Trust,
Wythenshawe
Hospital, Southmoor
Road, Manchester
M23 9LT, UK
C S Haworth
M E Dodd
M Atkins
A A Woodcock
A K Webb

Correspondence to:
Dr A K Webb
email:
the5webbs@hotmail.com

Received 19 April 1999
Returned to authors
7 June 1999
Revised manuscript received
5 August 1999
Accepted for publication
2 September 1999

volume in one second (FEV₁) of 0.6 l, forced vital capacity (FVC) of 1.2 l, required continuous intravenous antibiotic therapy and overnight gastrostomy feeding. Capillary blood gas analysis while breathing room air revealed oxygen partial pressure (Po₂) of 51 mm Hg (6.8 kPa) and carbon dioxide partial pressure (Pco₂) of 43 mm Hg (5.7 kPa). On 24% oxygen, capillary blood gas analysis showed a Po₂ of 59 mm Hg (7.9 kPa) and a Pco₂ of 48 mm Hg (6.4 kPa). He was commenced on NIPPV using a pressure cycled ventilator (NIPPV, Friday Medical, London, UK) with the pressure set at 24 mm H₂O and the inspiratory and expiratory times matched to the patient's breathing pattern (0.9 and 2.0 seconds, respectively). The pressure was later increased to 28 mm H₂O as he developed CO₂ retention. Once established on the ventilator for 8–12 hours at night with 2 l/min supplemental oxygen, early morning capillary blood gas tensions were Po₂ 83.8 mm Hg (11.2 kPa) and Pco₂ 44.7 mm Hg (5.6 kPa).

Four months after commencing NIPPV he developed a small right pneumothorax (less than 10%) following the insertion of a totally implantable venous access device. The patient was asymptomatic but, as it was thought that NIPPV could increase the size of the pneumothorax, ventilatory support was withdrawn. His gastrostomy feeding was also discontinued and he was oxygenated overnight using a 24% Venturi mask. The following morning capillary blood gas analysis showed a Po₂ of 71 mm Hg (9.5 kPa) and Pco₂ of 51.2 mm Hg (6.8 kPa). Overnight feeding was reintroduced at 50% of the usual volume (500 ml). NIPPV continued to be withheld and five days after the first pneumothorax a chest radiograph showed a new left sided pneumothorax (less than 10%). The aetiology of the second pneumothorax was unclear and fortunately the patient remained in a stable condition. Both pneumothoraces slowly decreased in size and eight days after the initial pneumothorax capillary blood gas analysis on 24% oxygen showed a Po₂ of 62 mm Hg (8.3 kPa) and a Pco₂ of 44.6 mm Hg (5.9 kPa). At this time his chest radiograph was deteriorating and he was experiencing difficulty in expectorating sputum despite adequate hydration, intravenous antibiotic therapy, and the concomitant use of DNase. NIPPV was therefore recommenced (at a reduced pressure of 18 cm H₂O) to facilitate sputum expectoration and to improve his blood gas tensions. After two hours a chest radiograph revealed that the pneumothoraces had not increased in size and his capillary blood gas tensions had improved (Po₂ 89 mm Hg (11.8 kPa), Pco₂ 43.4 mm Hg (5.8 kPa)). He continued to receive NIPPV overnight and the next morning he felt better and was more mobile. However, at midday he developed surgical emphysema on his chest wall. A chest radiograph showed that the pneumothoraces had not increased in size but the NIPPV was further withheld. The following day his surgical emphysema had resolved and NIPPV and full overnight feeding were recommenced without further problems. He was discharged home approximately one

week later and capillary blood gas analysis at discharge using NIPPV with 2 l/min supplemental oxygen gave a Po₂ of 78 mm Hg (10.4 kPa) and Pco₂ of 42 mm Hg (5.6 kPa). Three months later he received a double lung transplant.

Two further transplant listed patients with cystic fibrosis dependent on NIPPV attending our unit have developed pneumothoraces. A 28 year old man with an FEV₁ of 0.8 l who had been established on NIPPV for 22 months developed a large (50%) left sided pneumothorax whilst using the ventilator. His NIPPV pressure was set at 19 mm H₂O. The pneumothorax was not associated with a respiratory exacerbation, but he was treated with intravenous antibiotic therapy and intravenous aminophylline to aid sputum expectoration while his NIPPV was discontinued. Capillary blood gas analysis while breathing room air gave a Po₂ of 53 mm Hg (7.1 kPa) and a Pco₂ of 41 mm Hg (5.5 kPa). The pneumothorax was drained using an intercostal tube and the lung re-expanded quickly, following which capillary blood analysis on 24% oxygen gave a Po₂ of 61 mm Hg (8.1 kPa) and a Pco₂ of 44.9 mm Hg (6.0 kPa). The patient maintained adequate blood gases for the duration of his admission and only required further NIPPV one month after his pneumothorax. He remains well, but NIPPV dependent, 27 months following his pneumothorax.

The third NIPPV dependent cystic fibrosis patient to develop a pneumothorax attended clinic with neck discomfort. She was not breathless. A chest radiograph demonstrated surgical emphysema in the neck and air in the pericardial space, but no evidence of a pneumothorax. NIPPV was withheld and she was maintained on 24% oxygen overnight. As she did not deteriorate it was decided to withhold NIPPV until the surgical emphysema had resolved, but two days after presentation she received a double lung transplant.

Discussion

At the Manchester Adult Cystic Fibrosis Unit we have treated 52 of 334 patients (16%) for a pneumothorax over the last 17 years and commenced 23 patients on NIPPV. Only three of our patients have developed a pneumothorax whilst dependent on NIPPV and one of these was iatrogenic. It is surprising that the reporting of pneumothoraces either as a consequence or coincident with NIPPV is not more common. However, our figures and those from another large adult cystic fibrosis unit indicate that this is a rare event.² In other respiratory diseases the occurrence of a pneumothorax while patients are being treated with NIPPV is also rare. This probably reflects that, in conditions such as kyphoscoliosis and the neuromuscular disorders, the lungs are relatively normal. In contrast, cystic fibrosis is characterised by progressive pulmonary infection and apical subpleural bronchiectatic cysts that often rupture. In the future the incidence of NIPPV associated pneumothorax may increase as NIPPV is used more widely in patients with cystic fibrosis.

The ventilator described in these cases is pressure preset. The inspiratory and expiratory times are individualised to allow sufficient expiratory time to avoid auto-positive end expiratory pressure and breath stacking.³ The pressure is then set to improve alveolar ventilation. It is important to balance adequate ventilation with peak inspiratory pressure, especially in those patients with low pulmonary compliance, to reduce the risk of barotrauma. Permissive hypercapnia may be acceptable in this situation as long as the patient remains asymptomatic. Pressure support ventilation may be preferable in patients with subpleural cysts who are at risk of barotrauma, as the peak airway pressure (including the swings associated with coughing on the ventilator) and the mean airway pressure may be lower. Conversely, it may be necessary to produce higher pressures in acutely sick patients. Some cystic fibrosis units use machines that generate higher pressures than the ventilator described in this paper. It is important to be aware of the maximum pressures generated and to balance the risk of barotrauma with patient benefit. We are not aware of any reports describing the relative risks of volume and pressure preset nasal ventilators in cystic fibrosis.

The development of a pneumothorax in a patient with cystic fibrosis receiving NIPPV can be a challenging clinical situation. As in the first case described here, pneumothorax may cause an abrupt deterioration in respiratory status and at the same time necessitate withdrawal of NIPPV. However, as demonstrated by the second case, other patients who are not in a respiratory exacerbation may remain relatively stable when NIPPV is withdrawn, reflecting that their "physiology" has been reset by NIPPV. If NIPPV is withheld or the inflation pressure is reduced and the P_{CO_2} rises, hypercapnia is acceptable in the short term as long as the patient remains asymptomatic. Alternatively, in a patient who requires continuing NIPPV following a pneumothorax, it can be delivered safely providing the pneumothorax is being drained through a patient intercostal tube.

An additional perceived benefit of NIPPV in patients with cystic fibrosis is that it may aid

sputum expectoration. However, when NIPPV is withdrawn following pneumothorax without chest intubation, sputum clearance techniques are modified to avoid increases in intrathoracic pressure which may result in sputum trapping. Our experience shows that good hydration, intravenous aminophylline, intravenous antibiotic therapy, DNase, and adequate analgesia may be of benefit. The reintroduction of NIPPV can be associated with further air leaks and the length of time that a patient refrains from NIPPV following a pneumothorax is dictated by clinical circumstance. Reducing ventilator pressures may facilitate the reintroduction of NIPPV. However, it is important to appreciate that the pressure delivered by a non-invasive ventilator is measured from within the mask and is not necessarily the pressure achieved in the trachea and alveoli, as there is usually a significant fall in pressure across the nose and upper airway. This may be especially true in cystic fibrosis patients with rhinitis and nasal polyps. Overnight feeding can precipitate type 2 respiratory failure in patients with cystic fibrosis who have severe lung disease due to splinting of the diaphragm and increased CO_2 production. In NIPPV dependent cystic fibrosis patients with a pneumothorax it may therefore be prudent to discontinue feeding until NIPPV can be reinstated.

This brief report highlights the dilemma of managing the rare complication of pneumothorax in NIPPV dependent adult patients with cystic fibrosis. Clearly, each patient requires meticulously supervised and individualised management with the risks of mechanical ventilation being balanced against the potential benefits.

- 1 Hodson ME, Madden BP, Steven MH, et al. Non-invasive mechanical ventilation for cystic fibrosis patients: a potential bridge for transplantation. *Eur Respir J* 1991;4:524-7.
- 2 Hill AT, Edenborough FP, Cayton RM, et al. Long-term nasal intermittent positive pressure ventilation in patients with cystic fibrosis and hypercapnic respiratory failure (1991-1996). *Respir Med* 1998;92:523-6.
- 3 Shneerson JM. Techniques in mechanical ventilation: principles and practice. *Thorax* 1996;51:756-61.