

Case reports

Disseminated *Penicillium marneffei* infection presenting as a right upper lobe mass in an HIV positive patient

Helen McShane, Christoph M Tang, Christopher P Conlon

Abstract

A 35 year old HIV positive patient from Hong Kong presented with a fever, cough and a skin rash in association with a lung mass, all of which were due to disseminated *Penicillium marneffei* infection. He made a good response to antifungal therapy. The lung mass is a previously undescribed pulmonary manifestation of disseminated *Penicillium marneffei* infection. Infections with this fungus should be suspected in any patient with HIV and respiratory symptoms who has visited southeast Asia.

(Thorax 1998;53:905-906)

Keywords: *Penicillium marneffei*; southeast Asia

Penicillium marneffei is a dimorphic fungus endemic in southeast Asia which recently has become an important opportunistic infection in HIV positive individuals with very low CD4 lymphocyte counts in North Thailand.¹ Some of the features of disseminated *P marneffei* infection such as fever and cough are non-specific and common to many opportunistic HIV infections, but cutaneous lesions can help to distinguish this infection from others. Pulmonary involvement is not uncommon but is usually subclinical. We describe the case of an HIV positive patient who presented with a rash and a right upper lobe mass which was due to *P marneffei* infection, a previously undescribed pulmonary manifestation of this fungus.

Case history

A 35 year old Chinese man presented in 1995 with a three month history of increasing shortness of breath, productive cough, and fever in association with skin lesions on his limbs and trunk. He was born in Hong Kong and moved to England at the age of 12 years. He had visited Hong Kong and southern China for one month in 1992 and for two months in 1993 but had not otherwise left the United Kingdom. He had been an intravenous drug user in the past

and was first diagnosed as being HIV positive in 1992. He had been well until this presentation except for an episode of *Pneumocystis carinii* pneumonia (PCP) in 1993, his only AIDS defining illness to date. He was taking dapsone for PCP prophylaxis and smoked 10 cigarettes a day.

On examination he was febrile (38.4°C) and had generalised lymphadenopathy. There were several well circumscribed dark red papules on his skin which were crusted at the edges, characteristic of lesions seen in *P marneffei* infection (fig 1). Examination of his respiratory, cardiovascular, and gastrointestinal systems was unremarkable. Oxygen saturation on pulse oximetry was 88% on air.

Initial investigations gave the following results: haemoglobin, 10.8 g/dl; white cell count, $4.5 \times 10^9/l$ (lymphocytes 0.73, neutrophils 3.19, monocytes 0.23, eosinophils 0.36); platelets, $109 \times 10^9/l$; erythrocyte sedimentation rate, 75 mm/h; C reactive protein, 16 mg/l; CD4 lymphocyte count, $0.02 \times 10^9/l$ (normal $0.4-1.0 \times 10^9/l$). Routine biochemistry was normal. His chest radiograph showed a dense opacity in the right upper lobe

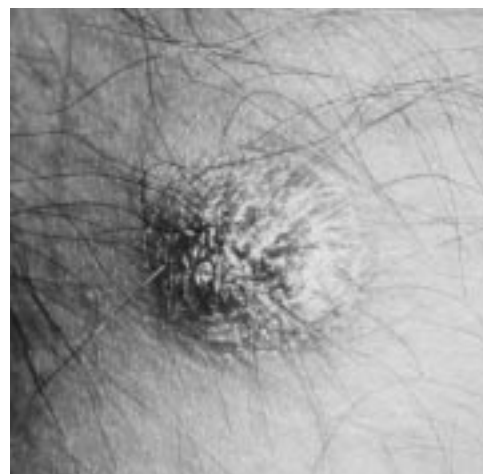


Figure 1 Typical skin lesion on forearm.

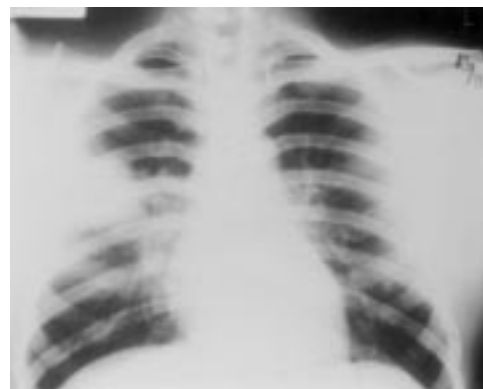


Figure 2 Posteroanterior chest radiograph showing right upper lobe mass due to *Penicillium marneffei*.

Infectious Diseases Unit, Nuffield Department of Medicine, Oxford Radcliffe Hospital NHS Trust, Headley Way, Oxford OX3 9DU, UK

H McShane
C M Tang
C P Conlon

Correspondence to:
Dr C Conlon.

Received 7 April 1997
Returned to authors
13 May 1997
Revised version received
14 July 1997
Accepted for publication
30 July 1997

with diffuse generalised bilateral air space disease (fig 2). A CT scan of the chest showed multiple medium sized nodules throughout both lung fields and a segmental soft tissue mass in the right upper lobe which abutted the pleural surface and measured 5 × 7.5 cm. Sputum microscopy and culture were negative for bacteria, mycobacteria, and fungi. Fiberoptic bronchoscopy revealed a tumour-like lesion on the posterior tracheal wall and a distorted right middle lobe with no endobronchial lesion visible. Bronchial lavage fluid was negative on microscopy and culture but biopsy specimens of the tracheal lesion, skin, and right upper lobe lesion had an identical histological appearance showing a mononuclear cell infiltrate with fungal yeast forms within macrophages. *P marneffei* was isolated from all biopsy samples. Blood cultures were negative.

The patient was started on intravenous amphotericin but, because of side effects, his treatment was changed after 48 hours to high dose oral itraconazole, 200 mg twice daily. His skin lesions began to regress and his chest symptoms resolved within a week of starting treatment. Six months later his skin was clear and the chest radiograph was normal except for a small residual right upper lobe opacity. He remained well on itraconazole until developing cytomegalovirus (CMV) retinitis 18 months later, subsequently dying of CMV encephalopathy.

Discussion

In endemic areas disseminated *P marneffei* infection is recognised as an increasing problem in patients with HIV infection. It is now the third most common opportunistic infection in the HIV population in northern Thailand after

extrapulmonary tuberculosis and cryptococcal meningitis.² An important clue to the diagnosis is a characteristic papular skin rash, often with central umbilication or necrosis, resembling giant molluscum contagiosum. In a recent series of 86 patients co-infected with HIV and *P marneffei* 71% had these characteristic skin lesions.² Pulmonary involvement has been described as being diffuse or focal with either an alveolar or reticulonodular pattern of involvement. A single case of a pleural effusion due to *P marneffei* has also been reported. Ours is the first description of a solid lung mass and an endotracheal lesion in this condition.

The patient was clinically suspected of having disseminated *P marneffei* infection on the basis of his skin lesions and travel history, but the extent of his pulmonary disease prompted a search for other pathogens such as *Mycobacterium tuberculosis* or *Cryptococcus neoformans*. Extensive investigation revealed *P marneffei* as the sole cause of his presenting symptoms and signs. Infection with this fungus should be suspected in HIV positive patients presenting with fever and a papular rash who have visited southeast Asia.³ We have shown that patients may also present with a mass lesion in the lung and that prompt recognition and institution of treatment can lead to an almost complete resolution of the disease.

- 1 Supparatpinyo K, Chiewchanvit S, Hirunsri P, et al. *Penicillium marneffei* infection in patients infected with human immunodeficiency virus. *Clin Infect Dis* 1992;14:871-4.
- 2 Supparatpinyo K, Khamwan C, Baosoung V, et al. Disseminated *Penicillium marneffei* infection in Southeast Asia. *Lancet* 1994;344:110-3.
- 3 Duong TA. Infection due to *Penicillium marneffei*, an emerging pathogen: review of 155 reported cases. *Clin Infect Dis* 1996;23:125-30.

Thorax 1998;53:906-908

Flitting radiographic shadows: an unusual presentation of cancer in the lungs

W M Edmondstone

Abstract

Tumour involvement of pulmonary blood vessels occurs frequently in advanced lung cancer and occasionally may cause pulmonary infarction. A case is reported of diffuse obstruction of pulmonary arteries by cancer in which no primary tumour was found, and which presented as flitting radiographic opacities due to pulmonary infarction.

(*Thorax* 1998;53:906-908)

Keywords: pulmonary infarcts; pulmonary arterial tumour embolism; cancer

Radiographic opacities which "flit" around the lungs are characteristic of a number of conditions including allergic bronchopulmonary aspergillosis and other pulmonary eosinophilic syndromes, and cryptogenic organising pneumonia. They may follow aspiration from the upper airways or oesophagus, or occur in acute infective exacerbations of bronchiectasis or chronic bronchitis. Recurrent pulmonary emboli may cause infarcts which result in transient consolidation. Malignant disease in the lungs usually causes progressive enlargement of one or more radiographic opacities and is not associated with flitting shadows.

A case is reported where infarcts due to obstruction of pulmonary arteries by tumour occurred in the absence of an obvious primary cancer and resulted in flitting radiographic shadows.

Case report

In 1980 a 50 year old man underwent radical radiotherapy followed by a total laryngectomy for squamous cell carcinoma of the larynx. Subsequently there was no evidence of tumour

Royal Hospital Haslar,
Gosport, Hampshire
PO12 2AA, UK
W M Edmondstone

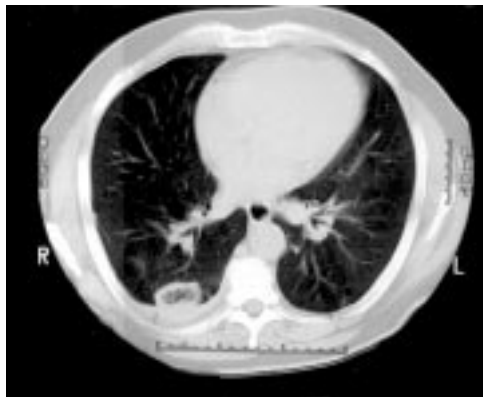
Correspondence to:
Dr W M Edmondstone.

Received 27 May 1997
Returned to authors
12 September 1997
Revised version received
29 September 1997
Accepted for publication
23 October 1997

Figure 1 Chest CT scan showing peripheral consolidation at the apex of the right lung.

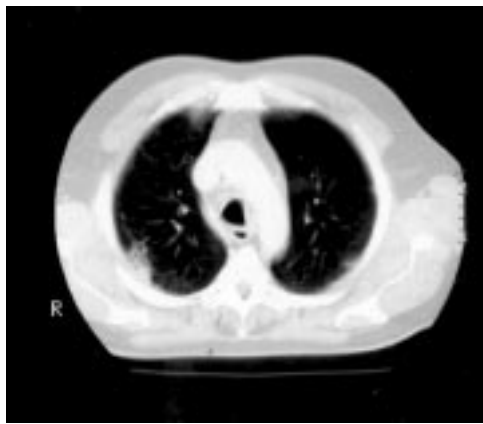

Figure 2 Chest CT scan four months later showing a new area of consolidation with cavitation in the right lower lobe. Both the opacities proved to be pulmonary infarcts secondary to obstruction of pulmonary arteries by squamous cell carcinoma.



recurrence and he remained well until 1996 when, aged 66, he developed right upper chest pain, breathlessness on exertion, dry cough, malaise, and weight loss. He had been a heavy smoker until his laryngectomy and he had been exposed to asbestos. He was referred after several courses of antibiotics had failed to clear an area of consolidation in the periphery of the right lung apex.

Apart from his tracheostomy, examination was unremarkable. His erythrocyte sedimentation rate was slightly elevated at 24 mm/h but otherwise blood tests and the electrocardiogram were normal or negative. A fiberoptic bronchoscopic examination was normal and washings and brushings from the right upper lobe revealed no malignant cells. A computed tomographic (CT) scan (fig 1) confirmed a peripheral opacity at the apex of the right lung with some thickening of the overlying pleura. A CT guided percutaneous biopsy specimen was non-diagnostic, showing some fibrous thickening of the pleura only.

During the next four months his chest radiograph improved and the right apical opacity gradually resolved. He continued to feel unwell and to lose weight, however, and his breathlessness increased. Four months after his original presentation his chest radiograph showed almost complete resolution of the apical lesion, but a new opacity had developed in the right lower lobe. A further CT scan (fig 2) showed a cavitating lesion in the periphery of the posterobasal right lower lobe. Blood tests including antineutrophil cytoplasmic antibodies were negative, bronchoscopy was again nor-

mal, and a repeat CT guided needle biopsy specimen revealed only necrotic debris.

A ventilation-perfusion lung scan showed matching defects in the right upper and lower lobes but multiple mismatched defects elsewhere, indicating a high probability of pulmonary emboli. While being anticoagulated he developed a right hemiplegia which was shown by CT scanning to be due to a cerebral infarct. He subsequently deteriorated rapidly and died.

The necropsy showed evidence of a recent infarct in the left cerebral hemisphere. In the chest there were bilateral pleural plaques, both lungs were congested and oedematous, and there were two necrotic areas in the right upper and right lower lobes. Microscopy showed these to be infarcts which were undergoing organisation. There was no evidence of macroscopic tumour in the chest or elsewhere, but microscopic examination of sections of the right upper and lower lobes and the left upper lobe showed extensive spread of poorly differentiated squamous cell carcinoma within pulmonary arteries and fibrous septa. Although no primary tumour was found there was infiltration of the left hilar lymph nodes and an area of severely dysplastic squamous epithelium in a section of the right main bronchus.

Discussion

Many cancers induce a hypercoagulable state and thrombotic pulmonary embolism is the second commonest cause of death in patients with solid tumours.¹ Although it is rarely diagnosed in life, necropsy studies have demonstrated that pulmonary arterial tumour embolism occurs in 8–20% of advanced cancers, being particularly associated with carcinoma of the lung, breast, liver, pancreas, and gastrointestinal tract.^{2–4} Occlusion of pulmonary arteries by tumour may be compounded by thrombosis in situ and may lead to infarction. Without a lung biopsy the diagnosis, and its differentiation from thrombotic pulmonary embolism, may be difficult to make.⁴ Whether pulmonary infarction complicates arterial tumour embolism more frequently than thrombotic embolism remains undecided.^{2–4} In a series of 100 pneumonectomies for lung cancer there were 10 pulmonary infarcts of which two were due to tumour infiltration and thrombosis of pulmonary vessels, three resulted from vascular compression by tumour, and in the remainder no obvious cause was found.⁵

In this case the diagnosis of primary pulmonary or pleural malignancy was suspected initially but not supported by investigations. The appearance of a second opacity in the right lower lobe raised the possibility of aspiration of infected material from the patient's tracheostomy. Recurrent pulmonary infarcts were also thought to be likely. This diagnosis was supported by the ventilation-perfusion lung scan which showed multiple mismatches, but these were subsequently found to be due to carcinomatous rather than thrombotic occlusion of pulmonary vessels. The possibility of this diagnosis was not considered, especially as

there appeared to be no evidence of a primary tumour. Whether the extensive infiltration by squamous cell carcinoma was due to late metastasis from the patient's previous laryngeal tumour, or whether it was due to a covert lung primary is uncertain.

Tumour involvement of pulmonary vessels is not uncommon. This diagnosis should be considered in patients with a history of previous malignancy who present with fitting lung shadows.

- 1 Ambrus JL, Ambrus CM, Mink IB, *et al.* Causes of death in cancer patients. *J Med* 1975;6:61-71.
- 2 Soares FA, Landell GA, de Oliveira JA. A prospective study of the morphological aspects of tumour involvement of the pulmonary vessels. *Pathology* 1992;24:150-4
- 3 Soares FA, Pinto AP, Landell GA, *et al.* Pulmonary tumour embolism to arterial vessels and carcinomatous lymphangitis. A comparative clinical study. *Arch Pathol Lab Med* 1993;117:827-31.
- 4 Goldharber SZ, Dricker E, Buring JE, *et al.* Clinical suspicion of autopsy-proven thrombotic and tumour embolism in cancer patients. *Am Heart J* 1987;114:1432-5.
- 5 Hanbury WJ, Cureton RJ, Simon G. Pulmonary infarcts associated with bronchogenic carcinoma. *Thorax* 1954;9:304-12.

Thorax 1998;53:908

NOTICES

Practical Pulmonary Pathology

This practical "hands on" course to be held at Imperial College School of Medicine, London on 14 and 15 April 1999 is separate from but complements an IAP course on pulmonary pathology that will be held in Swansea on the following two days (16 and 17 April). Most of the course will be devoted to personal examination at the microscope of a unique collection of pulmonary pathology cases, mainly other people's problems that have been referred in consultation. Lectures will be limited to three each day and the topics for these have been chosen to complement those given in Swansea. Guest lecturers include T Colby (Mayo Clinic), J M Kay (McMaster University) and W Travis (Armed Forces Institute of Pathology). Application forms are available from Professor B Corrin, Royal Brompton Hospital, London SW3 6NP. Fax: +44 171 351 8293. e-mail: b.corrin@ic.ac.uk (with copy to l.oscar@ic.ac.uk).

Asthma Therapy: from Basic to Clinical Research

Prous Science Publishers is organising a telesymposium on asthma therapy as part of an Internet/Intranet telesymposium from 15 January to 1 March 1999 (print communications available). Abstracts are now being accepted. Contact: Sara Skinner, Project Manager, Telesymposia Proceedings, Prous Science, PO Box 540, 08080 Barcelona, Spain. Tel: +34 93 459 2220. Fax +34 93 458 1535. e-mail: ts@prous.es. Website address <http://www.prous.com/ts>

International Society for Aerosols in Medicine (ISAM)

The 12th International Congress of the International Society for Aerosols in Medicine (ISAM) will be held on 12-16 June 1999 in Vienna, Austria. For further information contact the Vienna Academy of Postgraduate Medical Education and Research, Alser Strasse 4, A-1090 Vienna, Austria. Telephone

+43 1 405 13 8322. Fax +43 1 405 13 8323. e-mail: medacad@via.at

BOOK REVIEWS

Principles and Practice of Intensive Care Monitoring. Tobin Martin J. (Pp 1525, 841 illustrations). USA: McGraw-Hill Inc, 1998. ISBN 0 07 065094 2.

The preface to this text, which forms the companion volume to *Principles and Practice of Mechanical Ventilation*, declares its intent to provide a comprehensive and authoritative compendium of knowledge on intensive care monitoring. Without doubt Martin Tobin has succeeded in this task. It is indeed a massive tome containing over 1500 pages subdivided into 87 chapters, contributed by 129 authors, and covers practically every conceivable aspect of monitoring in the intensive care environment.

The book is generally very well written and, given the number of authors, many of whom are of international renown, shows a commendable level of editorial control. The work is divided by organ system into eight major sections. Individual chapters follow a uniform layout with summaries and are written with an easily readable style, giving the entire work a familiar and comfortable feel. The chapters are indeed comprehensive, ranging from historical review and basic science through practical aspects and troubleshooting to the state of the art. Tables, graphs, and illustrations are used extensively and to good effect, although the quality of reproduction is inconsistent. References are comprehensive, relevant, and up to date.

The weaknesses in the book relate paradoxically to the quest for comprehensiveness and to the genuine difficulty of producing a truly international textbook. The seven chapters devoted to pulmonary artery catheters are excessive, while those concerning more esoteric subjects will be of interest to a minority of readers. Delivery and monitoring of inhaled nitric oxide therapy should probably merit more than six lines. The latter sections of the book dealing with legal issues, standards, and the FDA are unashamedly American and, whilst fascinating, lose immediacy when crossing the Atlantic.

In summary this is an extremely well written text on intensive care that is worth a place on the reference section of any ICU bookshelf. It provides an excellent reference text for trainees new to the specialty and a "dip in

and read" book for those with greater experience. I thoroughly enjoyed it.

The Pediatric Lung. Wilmott RW. (Pp 331; S Fr 228.00). Switzerland: Birkhäuser Verlag, 1997. ISBN 3 7643 5703 7.

The field of paediatric respiratory medicine is changing rapidly and a textbook like this provides a useful update on advances in the field. The series deals with respiratory pharmacology and pharmacotherapy and the editor has chosen not to concentrate on the management of one chronic illness but to deal with many therapeutic interventions in acute and chronic respiratory illness in children. As one would expect, there is a strong emphasis on cystic fibrosis (mucoactive agents, aerosol therapies, gene therapy, and pharmacological strategies to tackle the basic defect in cystic fibrosis). Asthma management is extensively covered (aerosol delivery, corticosteroids, acute severe asthma, and a review of new therapies). The book will undoubtedly be useful to the respiratory paediatrician, but there are chapters which will appeal to the paediatric intensivist or neonatologist (management of viral pneumonia, surfactant, and nitric oxide).

The topics chosen for each chapter are generally appropriate, though one might question whether an entire chapter should be given over to nedocromil sodium. The coverage of "hot topics" in cystic fibrosis and asthma is particularly good. The format of this book leads to some repetition—for example, amiloride and DNase therapy are both dealt with more than once. Some of the sections dealing with basic science are over referenced and may be inaccessible to many clinicians.

The chapter format is the traditional "expert review". Some reference is made to meta-analysis but there is little to guide the reader to the many important systematic reviews in the field (such as antenatal steroids and hyaline membrane disease). In most cases the authors' evident enthusiasm for their subject is tempered by an awareness that assessment of many new therapies is incomplete. In the chapter on the use of nitric oxide we are told that "... not one controlled trial of inhaled NO therapy has yet shown an improvement in clinical outcome ...". Since this book was published, one such trial has been completed (*N Engl J Med* 1997;336:597-604) and has shown a reduction in the percentage of infants requiring extracorporeal membrane oxygenation (ECMO) from 64% to 46%.

At 228 Swiss francs this book is not cheap, but it will cost you less than attending several international conferences to get the same information.