

Occasional review

“Ultimate activation” of eosinophils in vivo: lysis and release of clusters of free eosinophil granules (Cfegs)

Carl G A Persson, Jonas S Erjefält

During the last decade in vitro data have accumulated showing cytokine mediated inhibition of the programmed eosinophil death called apoptosis.¹ If valid to eosinophilic diseases, this action would increase the dwell time of eosinophils in the target tissue where they could repeatedly release fractions of their potent granular mediators.² Underscoring a potential importance of these mechanisms, the pharmacology of steroids includes both anti-release effects and pro-apoptotic actions, as determined in eosinophil test systems ex vivo.³ Although its role in vivo has yet to be established, eosinophil apoptosis is now at the cutting edge of experimental and conceptual research activities.^{1,4,5} In contrast, the non-apoptotic death or lysis of eosinophils is poorly recognised, not to say completely ignored. This imbalance in scientific interest is remarkable, particularly in consideration of evidence indicating eosinophil lysis and its immediate result – clusters of free extracellular eosinophil granules (Cfegs) in the target tissues of several common diseases.

This review highlights old and recent observations on Cfegs and focuses on their occurrence in the respiratory tract. Regrettably, we cannot provide the usual review mix of molecular and in vitro cell aspects with arrows linking biology data with clinical features of the airway diseases, nor do we present any scheme of reductive mechanisms involved in the present “cell activation” process. Also, this may not be a proper time to discuss in any detail the balance of roles in inflammation, disease, defence, and repair of the “ultimately activated” eosinophils. This brief overview is meant rather as a reminder that Cfegs do exist and that they should probably no longer be ignored. Despite all these shortcomings, and notwithstanding the fact that eosinophil lysis and generation of Cfegs have no place in current scientific literature and discussions, we endeavour to suggest that these events may, indeed, be a major modus operandi of eosinophils in vivo.

Eosinophil lysis and Cfegs: seeing is not always believing

Non-apoptotic death (“necrosis”, lysis, accidental death) of eosinophils and the gen-

eration of clusters of free eosinophil granules have repeatedly been depicted by transmission electron microscopy.^{2,6–10} The micrographs even suggest the possibility that lysis of eosinophils, and an intriguing distribution of free eosinophil granules, may be a major feature of many eosinophilic diseases including bullous pemphigoid,¹¹ atopic dermatitis,¹² eosinophilic pneumonia,¹³ allergic rhinitis,¹⁴ nasal polyposis,¹⁴ and asthma.^{6–10,14} Yet, this phenomenon is disregarded in discussions on the mechanisms of eosinophils in inflammation and allergy.^{1,2,15–18}

This manifest disinterest may reflect a combination of circumstances. Authors may rightly be cautious in their interpretation of transmission electron microscopy data due to the possibility that artefacts may have been inflicted both at the taking of biopsy specimens and at the sectioning of tissue samples. The fact that only small, potentially non-representative, tissue areas have been examined may also contribute to a lack of interest or disbelief in this phenomenon. In addition, free eosinophil granules in the airways have not previously been made evident by experimental demonstrations of when and how they are induced. Fourthly, the non-apoptotic death of eosinophils and the occurrence of free extracellular granules in vivo are, and have been, outside the acknowledged in vitro research paradigms in this field. The last mentioned point gains particular weight by modern requirements on medical research which tend to favour studies of molecular mechanisms in isolated cell systems at the expense of the exploratory research that observes and assesses basic in vivo phenomena.¹⁹

Acute generation of Cfegs in vivo in the airway mucosa

The tracheal mucosa of guinea pigs is rich in eosinophils²⁰ that reside in great numbers at the epithelial basement membrane.^{21,22} This particular homing of airway eosinophils coincides with epithelial expression of eotaxin²³ which is a selective chemoattractant originally discovered in guinea pig lungs.²⁴ The mucosal eosinophilia makes the normal or sensitised guinea pig large airway well suited for exploring which airway provocations may acutely activate

Department of Clinical Pharmacology, University Hospital of Lund, Department of Physiology and Neuroscience, University of Lund and Department of Pharmacology, Astra Draco AB, Lund, Sweden
C G A Persson
J S Erjefält

Correspondence to:
Dr C Persson, Department of Clinical Pharmacology, University Hospital, S-221 85 Lund, Sweden.

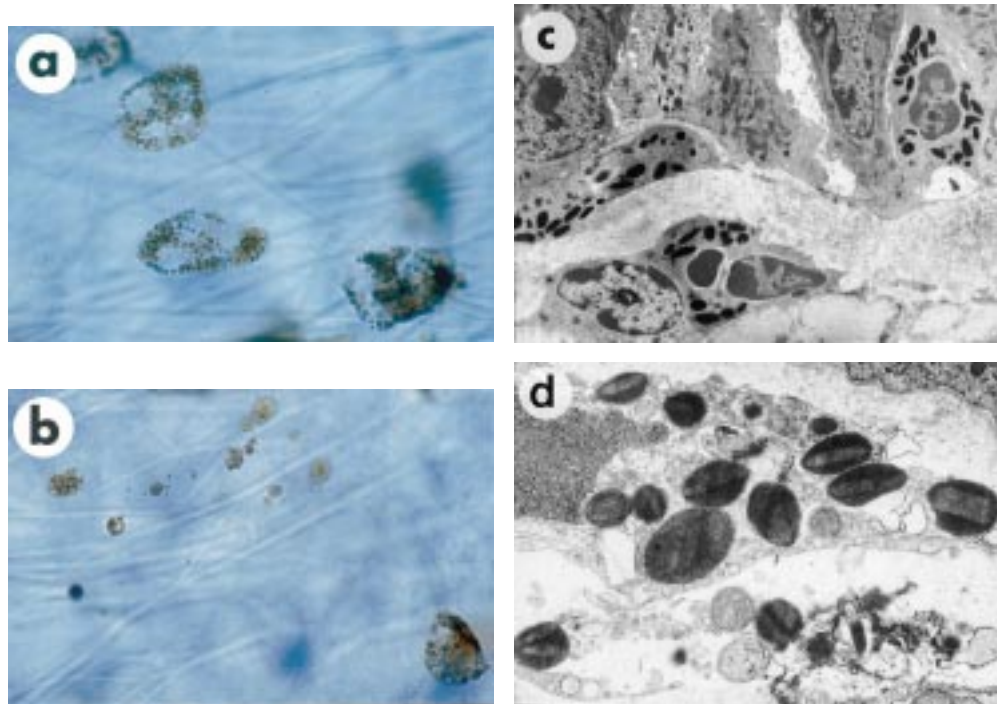


Figure 1 Bright field microscopy of whole mount preparation of guinea pig trachea with eosinophil granules visualised by histochemical staining of cyanide resistant eosinophil peroxidase. The substrate solution penetrates well into the whole tissue specimen, thus allowing deep tissue examination of the eosinophils. By changing the level of focus the localisation of (a) the intact eosinophils and (b) the Cfegs is determined. In both (a) and (b) the focus is at the level of the epithelial basement membrane. Further details are revealed by transmission electron microscopy showing (c) intact eosinophils in airway mucosa and (d) Cfegs together with an eosinophil cell displaying signs of membrane discontinuity and chromatinolysis.

mucosal eosinophils *in vivo*. The responses to provocations such as epithelial removal and exposure to allergen (in sensitised animals) include a prompt movement of the leucocytes from a basal to an apical position in the epithelium. However, other much more dramatic events also take place. Thus, within an hour after either provocation large numbers of eosinophils have been lysed, producing Cfegs in the mucosal tissue.^{21,22} We do not know whether generation of Cfegs may be grouped together with lysis mechanisms traditionally called “necrosis”.⁴ Majno and Joris,⁵ who regard non-apoptotic cell deaths an under-researched area, have convincingly argued that necrosis actually refers to changes secondary to cell death by any mechanism. For now, lysis therefore appears to be a passable descriptive term for the present eosinophil phenomenon.

Since the free granules are observed in large tissue samples, using a whole mount technique combined with deep tissue staining of eosinophil peroxidase, sampling and sectioning artefacts are avoided in these experiments.²¹ The analysis is complemented by transmission electron microscopy that demonstrates lysis of eosinophils and provides details of the features and the locations of the free granules.^{21,22} From these animal observations (fig 1) it has been established that the presence of Cfegs in the airway tissue is a real phenomenon which is not caused by the handling of the tissue and does not just reflect chance observations. Furthermore, the free granules are induced by

common “asthma-like” provocations such as epithelial shedding/restitution and allergen exposure. These findings strengthen the significance of the occurrence of Cfegs in illustrations of the histopathology of human eosinophilic diseases including asthma, eosinophilic pneumonia, allergic rhinitis, and nasal polyposis.

Cfegs in asthmatic sputum samples

In 1879 Ehrlich²⁵ reported on specific staining methods of leucocytes and identified the eosinophils. Prior to this advancement eosinophils may frequently have been considered “Fett-Zellen”, implying that the granules were drops of fat. In 1872 Leyden²⁶ reported that these cells occurred together with numerous free granules in sputum samples from asthmatic patients. Before him Parrot²⁷ in 1867 (fig 2) and Foerster²⁸ in the 1850s depicted such cells. In their books, which shared the title “Asthma, its pathology and treatment”, both Salter²⁹ and Berkart³⁰ in 1860 and 1889, respectively, may have illustrated eosinophils and Cfegs (fig 2). In 1892 Schmidt³¹ applied histological fixation, sectioning and staining techniques to sputum samples to record eosinophils and Cfegs in sputum from asthmatic patients (fig 2). Using the same approach as Schmidt, with the addition of EPO staining and transmission electron microscopy, we have demonstrated Cfegs as a non-artifact phenomenon (fig 3) and eosinophils undergoing lysis in the sputum of asthmatic patients.¹⁴

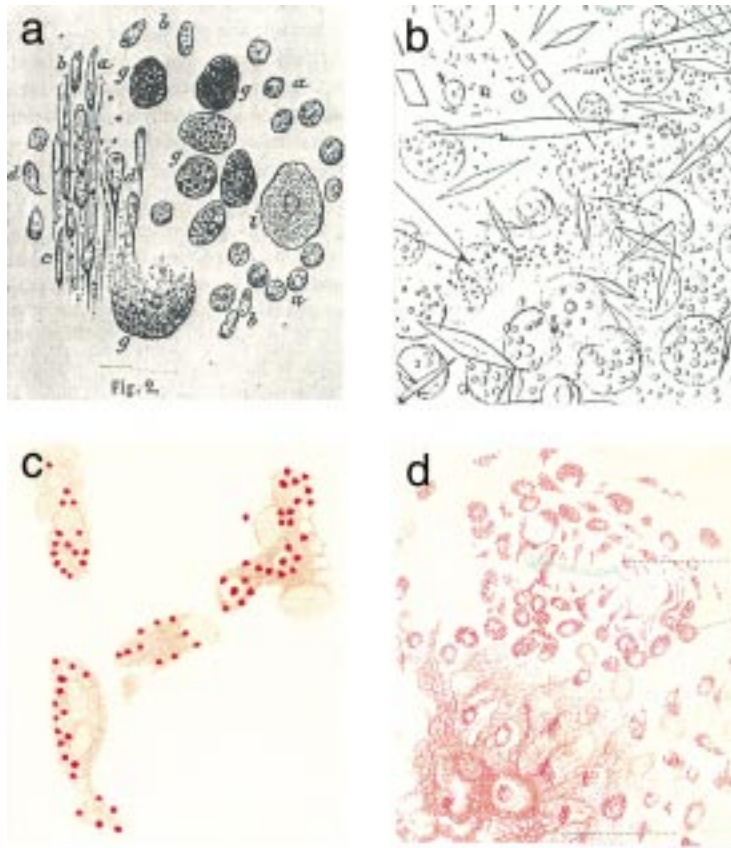


Figure 2 (a) Components of sputum from an asthmatic patient, perhaps including eosinophils and Cfegs (at "g") depicted by Parrot²⁷ in 1867. (b) Sputum sample from an asthmatic patient examined in 1872 by Leyden²⁶ showing crystals (previously observed by Charcot and others) in a sea of free granules and granular cells. (c) In the 1880s Berkart³⁰ demonstrated "leucocytes in a state of disintegration" in fresh asthma sputum. (d) A few years later in 1892 Schmidt³¹ put asthma sputum samples in fixative and stained sections of them to observe eosinophils and free eosinophil granules.

Cfegs and levels of eosinophilic cationic protein (ECP)

Levels of eosinophilic cationic protein (ECP) in cell-free samples of sputum and bronchoalveolar lavage fluid have become a major diagnostic index in asthma³² and eosinophilic pneumonia.³³ It is not known to what degree the reported levels of ECP reflect so-called "classical degranulation mechanisms" (the release of a small percentage of granule molecules occurring at cytokine/mediator challenge of cultured eosinophils^{34,35}). Indeed, since Cfegs may be very leaky (see below), and since they abound in the airway lumen (figs 2 and 3), the ECP may also emanate from Cfegs. Of greatest concern is the possibility that the analytically assessed ECP has not been released but more or less reflects what is stored in the Cfegs that would be present in cell-free fluids of airway surface material. Hence, free ECP levels can be accurately determined only if the sample, which is analysed, is free from both cells and Cfegs (this reasoning is equally valid to nasal samples). It appears that this problem of the interpretation has not received any attention. Admittedly, ECP levels in the sputum and bronchoalveolar lavage fluid remain of interest and importance, but perhaps as an index of the combined presence of Cfegs and amount of released ECP rather than as a specific measure of free, non-granular ECP.

Cfegs in airway pulmonary tissue

Some 80 years ago Felix Marchand³⁶ demonstrated epithelial eosinophilic inflammation in the entire respiratory tract of patients who had died from asthma. He remarked that free eosinophil granules reflected, in part, eosinophil death and, in part, artefacts.³⁶ Filley *et al.*,⁷ also studying fatal asthma, have now reported that free eosinophil granules ac-

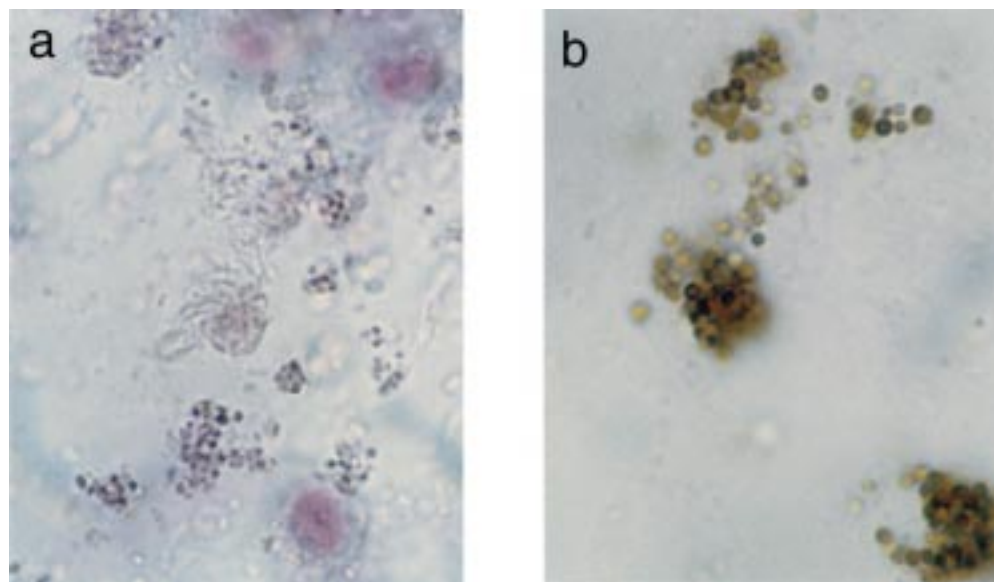


Figure 3 (a) Sputum sample from an asthmatic patient which was immediately fixed, stained and sectioned to show Cfegs and ciliated cells. (b) The presence of Cfegs is confirmed by histochemical staining with cyanide resistant EPO.¹⁴

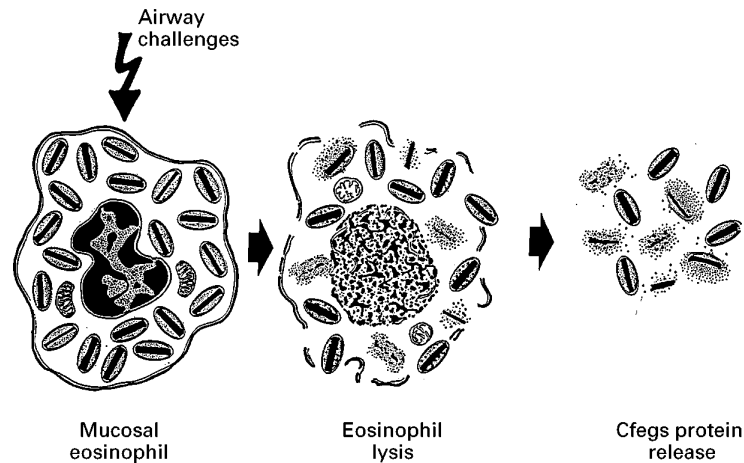


Figure 4 In asthma and allergic rhinitis mucosal eosinophils may be brought into lysis by causative events such as exposure to allergens or other noxious substances that harm the epithelial lining. Lysis is evident by membrane rupture, chromatolysis and swelling of mitochondria. This results in clusters of free eosinophil granules (Cfegs) in the lamina propria and the epithelium (and the lumen). The Cfegs are in different states of dissolution which suggests that the effective release of the granule contents is close to important mucosal target cells.

accumulate in the airways and stain intensely with anti-major basic protein. Jeffery *et al.*,⁶ in a careful electron microscopy study, demonstrated that, despite long term steroid treatment, Cfegs occur in the bronchi of patients with severe asthma. They also recorded high numbers of Cfegs in patients with mild allergic asthma. These Cfegs are reduced by treatment with inhaled steroids, perhaps as a reflection of the reduction of the number of eosinophils in the bronchial tissue by steroids.⁶ In guinea pig trachea and asthmatic bronchi free eosinophil granules may be seen close to neutrophils and lymphocytes.^{6,21,22} The free granules also reside in or close to airway end organs such as the epithelium (particularly at those patchy sites where intense processes of shedding/restitution are ongoing²²), the sub-epithelial microcirculation,^{21,22} the smooth muscle,⁶ and the regional lymph nodes.³⁷ Cfegs have also been seen close to a site of alveolar damage in a patient with idiopathic eosinophilic pneumonia.³⁸ The important distribution of Cfegs in airway pulmonary tissues provides ample opportunity for the pathophysiological effects of locally released granular products.

Cfegs as effector organelles

Intravenous injection of eosinophil granules was once used to show that the tissue toxicity of eosinophils is confined to these organelles.³⁹ Dvorak *et al.*,⁴⁰ examining skin tissue in hyper-eosinophilic syndrome, have demonstrated variable densities of membrane-bound, free eosinophil granules. In guinea pig trachea, too, free eosinophil granules, with or without membrane, exhibit variable degrees of dissolution density (fig 1).^{21,22} Transmission electron microscopy of nasal polyp tissues has indicated the presence of Cfegs in different states of dissolution and eosinophils displaying classical signs of cell lysis such as chromatolysis and

membrane discontinuity.¹⁴ Furthermore, transmission electron micrographs of parasites covered by Cfegs, and killed parasites in a soup of Cfegs, are strongly suggestive of a role for eosinophil lysis and Cfegs in combatting parasitic infections.^{41–45} However, the lysis of eosinophils and generation of Cfegs have not received much attention in parasite research or elsewhere and have, for the most part, not been distinguished from “degranulation”.

As observed in sensitised guinea pigs²² and suggested by findings in allergic asthma,⁶ atopic dermatitis,^{12,46} and seasonal allergic rhinitis,¹⁴ exposure to allergen will induce eosinophil lysis and free granules. Observations of in vivo sequelae to shedding-like removal of airway epithelium in guinea pigs further suggest the possibility that epithelial shedding/restitution may produce free eosinophil granules in asthma.²¹ (In in vivo experiments the dynamic brew of plasma-derived proteins/peptides may affect eosinophils of the inflamed airways in ways which may be difficult to mimic ex vivo.¹⁹) Macrophages may ingest Cfegs but this does not appear to be a very efficient mechanism of elimination. Non-ingested Cfegs thus abound in allergic reactions,^{12,14,22,46} parasitic infections,^{41–45} and in epithelial damage/repair processes.^{21,22} Taken together, these observations agree with the notion that the extracellular eosinophil granules may be very leaky and that endogenous mechanisms do not neutralise the Cfegs promptly. At the current state of knowledge the mechanism of generation of Cfegs and their activity cannot be described at a reductionist level. However, eosinophil lysis and generation of Cfegs would functionally represent the ultimate activation of the eosinophils. This may be viewed grossly as a two step event – first the release of granules and then the release of granular products (fig 4).

Cfegs in animal models

Eosinophil lysis and generation of Cfegs are not only phenomena of humans and guinea pigs. As suggested by a singular statement in the results section of a recent study,⁴⁷ free eosinophil granules may occur in a non-human, primate model of allergic asthma. Similarly, Cfegs occur in the airways of allergen challenged sensitised dogs (unpublished observations). Unfortunately, the widely used mouse models of allergic asthma may not exhibit Cfegs. The lungs of allergic mice may develop a very pronounced eosinophilia but these cells may neither show signs of activation nor may they abound in the epithelium.^{48,49} It appears that several aspects of the generation and the activity of airway Cfegs may potentially be explored in guinea pigs. However, the experimental animal approach cannot reduce the priority of learning more about eosinophil lysis and Cfegs in diseases of the human airway. This phenomenon may also be examined to some extent in experiments involving human isolated eosinophils.^{50,51}

Concluding remarks

Modern researchers may take it for granted that gross in vivo processes of the inflamed

airway mucosa have already been well examined and described. One assumes that this must be so since the major features of the asthmatic airways have been known for 100 years or more.⁵² However, as this review attempts to emphasise, knowledge of the in vivo activation of a major inflammatory cell, the eosinophil, is severely lacking. Even worse, we appear to act as if blindfolded when in vivo findings of potential importance to this in vivo activation are presented. The excuse for this neglect – for example, the inference that the in vivo phenomena are not of interest since they disagree with the all important in vitro paradigms – is, at the very least, poor. Is this example from the area of eosinophil research the odd exception? Probably not. For example, we may be equally ignorant about gross vascular and epithelial aspects of asthma. Vasodilatation and plasma exudation were in vogue in the late 1800s⁵² but today little is discussed or known about plasma derived molecules (as opposed to data on in vitro cell derived molecules) as determinants of the biologically active milieu of the inflamed airway mucosa.⁵³ Berkart³⁰ in the 1880s, and several of his contemporary and subsequent German colleagues,^{36,54,55} more or less explicitly⁵² saw asthma as an epithelial disease with shedding being a hallmark feature. Today the processes of epithelial shedding and restitution, and particularly their in vivo sequelae, are just beginning to be unravelled.⁵⁶ And so forth. If the relevant paradigms cannot be created in vitro (due to altered cell phenotypes, non-relevant molecular milieu, etc), and if the currently acknowledged in vivo paradigms (which are adopted for in vitro descriptive work at cellular and molecular levels) are not well researched or are false, the way forward in several areas will probably have to be based on in vivo discovery research that asks the important questions.⁵⁷ The fact that the exploratory in vivo approach now receives little encouragement is another matter.¹⁹

In want of a more specific name we have used the term eosinophil lysis in this text to describe the "activation" process which generates Cfegs in the relevant target tissues in asthma, allergic rhinitis, nasal polyposis, and eosinophilic pneumonia (and other eosinophilic diseases including the anti-parasite eosinophil mechanisms). Multifaceted experimental work now seems warranted to define and explain further the generation of Cfegs in vivo. It cannot be overlooked that finely tuned mechanisms are involved which are subject to physiological and pharmacological regulation. Hence, novel eosinophil active drugs may be discovered⁵⁸ and important molecular mechanisms of inflammatory cell activation may be unravelled.

The authors thank Mrs Mai Broman for expert secretarial assistance.

- 1 Simon H-U, Blaser K. Inhibition of programmed eosinophil death: a key pathogenic event for eosinophilia? *Immunol Today* 1995;16:53-5.
- 2 Gleich GJ, Kay AB, eds *Eosinophils in allergy and inflammation*. New York: Marcel Dekker, 1994:i-xxiv and 1-496.
- 3 Cox G, Ohtoshi T, Vancheri C, et al. Promotion of eosinophil survival by human bronchial epithelial cells and its mod-

- ulation by steroids. *Am J Respir Cell Mol Biol* 1991;4:525-31.
- 4 Duvall E, Wyllie AG. Death and the cell. *Immunol Today* 1986;7:115-9.
- 5 Majno G, Joris J. Apoptosis, oncosis, and necrosis. An overview of cell death. *Am J Pathol* 1995;146:3-15.
- 6 Jeffery PK, Godfrey RW, Adelroth E, Nelson F, Rogers A, Johansson S-A. Effects of treatment on airway inflammation and thickening of basement membrane reticular collagen in asthma. *Am Rev Respir Dis* 1992;145:890-9.
- 7 Filley WV, Kephart GM, Holley KE, Gleich GJ. Identification by immunofluorescence of eosinophil granule major basic protein in lung tissues of patients with bronchial asthma. *Lancet* 1982;ii:11-16.
- 8 Ohashi Y, Motojima S, Fukuda T, Makino S. Airway hyper-responsiveness, increased intracellular spaces of bronchial epithelium, and increased infiltration of eosinophils and lymphocytes in bronchial mucosa in asthma. *Am Rev Respir Dis* 1992;145:1469-76.
- 9 Beasley R, Roche WR, Roberts JA, Holgate ST. Cellular events in the bronchi in mild asthma and after bronchial provocation. *Am Rev Respir Dis* 1989;139:806-17.
- 10 Laitinen LA, Laitinen A, Haahntela T. Airway mucosal inflammation even in patients with newly diagnosed asthma. *Am Rev Respir Dis* 1993;147:697-704.
- 11 Dvorak AM, Mihm MC, Osage JE, Kwan TH, Austen KF, Wintroub BU. Bullous pemphigoid, and ultrastructural study of the inflammatory response: eosinophil, basophil and mast cell granule changes in multiple biopsies from one patient. *J Invest Dermatol* 1982;78:91-101.
- 12 Leiferman KM, Fujisawa T, Gray BH, Gleich GJ. Extracellular deposition of eosinophil and neutrophil granule proteins in the IgE-mediated cutaneous late phase reaction. *Lab Invest* 1990;62:579-89.
- 13 McEvoy JDS, Donald KJ, Edwards RL. Immunoglobulin levels and electron microscopy in eosinophilic pneumonia. *Am J Med* 1978;64:529-36.
- 14 Erjefält JS, Greiff L, Andersson M, Persson G, Korsgren M, Sundler F, Persson CGA. Eosinophil lysis and clusters of free eosinophil granules (Cfegs) in rhinitis and asthma. *Am J Respir Crit Care Med* 1997 (in press).
- 15 Dvorak AM. Similarities in the ultrastructural morphology and developmental and secretory mechanisms of human basophils and eosinophils. *J Allergy Clin Immunol* 1994;94:1103-34.
- 16 Martin LB, Kita H, Leiferman KM, Gleich GJ. Eosinophils in allergy: role in disease, degranulation, and cytokines. *Int Arch Allergy Immunol* 1996;109:207-15.
- 17 Beeson PB, Bass DA. *The eosinophil*. Philadelphia: WB Saunders, 1977.
- 18 Weller PF. The immunobiology of eosinophils. *N Engl J Med* 1991;324:1110-8.
- 19 Persson CGA. In vivo veritas. *Thorax* 1996;51:441-3.
- 20 Kallós P, Pagel W. Experimentelle untersuchungen ueber Asthma bronchiale. *Acta Med Scand* 1937;91:292-305.
- 21 Erjefält JS, Sundler F, Persson CGA. Eosinophils, neutrophils, and venular gaps in the airway mucosa at epithelial removal – restitution. *Am J Respir Crit Care Med* 1996;153:1666-74.
- 22 Erjefält JS, Korsgren M, Nilsson M, Sundler F, Persson CGA. Association between inflammation and epithelial damage-restitution processes in allergic airways in vivo. *Clin Exp Allergy* 1997 (in press).
- 23 Korsgren M, Erjefält JS, Erjefält I, Mulder H, Sundler F, Persson CGA. Eotaxin may regulate homing of eosinophils to airway epithelium: immunocytochemical and in situ hybridisation studies in naive and allergen challenged guinea-pigs. *Am J Respir Crit Care Med* 1997 (in press).
- 24 Griffiths-Johnson DA, Collins PD, Rossi AG, Jose PJ, Williams TJ. The chemokine, eotaxin, activates guinea-pig eosinophils in vitro and causes their accumulation into the lung in vivo. *Biochem Biophys Res Commun* 1993;197:1167-72.
- 25 Ehrlich P. Beiträge zur Kenntnis der granulierten Bindegewebszellen und der eosinophilen Leucocyten. *Arch Anat Physiol* 1879;3:166-82.
- 26 Leyden L. Zur Kenntnis des Bronchialasthmas. *Arch Path Anat* 1872;54:324-41.
- 27 Parrot J. Asthme. In: *Dictionnaire encyclopédique des sciences médicales*. Paris: 1867:752.
- 28 Foerster A. *Atlas der microscopischen pathologischen Anatomie*. Leipzig, 1854-9, 66 (fig IV, tafel XIII).
- 29 Salter HH. *Asthma: its pathology and treatment*. London: Churchill, 1860.
- 30 Berkart JJB. *Asthma: its pathology and treatment*. London: Churchill, 1889.
- 31 Schmidt A. *Zeitschrift für klinische Medizin* 1892;XX:476-500.
- 32 Venge P, Håkansson L. The eosinophil and asthma. In: Kaliner MA, Barnes PJ, Persson CGA, eds. *Asthma: its pathology and treatment*. New York: Marcel Dekker, 1991:477-502.
- 33 Janin A, Torpier G, Courtin P, Capron M, Prin L, Tonnel A-B, et al. Segregation of eosinophil proteins in alveolar macrophage compartments in chronic eosinophilic pneumonia. *Thorax* 1993;48:57-62.
- 34 Abu-Ghazaleh RI, Fujisawa T, Mestecky J, Kyle RA, Gleich GJ. IgA-induced eosinophil degranulation. *J Immunol* 1989;142:2393-400.
- 35 Dvorak AM, Furitsu T, Letourneau L, Ishizaka T, Ackerman SJ. Mature eosinophils stimulated to develop in human cord blood mononuclear cell cultures supplemented with recombinant human interleukin-5. *Am J Pathol* 1991;138:69-82.

- 36 Marchand F. Beitrag zur Pathologie und pathologischen Anatomie des Bronchial Asthma. *Beitr Path Anat* 1916; **61**:251–324.
- 37 Korsgren M, Erjefält JS, Erjefält I, Sundler F, Persson CGA. Occurrence of eosinophils (EOS) in tracheobronchial lymph nodes (TBLN) of sensitized guinea pigs. *Am J Respir Crit Care Med* 1997 (in press).
- 38 Gonzales EB, Swedo JL, Rajaraman S, Daniels JC, Grant JA. Ultrastructural and immunohistochemical evidence for release of eosinophilic granules in vivo: cytotoxic potential in chronic eosinophilic pneumonia. *Allergy J Clin Immunol* 1986; **79**:755–62.
- 39 Seiler G, Westerman RA, Wilson JA. The role of specific eosinophil granules in eosinophil-induced experimental encephalitis. *Neurology* 1969; **19**:478–88.
- 40 Dvorak AM, Weller PF, Monahan-Earley RA, Letourneau L, Ackerman SJ. Ultrastructural localisation of Charcot-Leyden crystal protein (lysophospholipase) and peroxidase in macrophages, eosinophils, and extracellular matrix of the skin in the hypereosinophilic syndrome. *Lab Invest* 1990; **62**:590–607.
- 41 Rácz P, Tenner-Rácz K, Büttner DW, Albiez EJ. Ultrastructural evidence for eosinophil-parasite adherence (EPA) reaction in human onchocercal lymphadenitis in the early period following diethylcarbamazine treatment. *Tropenmed Parasit* 1982; **33**:213–18.
- 42 Pimenta PFP, Dos Santos MAV, De Souza W. Fine structure and cytochemistry of the interaction between *Leishmania mexicana amazonensis* and rat neutrophils and eosinophils. *J Submicrosc Cytol* 1987; **19**:387–95.
- 43 Rácz P, Tenner-Rácz K, Büttner DW, Safar P. Immunopathologic reactions of lymph nodes in parasitic infections. *Fortschritte der Zoologie, Band 27, Suppl 12: Immune reactions to parasites*. Stuttgart: Gustav Fischer Verlag, 1982:161–7.
- 44 Kephars GM, Gleich GJ, Connor DH, Gibson DW, Ackerman SJ. Deposition of eosinophil granule major basic protein onto microfilariae of *onchocerca volvulus* in the skin of patients treated with diethylcarbamazine. *Lab Invest* 1984; **50**:51.
- 45 Wildenburg G, Darge K, Knab J, Tischendorf FW, Bonow I, Büttner DW. Lymph nodes of onchocerciasis patients after treatment with ivermectin: reaction of eosinophil granulocytes and their cationic granule proteins. *Trop Med Parasitol* 1994; **45**:87–96.
- 46 Schlecht H, Schwenker G. Über die Beziehungen der Eosinophilie zur Anaphylaxie. *Dtsch Arch Klin Med* 1912; **108**:405–28.
- 47 Gundel RH, Gerritsen ME, Gleich GJ, Wegener CD. Repeated antigen inhalation results in prolonged airway eosinophilia and airway hyperresponsiveness in primates. *J Appl Physiol* 1990; **68**:779–86.
- 48 Erjefält JS, Andersson P, Gustafsson B, Korsgren M, Sonmark B, Sundler F, et al. Allergen challenge-induced extravasation of plasma in the large airways of allergic mice. *Am J Respir Crit Care Med* 1997 (in press).
- 49 Korsgren M, Erjefält JS, Korsgren O, Sundler F, Persson CGA. Allergic eosinophil-rich inflammation develops in lungs-airways of B cell-deficient mice. *J Exp Med* 1997 (in press).
- 50 Villalta F, Pankratz HS, Kierszenbaum F. Extracellular killing of *Trypanosoma cruzi* amastigotes by human eosinophils. *J Protozool* 1987; **34**:285–90.
- 51 Weiler CR, Kita H, Hukee M, Gleich GJ. Eosinophil viability during immunoglobulin-induced degranulation. *J Leukoc Biol* 1996; **49**:3–501.
- 52 Persson CGA. Centennial notions of asthma as an eosinophilic, desquamative, exudative, and steroid-sensitive disease. *Lancet* 1997 (in press).
- 53 Persson CGA. Role of plasma exudation in asthma. *Lancet* 1986; **ii**:1186–9.
- 54 Curschmann H. Ueber Bronchiolitis exsudative und ihr Verhältnis zum Asthma nervosum. *Dtsch Arch Klin Med* 1883; **32**:1–34.
- 55 Fraenkel A. Zur pathologischen Anatomie des Bronchialasthmas. *Z Klin Med* 1898; **35**:559–72.
- 56 Persson CGA, Erjefält JS. Airway epithelial restitution after shedding and denudation. In: Crystal RG, West JB, et al, eds. *Scientific foundations. The lung*. 2nd ed. Philadelphia: Lippincott-Raven, 1997:2611–27.
- 57 Woolcock AJ, Barnes PJ. Asthma: the important questions. Part 3. *Am J Respir Crit Care Med* 1996; **153**:51.
- 58 Persson CGA, Erjefält JS. Eosinophil lysis and free granules: an in vivo paradigm for cell activation and drug development. *Review TIPS* 1997 (in press).