
Case reports

Commentary

D J Shale

The care of adults with cystic fibrosis has become an increasingly prominent part of the professional life of many respiratory physicians. An evolving new group of patients brings with it new experiences in management, a need to develop new skills, and problems induced by the use of these skills and techniques.

Since the description of the cystic fibrosis transmembrane conductance regulator (CFTR) gene and the $\Delta F508$ mutation there have been at least a further 400 mutations reported, although most patients are affected by a restricted range of mutations.¹ Some of these mutations may be associated with mild respiratory disease which may not immediately suggest cystic fibrosis and, hence, respiratory physicians with or without an interest in cystic fibrosis need to be aware of such a possibility. Gregory *et al*² report a family with cystic fibrosis of mild severity associated with heterozygote status for two mutations. The patient diagnosed at the relatively late age of 14 years was found to be a heterozygote with a $\Delta F508$ and an unknown mutation which was associated with very mild disease, particularly with regard to the respiratory system. Genetic analysis of the family involving his male sibling and parents showed that his unknown mutation clearly came from his mother and that she had passed on a known mutation (G551D) to her other son, proving that she was a compound heterozygote with non-matched mutations in her CFTR alleles.

This is an unusual pattern of diagnosis as the mother was 46 years old at this stage. However, with 400 mutations it is to be expected that such patients may occur but remain largely undiagnosed if the phenotype is mild. It is of interest that the mother's diagnosis was purely fortuitous and did not derive from a clinical suspicion. Indeed, she was only deemed to be clinically affected after the genotype data were known. She, too, had mild variant disease, although she exhibited more symptoms within the respiratory system than her son. Awareness of cystic fibrosis causing mild respiratory disease is important and should be borne in mind by respiratory physicians.

This case emphasises that cystic fibrosis can occur in a range of clinical forms and degrees of severity with little to suggest it as a diagnosis unless there is clinical suspicion. It also indicates the importance of genotyping as an essential element of diagnosis so that a known probability of exclusion for cystic fibrosis can be confidently given. Indeed, with a negative

sweat test and mild lung disease as the possible phenotypic expression of the disorder, the genotype seems to be the only clear way of making a confident diagnosis.

The need for regular intravenous antibiotic therapy, often administered at home by the patient, has led to the use of a variety of venous access devices. These range from standard venous cannulae with sterilisation filters and paediatric long lines, both of which may provide access for up to two weeks, to the implanted reservoir devices with a central venous infusion line. Amongst the latter devices the Port-a-Cath has become popular both with patients and health professionals. Such devices have been widely used in the last decade and are associated with low rates of infection or thrombosis in comparison with external access systems. In general their use in cystic fibrosis has been successful, although most reports have involved small numbers of patients. Thrombosis is a risk with any intravascular device but few reports have indicated life threatening sequelae. Yung *et al*³ report a patient in whom a large clot formed at the catheter tip in the right atrium which became detached following thrombolytic therapy, causing a pulmonary embolus which needed thrombolysis. This appears to be a remote risk with implanted devices from the limited literature in this area. Physicians using such systems need to be aware of the potential of such complications, but should realise that, on the basis of current experience, the magnitude of the risk is small. In cases where a blocked line occurs it may be worth performing a CT scan with contrast medium to determine if a significant thrombus is the cause, and physicians should be aware of the risk of embolisation.

A similar understanding of the risk involved in invasive procedures is required when considering the report by Fraser *et al*⁴ of reversible transverse myelitis following bronchial artery embolisation for haemoptysis. This is a well recognised option for the treatment of haemoptysis that cannot be controlled by conservative measures. In general it is a safe procedure that has been widely used in the treatment of patients with cystic fibrosis. These neurological sequelae relate to the origins of the bronchial vessels, which can be both complex and variable, and their relationship to the anterior spinal arteries which are essentially end arteries. The mechanism of injury may derive from the use of contrast media to define the anatomy of the

Section of Respiratory
Medicine, University
of Wales College of
Medicine, Llandough
Hospital, Penarth,
South Glamorgan
CF64 2XX, UK
D J Shale

Correspondence to:
Professor DJ Shale.

bronchial vasculature or accidental occlusion when the bronchial vessels are embolised. In the patient described by Fraser *et al* it is likely that the contrast medium caused the reversible transverse myelitis since this is a recognised risk of angiography and Kardjiev *et al*⁵ reported five similar cases when the same segmental intercostal vessels were injected with contrast medium. In this case there was a resolution of symptoms which again suggests that this is an effect of contrast medium rather than embolisation of the anterior spinal vessels. Bronchial artery embolisation is a recognised form of treatment for a small number of patients and the risk of complications, such as those recorded here, is very low.

As more patients with cystic fibrosis survive longer, develop more respiratory disease, and require an aggressive clinical response, there will be examples of adverse events. Such problems in a highly specific group of patients may

be less likely to occur or be more easily dealt with in specialist centres where experience of such problems and expertise is available. We need to accept their existence in recommending treatment, but should bear in mind the relative safety of such manoeuvres and the benefits they have brought to patients with cystic fibrosis who can now expect to survive into early adulthood.

- 1 The Cystic Fibrosis Genetic Analysis Consortium. Population variation of common CF mutations. *Hum Mutat* 1994;4: 167-77.
- 2 Gregory GA, Woolf DA, McMahon R, Maher ER, Barton DE. Cystic fibrosis diagnosed by molecular genetic investigation in the mother of a patient with cystic fibrosis. *Thorax* 1997;52:96-7.
- 3 Yung B, Elborn JS, Campbell IA, Summers Y, Beckles M, Woodcock AA. Thromboembolism related to a Port-a-Cath device in a patient with cystic fibrosis. *Thorax* 1997; 52:98-9.
- 4 Fraser KL, Grossman H, Hyland RH, Tullis DE. Transverse myelitis: a reversible complication of bronchial artery embolisation in cystic fibrosis. *Thorax* 1997;52:99-101.
- 5 Kardjiev V, Symeonov A, Chankov I. Etiology, pathogenesis and prevention of spinal cord lesion in selective angiography of the bronchial and intercostal arteries. *Radiology* 1974; 112:81-3.

Thorax 1997;52:96-97

Cystic fibrosis diagnosed by molecular genetic investigation in the mother of a patient with cystic fibrosis

G A Gregory, D A Woolf, R McMahon, E R Maher, D E Barton

Abstract

Cystic fibrosis was diagnosed in the 46 year old mother of an index patient as a result of molecular genetic analysis, illustrating the need to consider the diagnosis at any age in the close relatives of patients with cystic fibrosis.

(*Thorax* 1997;52:96-97)

Keywords: cystic fibrosis, molecular genetic analysis.

Mrs C's son, JC, was diagnosed as having cystic fibrosis at 14 years of age following investigation of short stature (height 138 cm; <3rd centile) and loose stools. There were no major respiratory symptoms at the time. The diagnosis was confirmed by sweat testing. He is now 23 years old and remains very well with minimal symptoms. The family were referred to a clinical genetics department for advice on the carrier status of an unaffected brother.

Molecular genetic analysis showed that JC is heterozygous for the common cystic fibrosis mutation, $\Delta F508$, which he inherited from his father (fig 1). In addition to $\Delta F508$, Mrs C and JC have been screened for nine other commonly found cystic fibrosis mutations:¹ G85E, R117H, 621+1G→T, 1717-1G→A, S549?, R553X, G542X, G551D, and N1303K. Exons 3, 7, 11, 20, and 21 of their cystic fibrosis transmembrane conductance regulator (CFTR) genes have also been subject to single strand conformational variant analysis without detecting any base changes in JC, hence the cystic fibrosis mutation JC inherited from his mother has not been identified and we have ruled out 85% of mutations found in patients with cystic fibrosis in the UK. Surprisingly, genotyping of Mrs C showed that, in addition to the unidentified cystic fibrosis mutation which she has transmitted to JC, she also carries a nucleotide substitution in exon 11 that alters amino acid 551 from the normal glycine (G) to aspartate (D) which she has passed to her

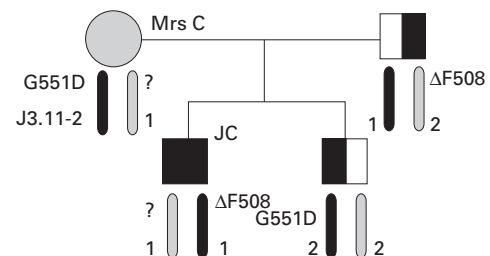


Figure 1 Pedigree of patient JC. As indicated by the linked RFLP marker J3.11-2/Msp, JC and his brother have inherited different maternal CFTR alleles. Mrs C must therefore carry an as yet uncharacterised mutation as well as the G551D mutation present in her younger son.

Department of Paediatrics, Peterborough District Hospital, Thorpe Road, Peterborough PE3 6DA, UK
G A Gregory
D A Woolf

East Anglian Regional Genetics Service, Addenbrooke's Hospital, Hills Road, Cambridge CB2 2QQ, UK
R McMahon
E R Maher
D E Barton

Correspondence to: Dr G A Gregory.

Received 21 October 1994
Returned to authors 23 March 1995
Revised version received 24 August 1995
Accepted for publication 30 August 1995

other son. She must therefore be a compound heterozygote with mutations in both alleles of her CFTR gene.

Following this unexpected finding, Mrs C was invited for consultation. She reported that she had been underweight and short as a child, with a persistent cough and recurrent chest infections. These symptoms had improved in adolescence but she had developed chronic sinusitis in her late teens, requiring sinus wash-outs and maxillary anastomies. More recently, there was a four year history of productive cough and exertional dyspnoea on climbing one flight of stairs or walking 200 yards on the flat. She had no gastrointestinal symptoms.

On examination Mrs C was short with a height on the 3rd centile (151.8 cm), although her weight was about the 90th centile (70.6 kg). She was not clubbed and auscultation of her chest was unremarkable. A chest radiograph showed signs of mild hyperinflation but no other abnormality, however lung function tests revealed a forced vital capacity (FVC) of 2.63 litres (61% of predicted), and a forced expiratory volume in one second (FEV₁) of 2.24 litres (53% of predicted). A sample of sputum grew *Staphylococcus aureus* and *Proteus* species. Sweat testing, performed and repeated after suppression with fludrocortisone, showed sweat sodium levels of 78 and 81 mmol/l and an osmolality of 202 and 211 mosmol/kg, respectively, confirming the diagnosis of cystic fibrosis.²

Discussion

Most patients with cystic fibrosis are diagnosed in the first two decades of life, with some regions detecting cases soon after birth by neonatal screening.³ However, up to 5% of patients present as adults. The diagnosis of cystic fibrosis in adults is usually made after a presentation with chronic respiratory symptoms, either alone or with bowel symptoms.⁴ Rarely, the presentation can occur with acute infection, respiratory failure, or pancreatitis.

Although generally there is no close correlation between pulmonary severity and genotype,⁵ certain mutations have been found to result in mild forms of cystic fibrosis even when associated with "severe" mutations. Congenital bilateral absence of vasa deferentia is a particular case. Up to 42% of these otherwise healthy patients carry at least one identifiable mutation and a further 24% are compound heterozygotes.⁶ In addition, patients with very

mild disease and negative sweat tests have been reported to be homozygous for certain mutations including R117H,^{6,7} G551S, and D1152H,^{8,9} emphasising the importance of genetic analysis in the diagnosis of cystic fibrosis.

With over 400 different mutations now identified in patients with cystic fibrosis¹ it is not feasible to screen for all mutations. Nevertheless, it is likely that more than 90% of Western European patients with rare cystic fibrosis mutations and a mild phenotype will also carry one of the more common and easily detected mutations, as was the case with Mrs C. In this case Mrs C was found to carry the G551D mutation which she has passed on to her other son, in addition to the unknown mutation that she must have transmitted to the index case, JC. We would therefore encourage the genetic screening of anyone who has mild and otherwise unexplained features of cystic fibrosis, with a sweat test being performed on those found to carry even a single cystic fibrosis mutation.

Cases of cystic fibrosis in mothers and their children have been described previously, although in all instances the mother was diagnosed first.¹⁰ This case illustrates the need to consider the diagnosis of cystic fibrosis, regardless of age, in family members of index cases even if only mild features of the condition are present. We believe that Mrs C is the first person to be diagnosed in this manner.

- 1 The Cystic Fibrosis Genetic Analysis Consortium. Population variation of common CF mutations. *Hum Mutat* 1994;4:167-77.
- 2 Hodson ME, Beldon I, Power R, Duncan FR, Bamber M, Battn JC. Sweat tests to diagnose cystic fibrosis in adults. *BMJ* 1983;286:1381-3.
- 3 Green MR, Weaver LT, Heeley AF, Nicholson K, Kuzemko JA, Barton DA, et al. Cystic fibrosis identified by neonatal screening: incidence, genotype and early natural history. *Arch Dis Child* 1993;68:464-7.
- 4 Hunt B, Geddes DM. Newly diagnosed cystic fibrosis in middle and late life. *Thorax* 1985;40:23-6.
- 5 The Cystic Fibrosis Genotype-Phenotype Consortium. Correlation between genotype and phenotype in patients with CF. *N Engl J Med* 1993;329:1308-13.
- 6 Mercier B, Verlingue C, Lissens W, Silber S, Novelli G, Bondulle M, et al. Is congenital bilateral absence of vas deferens a primary form of cystic fibrosis? Analyses of the CFTR gene in 67 patients. *Am J Hum Genet* 1995;56:272-7.
- 7 Bienvenue T, Beldjord C, Adliman M, Kaplan JC. Male infertility as the only presenting sign of cystic fibrosis when homozygous for the mild mutation R117H. *J Med Genet* 1993;30:797.
- 8 Strong TV, Smit LS, Turpin SV, Cole JL, Tom C, Markiewicz D, et al. Cystic fibrosis gene mutation in two sisters with mild disease and normal sweat electrolyte levels. *N Engl J Med* 1991;325:1630-4.
- 9 Rave-Harel N, Madgar I, Goshen R, Nissim-Rafinia M, Ziadni A, Rahat A, et al. CFTR haplotype analysis reveals genetic heterogeneity in the etiology of congenital bilateral aplasia of the vas deferens. *Am J Hum Genet* 1995;56:1359-66.
- 10 Purves LR, Rubinstein R, Maxwell J, Leisegang F, Ireland J. Robust and inexpensive equipment design for polymerase chain reaction detection of sequence mutations: cystic fibrosis in a mother and two children analysed. *S Afr Med J* 1993;83:25-7.