

## Case reports

A commentary on the following two case reports appears on page 1279.

### Gorham's syndrome: a usually fatal cause of pleural effusion treated successfully with radiotherapy

K D McNeil, K M Fong, Q J Walker, P Jessup, P V Zimmerman

#### Abstract

**A 21 year old man presented with a right sided pleural effusion. Destruction of the 11th and 12th right ribs and adjacent vertebral bodies was noted on computed tomographic scanning. An open rib biopsy revealed the histopathological changes of Gorham's syndrome. In view of the progressive vertebral destruction and inevitable spinal cord compromise, he was treated with high dose radiotherapy. The process was arrested and he remains well with no signs of recurrence after four years. Pleural effusion and vertebral destruction complicating Gorham's syndrome carry a poor prognosis but, in this case, high dose radiotherapy has been effective in controlling both the effusion and the progressive bony destruction.**

(Thorax 1996;51:1275-1276)

Keywords: Gorham's syndrome, radiotherapy, pleural effusion.

Gorham's syndrome is a rare disorder of unknown aetiology characterised by a non-malignant proliferation of vascular structures originating in bone with progressive bony destruction and often extending into surrounding soft tissues.<sup>1</sup> Complications range from mild discomfort to death, depending on the site of bony involvement. Pleural effusion and vertebral disease are uncommon but usually fatal complications of this condition.<sup>12</sup>

This report describes a case of Gorham's syndrome of the chest wall complicated by a pleural effusion and progressive vertebral destruction where a sustained recovery (four years) has been achieved with high dose radiotherapy.

#### Case report

A 21 year old man presented for investigation of a right sided pleural effusion. Four months prior to presentation he developed right chest

and flank pain following a football game. Two weeks before admission he developed shortness of breath and a large haematoma over his right flank. A chest radiograph showed a large right pleural effusion. There was no history of significant trauma. He was otherwise fit and well with no significant past medical or family history.

Pleural aspiration yielded two litres of heavily bloodstained fluid with immediate improvement in his breathlessness. Analysis of the pleural fluid showed a sterile exudate containing lymphocytes, red cells, and reactive mesothelial cells. The histology of pleural biopsy specimens showed collagenous fibrosis and a chronic inflammatory cell infiltrate. There was no evidence of malignancy, and no microorganisms (including acid fast bacilli and fungi) were seen with special stains or on subsequent culture. Full blood count revealed a haemoglobin of 12.8 g/dl but was otherwise normal. Erythrocyte sedimentation rate was 4 mm/hour. Coagulation studies and serum biochemical parameters were normal.

One week following the initial aspiration, the pleural fluid had re-accumulated. Computed tomographic (CT) scanning of the chest and upper abdomen showed the right pleural effusion but no other abnormalities. Surgical drainage and open pleural biopsy were performed and again histological examination showed only fibrosis and chronic inflammation with no direct or subsequent evidence of malignancy or infection. Pleurodesis was not performed at this time because of the uncertainty of the diagnosis.

Six weeks later he was readmitted with a recurrence of his symptoms. A chest radiograph confirmed re-accumulation of the right sided effusion. A repeat CT scan, however, showed, in addition to the effusion, complete destruction of the right 12th rib, partial destruction of the right 11th rib, and erosion of the right transverse process and body of the

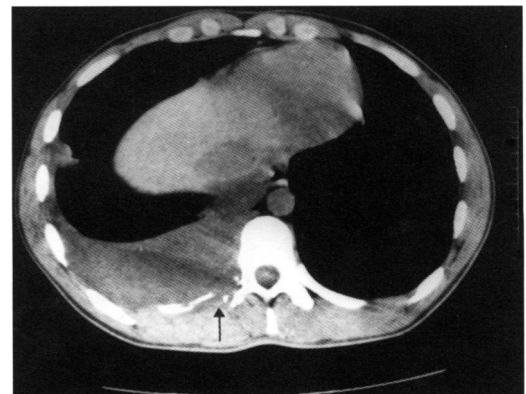


Figure 1 Computed tomographic scan showing pleural effusion and partial destruction of the right 11th rib (arrowed) and adjacent vertebral body.

Department of  
Thoracic Medicine  
K D McNeil  
P Jessup  
P V Zimmerman

Department of  
Pathology  
P Jessup

The Prince Charles  
Hospital,  
Chermside, Brisbane,  
Australia 4032

Queensland Radium  
Institute,  
Brisbane, Australia  
Q J Walker

Correspondence to:  
Dr K D McNeil.

Received 5 June 1995  
Accepted for publication  
17 August 1995

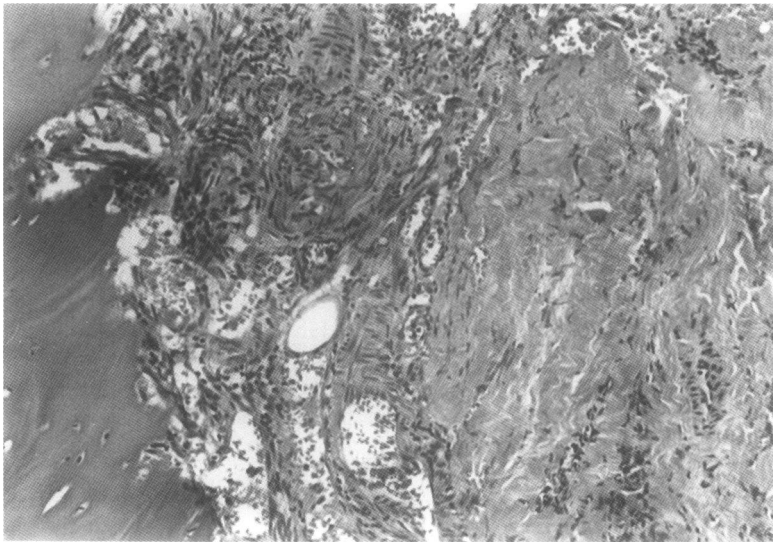


Figure 2 Photomicrograph of a biopsy specimen of the 11th rib showing replacement of medullary bone and early destruction of cortical bone by abnormal vascular structures. Original magnification  $\times 150$ .

11th thoracic vertebra (fig 1). A large haematoma was also seen extending from the right costal margin to the pelvic brim. Radionuclide bone scanning showed decreased activity in the right 11th and 12th ribs. Excision biopsy specimens and subsequent histological examination of the remaining right 11th rib showed bony destruction and replacement by masses of anastomosing vascular channels, infiltrating and destroying adjacent soft tissues (fig 2). There was no histological evidence of malignancy. The histological findings were compatible with Gorham's syndrome.

In view of the rapidly progressive bony destruction involving the spine, treatment was instituted with high dose radiotherapy (40 Gy in 20 fractions). This was directed at the right posterior thoracoabdominal wall including the vertebral column. A renal scan performed before treatment showed both kidneys to be functioning normally. The treatment was well tolerated and a significant improvement in symptoms was seen. It is now four years since completion of the radiotherapy and he has remained well with no evidence of recurrence on follow up.

## Discussion

The aetiology of Gorham's syndrome is unknown. Trauma is a frequently reported association but no causal link has been proven and in some cases it is trivial or absent.<sup>1</sup> Spontaneous remissions and regrowth of bone have been reported but in many cases the disease is inexorably progressive.<sup>1,3</sup>

Skeletal involvement is usually unifocal with adjacent bones and soft tissues involved by direct spread.<sup>1</sup> Recurrent pleural effusions and chylothorax may result from chest wall and mediastinal involvement and have been reported to cause infection, circulatory failure, cachexia, and death. Vertebral disease may progress to compromise the spinal cord.<sup>1,2</sup> In a review of 97 cases from the literature<sup>1</sup> there were 16 deaths directly attributable to the disease. In 10 thoracic cavity involvement was reported and a further three died following transection of the spinal cord.

Many different treatments have been tried, with recent interest centering on surgery<sup>2,4,5</sup> and radiotherapy.<sup>3</sup> Surgical excision of involved tissues, thoracic duct ligation, and pleurodesis have all been reported to be effective in the treatment of chylothorax complicating the disease.<sup>1,2,4,5</sup> There are no controlled trials of treatment. If potentially fatal complications occur the early use of radiotherapy at adequate doses is recommended.<sup>3,6</sup> In our case the progressive destruction of the vertebral column with inevitable spinal cord compromise mandated early aggressive therapy and the good outcome in our patient certainly supports this approach. Importantly, there has been no subsequent progression of the vertebral destruction on follow up CT scans, implying that the radiotherapy was effective in arresting the process as a whole, not merely serving as a means of pleurodesis.

- 1 Choma ND, Biscotti CV, Bauer TW, Mehta AC, Licata AA. Gorham's syndrome: a case report and review of the literature. *Am J Med* 1987;83:1151-5.
- 2 Feigl D, Seidel L, Marmor A. Gorham's disease of the clavicle with bilateral pleural effusions. *Chest* 1981;79:242-4.
- 3 Handl-Zeller L, Hohenberg G. Radiotherapy of Morbus Gorham-Stout: the biological value of low irradiation dose. *Br J Radiol* 1990;63:206-8.
- 4 Pedicelli G, Mattia P, Zorzoli AA, Sorone A, De Martino F, Sciotto V. Gorham syndrome. *JAMA* 1984;252:1449-51.
- 5 Patrick JH. Massive osteolysis complicated by chylothorax successfully treated by pleurodesis. *J Bone Joint Surg [Br]* 1976;58:347-9.
- 6 Meller JL, Curet-Scott M, Dawson P, Besser AS, Shermeta DW. Massive osteolysis of the chest in children: an unusual cause of respiratory distress. *J Pediatr Surg* 1993;28:1539-42.