

Parathyroid cyst of the thymus

W G McCluggage, C F J Russell,
P G Toner

Abstract

A case is described of primary hyperparathyroidism in a patient with both a parathyroid cyst within the thymus gland and a concomitant parathyroid adenoma. The parathyroid adenoma contained microcystic areas of degeneration, and it is thought that the parathyroid cyst reflected degenerative change in a pre-existing adenoma. Parathyroid cyst should be considered in the differential diagnosis of cystic lesions within the thymus. Fine needle aspiration and parathyroid hormone assay on cyst fluid may provide a preoperative diagnosis.

(*Thorax* 1995;50:913-914)

Keywords: parathyroid cyst, thymus.

Thymic cysts are relatively rare lesions, accounting for approximately 3% of all anterior mediastinal masses.¹ Most are acquired lesions and arise from the cystic transformation of medullary duct epithelium-derived structures (including Hassall's corpuscles), induced by an inflammatory process.² The inferior parathyroid glands and the thymus share a common embryonic origin from the third branchial pouch and it is not uncommon to find parathyroid tissue within the thymus. It is, therefore, not surprising that parathyroid cysts occasionally occur within the mediastinum, embedded within the thymus gland.³⁻⁵ We report such a case and discuss the differential diagnosis of cystic lesions of the thymus.

Case report

A 33 year old man was found to have asymptomatic hypercalcaemia. Serum calcium, measured on several occasions over a two year period, ranged from 2.78 to 3.03 mmol/l (normal 2.10-2.57 mmol/l). Serum parathyroid hormone levels, measured using an intact molecule assay, were also persistently high at 83-96 pg/ml (normal 10-55 pg/ml), thus confirming primary hyperparathyroidism. There was no family history of this nor of other endocrine disorders. Clinical examination was unremarkable. Thallium-technetium isotope subtraction scanning revealed a solitary "hot spot" low in the neck, lying just within the thoracic inlet. At neck exploration the thyroid gland was unremarkable. Normal parathyroid glands were identified in the left superior and left inferior positions. An enlarged right inferior parathyroid gland, corresponding to the lesion identified on the preoperative scan, was located at the apex of the cervical tongue of the thymus and removed. In addition, a 2 cm cystic mass was embedded at a lower level within the thymus gland on the right side. The cystic lesion and surrounding thymus were removed. Following surgery serum calcium levels fell to and remained within the normal range with no symptoms of hypocalcaemia. The serum parathyroid hormone level also returned to the normal range.

PATHOLOGICAL FINDINGS

Sectioning the thymus gland revealed a collapsed cyst measuring 2 cm in diameter. Histologically this was lined by a single layer of cuboidal to low columnar epithelial cells surrounded by islands of parathyroid chief cells and normal thymus with lymphoid tissue and Hassall's corpuscles embedded within mature adipose tissue (fig 1).

The right inferior parathyroid gland comprised a well circumscribed tan-coloured nodule weighing 270 mg. Histological examination showed this to be composed of lobules of chief cells separated by fibrovascular connective tissue (fig 2), in keeping with a parathyroid adenoma. An unusual feature was the presence of microcystic areas of degeneration (fig 2).

Discussion

Cystic lesions of the thymus gland are relatively rare.¹ Their main histological features include multiple cystic cavities, focally lined by squamous, cuboidal or columnar epithelium, and the presence of nests of non-neoplastic thymus within the cyst wall. They are often associated with acute and chronic inflammation, fibrovascular proliferation, necrosis, haemorrhage, and cholesterol granuloma formation. The dilatation of Hassall's corpuscles and their subsequent cystic transformation may be the result of an acquired inflammatory process. A similar pathogenesis underlies the multicystic thymus seen in congenital syphilis (Dubois' abscesses).⁶ Cystic change may occasionally be seen associated with Hodgkin's disease and seminoma involving the thymus.² Cyst formation is prob-

Department of
Histopathology
W G McCluggage

Endocrine Surgery
Unit
C F J Russell

Royal Group of
Hospitals,
Belfast BT12 6BL,
UK

The Queen's
University of Belfast
P G Toner

Reprint requests to:
Dr W G McCluggage.

Received 12 April 1994
Returned to authors
26 August 1994
Revised version received
7 September 1994
Accepted for publication
19 October 1994

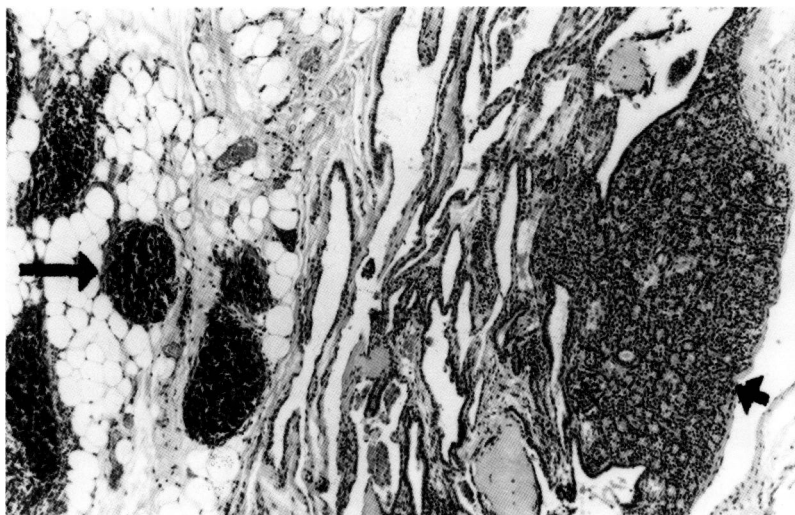


Figure 1 Collapsed cyst with parathyroid tissue (short arrow) in wall, embedded within thymus gland containing lymphoid tissue (long arrow). Haematoxylin and eosin, original magnification $\times 10$ increased by 28% in origination.

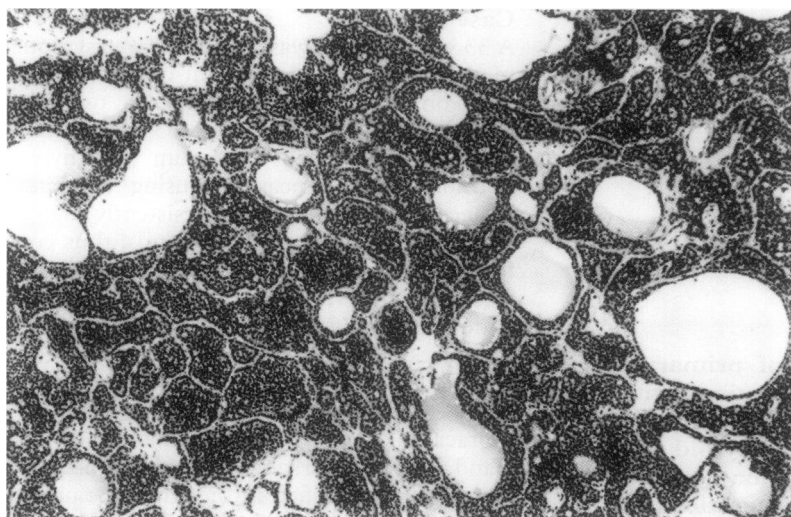


Figure 2 Parathyroid adenoma containing cystic areas of degeneration. Haematoxylin and eosin, original magnification $\times 25$ increased by 28% in origination.

ably due to inflammation associated with these tumours rather than to the tumour itself. Cysts within the thymus involved by Hodgkin's disease may develop before treatment or after radiotherapy.^{7,8} Other recognised variants of thymic cyst include degeneration within thymoma, dermoid cyst, lymphangioma, haemangioma, mediastinal thyroid cysts, developmental cyst of respiratory, gastrointestinal or pericardial tissue, and cyst of parathyroid origin. Cystic change may occur within the thymus following surgical trauma.

Parathyroid cyst is a rare lesion,^{3,4} generally arising in a cervical location and, if palpable, usually diagnosed preoperatively as a cystic thyroid nodule.⁴ The pathogenesis is uncertain. It may arise following cystic degeneration within an already enlarged parathyroid gland. Although in the present case it is not possible to confirm whether the cyst originated in a pre-existing parathyroid adenoma, a coexisting adenoma was removed and microcystic areas were seen on microscopic examination. Macroscopic parathyroid cysts could arise due to progressive enlargement of a single microcyst

or from coalescence of multiple microcysts which are sometimes seen in adenomatous or hyperplastic parathyroid glands. The distinction between a parathyroid adenoma and a hyperplastic parathyroid gland can be impossible on histological examination alone. In the present case the fact that two normal parathyroid glands were identified provides evidence that the parathyroid lesion was an adenoma rather than a hyperplastic gland.

A parathyroid cyst may be non-functional or may be hormonally active, resulting in hyperparathyroidism. Of 11 patients with parathyroid cysts reported by Calandra *et al*³ 10 had primary hyperparathyroidism corrected by removal of the cyst. Rosenberg and colleagues⁴ described 14 parathyroid cysts of which eight were functional and associated with hyperparathyroidism. Although our patient had primary hyperparathyroidism corrected by resection, a coexisting parathyroid adenoma was present and it is not possible to ascertain whether the cyst itself was functional.

As with other tumours of the neck region, fine needle aspiration may be a valuable diagnostic tool. Parathyroid cysts typically contain clear, watery fluid and, in both functioning and non-functioning cysts, parathyroid hormone is present in high concentrations.^{4,9,10} Assay of the aspirated fluid for parathyroid hormone may provide a preoperative diagnosis.

- 1 Davis RD Jr, Oldham NH Jr, Sabiston DC. Primary cysts and neoplasms of the mediastinum: recent changes in clinical presentation, methods of diagnosis, management and results. *Ann Thorac Surg* 1987;4:229-37.
- 2 Suster S, Rosai J. Multilocular thymic cysts: an acquired reactive process. *Am J Surg Pathol* 1991;15:388-98.
- 3 Calandra DB, Shah KH, Prinz RA, Sullivan H, Hofmann C, Oslapas R, *et al*. Parathyroid cysts: a report of eleven cases including two associated with hyperparathyroid crisis. *Surgery* 1993;94:887-92.
- 4 Rosenberg J, Orlando R, Ludwig M, Pyrttek LJ. Parathyroid cysts. *Am J Surg* 1982;143:473-80.
- 5 Petri N, Holten I. Parathyroid cyst: report of case in the mediastinum. *J Laryngol Otol* 1990;104:56-7.
- 6 Dubois P. Thymic cysts. *J Thorac Surg* 1954;27:477-93.
- 7 Baron RL, Sagal SS, Baglan RJ. Thymic cyst following radiation therapy for Hodgkin's disease. *Radiology* 1981;141:593-7.
- 8 Kim HC, Noshier J, Haas A, Sweeney W, Lewis R. Cystic degeneration of thymic Hodgkin's disease following radiation therapy. *Cancer* 1985;55:354-6.
- 9 Wang CA, Vickery AL, Maloof F. Large parathyroid cysts mimicking thyroid nodules. *Ann Surg* 1972;175:448-53.
- 10 Clark OH. Parathyroid cysts. *Am J Surg* 1978;135:295-402.