

## Case reports

A commentary on the following three case reports appears on page 1323.

# Successful extracorporeal membrane oxygenation (ECMO) support for fulminant community-acquired pneumococcal pneumonia

Massimiliano Codispoti, Keith Sanger, Pankaj S Mankad

### Abstract

**A case is described of fulminant community-acquired pneumococcal pneumonia in a 16 year old girl with no previous history of respiratory disease or any predisposing factors. She required extracorporeal membrane oxygenation (ECMO) until the diagnosis could be made and appropriate antibiotic therapy established.**

(Thorax 1995;50:1317-1319)

Keywords: pneumococcal pneumonia, extracorporeal membrane oxygenation (ECMO).

Despite advances in antimicrobial therapy, improved diagnostic and microbiological techniques, and sophisticated respiratory support systems,<sup>1</sup> pneumonia remains an important cause of mortality and morbidity world wide.<sup>2</sup> Rarely, its rapidity of onset may be such that the patient's condition is severely impaired before appropriate antibiotic therapy can be established. We report the successful use of extracorporeal membrane oxygenation (ECMO) in a girl with community-acquired pneumococcal pneumonia.

### Case report

A 16 year old girl presented with a five day history of tiredness, nausea, loss of appetite, and a 24 hour onset of chest ache and yellow sputum. On examination she was pale, tachypnoeic, distressed, with a temperature of

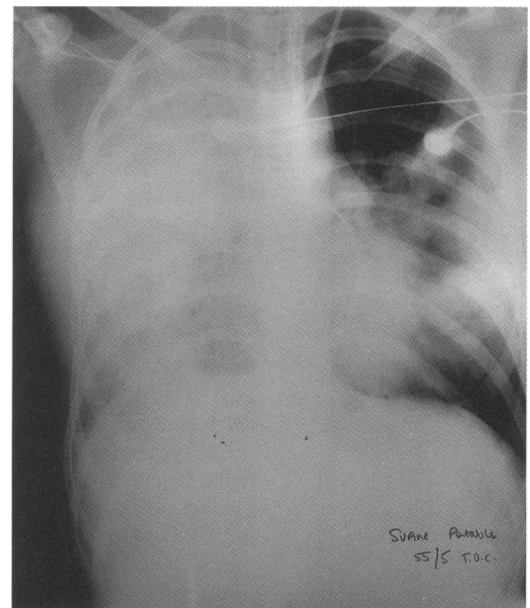


Figure 1 Anteroposterior chest radiograph at the time of admission (prior to instituting ECMO) showing bilateral pulmonary consolidation.

37.4°C. There was decreased expansion of the right hemithorax and widespread inspiratory crepitations. Chest radiography showed evidence of consolidation of the right lung and of the mid and lower zones of the left lung (fig 1). White blood count was  $2.8 \times 10^9/l$ , platelet count was  $133 \times 10^9/l$ . She was found to be negative for HIV, hepatitis B and C. Blood, sputum and urine specimens were sent for culture, together with urine and blood samples for detection of pneumococcal antigen. While awaiting the results, empirical antibiotic/antiviral therapy was established with erythromycin, flucloxacillin, ampicillin, and acyclovir.

A few hours after admission she became increasingly tachypnoeic, tachycardic, and hypotensive. Arterial blood gas tensions on 60%  $F_{iO_2}$  via a face mask revealed  $P_{aO_2}$  of 5.5 kPa and  $P_{aCO_2}$  6.23 kPa. She was electively ventilated. While receiving full ventilatory support she became increasingly hypotensive so that it was necessary to start adrenaline and, subsequently, noradrenaline infusion in order to maintain adequate organ perfusion.

The morning after admission, despite maximal inotropic and ventilatory support, the patient's haemodynamic and ventilatory parameters deteriorated further and were considered incompatible with survival. Therefore, 20 hours after admission she was referred for consideration of ECMO support.

The following clinical features were present at the time of referral: heart rate 160 bpm, systemic blood pressure 65/35 mm Hg, central venous pressure 15 mm Hg, pulmonary artery pressure 38/24 mm Hg, cardiac index 5.7 l/

Department of  
Cardiothoracic  
Surgery, Royal  
Infirmary NHS Trust,  
Edinburgh EH3 9YW,  
UK

M Codispoti  
K Sanger  
P S Mankad

Reprint requests to:  
Dr M Codispoti, Istituto di  
Chirurgia del Cuore e dei  
Grossi Vasi, Policlinico  
Umberto I, 00161 Rome,  
Italy.

Received 26 September  
Returned to authors  
20 January 1995  
Revised version received  
20 April 1995  
Accepted for publication  
1 June 1995

min/m<sup>2</sup>, systemic vascular resistances 267 dyne·s·cm<sup>-5</sup> with adrenaline 0.5 µg/kg/min, noradrenaline 1.6 µg/kg/min, dopamine 2 µg/kg/min, methoxamine 5.8 µg/kg/min; urinary output of <15 ml/hour; ventilation in continuous mandatory ventilation (CMV) mode, minute volume 13.4 litres, Fio<sub>2</sub> 1.0, positive end expiratory pressure (PEEP) 10 cm H<sub>2</sub>O to achieve 65% SaO<sub>2</sub>, arterial pH of 7.2, PaO<sub>2</sub> 5.2 kPa, PaCO<sub>2</sub> 8.6 kPa, BE-6, with a calculated intrapulmonary right to left shunt of 66%.

Considering the degree of cardiovascular and respiratory impairment, arteriovenous ECMO was promptly established by percutaneous technique using a centrifugal pump (Bio-Pump, Medtronic Inc, Minneapolis, Minnesota, USA) and a 2.5 m<sup>2</sup> membrane oxygenator (AVECOR Cardiovascular Ltd, Strathclyde, UK). The pump circuit was primed using 1500 ml of Hartmann's solution and the haematocrit was maintained at 30–35% during the ECMO support. Arteriovenous cannulation was obtained via a 21 Fr venous cannula and a 17 Fr arterial cannula (DLP Inc, Grand Rapids, Michigan, USA) in the right femoral vein and right femoral artery, respectively. Two hours later, due to impending ischaemia of the right leg, the arterial cannula was removed and reinserted under direct vision in the left femoral artery, together with a 12 Fr cannula (Polystan A/S, Valrose, Denmark) for distal perfusion of the same limb. In order to treat acute renal failure a continuous arteriovenous haemofiltration device was incorporated in the circuit (this was converted into continuous venovenous haemofiltration after discontinuation of ECMO), and rapid improvement of the haemodynamic and ventilatory parameters was obtained. Extracorporeal flow was adjusted with the aim of maintaining the mixed venous oxygen saturation between 65% and 75% and arterial oxygen saturation at >90%. The gas flow of the oxygenator was regulated to maintain a PaCO<sub>2</sub> of 5–6 kPa. During ECMO mechanical ventilation was maintained at minimal settings, in CMV mode, minute volume 5 litres, PEEP 5 cm H<sub>2</sub>O, Fio<sub>2</sub> 0.3. Intravenous, preservative-free mucous heparin (Pump-Hep, Leo Laboratories Ltd, Princes Risborough, Bucks, UK) was administered at a rate sufficient to maintain the whole blood activated clotting time at 220–250 seconds. During the following 48 hours it was possible to rationalise the antibiotic therapy on the basis of the isolation of an atypical pneumococcus (*Streptococcus pneumoniae*, type 14) sensitive to erythromycin and benzylpenicillin from the tracheal aspirate; urine and sputum were also positive for pneumococcal capsular antigen. Her respiratory state slowly improved so that by the sixth day of ECMO support this was successfully discontinued. She maintained a Pao<sub>2</sub> of 11 kPa and a PaCO<sub>2</sub> of 7.8 kPa while being ventilated in CMV mode, minute volume 8.5 litres, PEEP 6 cm H<sub>2</sub>O, Fio<sub>2</sub> 0.8. Her condition continued to improve and on the 15th day she was extubated. Four days later she was transferred to the renal unit and was discharged home 32 days after the end of support with only minimal changes re-

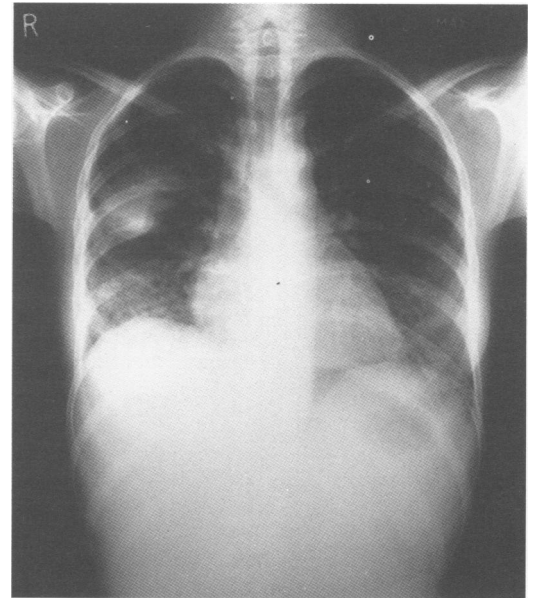


Figure 2 Chest radiograph three weeks later showing only small areas of consolidation in the right upper and lower lobes.

maining on the chest radiograph (fig 2). She remains symptom-free one year later.

### Discussion

Extracorporeal membrane oxygenation in the treatment of adult respiratory failure was virtually abandoned in the United States in 1979 following the publication of disappointing results of the National Institutes of Health (NIH) sponsored multicentre, prospective, randomised trial from 1975 to 1978.<sup>3</sup> These poor results were due to relative inexperience of some of the nine study centres included in the trial, crude coagulation control, the use of venoarterial bypass, and maintenance of the patients on high pressure, high oxygen mechanical ventilation during ECMO.<sup>4</sup> However, continuing efforts by several European centres<sup>5</sup> has led to the revival of adult ECMO, not only in European institutions but also in a few North American centres.<sup>6</sup> The recent experience with adults on ECMO highlights the importance of early intervention in the disease process to achieve a successful outcome.<sup>7</sup> Nevertheless, our patient was moribund with a calculated intrapulmonary left to right shunt of 66% and secondary pump failure. ECMO was offered in desperation as a terminal "rescue attempt". Venoarterial mode of support was selected despite the recent suggestion favouring a venovenous route in a similar situation.<sup>8</sup> This was due to the extreme type of pathophysiology and to provide better support for the myocardial function. Venovenous access maintains normal pulmonary blood flow in the peripheral lung capillaries, which might thrombose under conditions of low blood flow during venoarterial access. Moreover, microemboli and other embolic material that inevitably form during extracorporeal circulation are filtered through the pulmonary capillary bed during venovenous bypass; during venoarterial bypass, they are perfused directly into the systemic capillary bed

with potential for multiorgan dysfunction. We feel that these potential problems with a veno-arterial circuit can be minimised by maintaining high levels of systemic anticoagulation. The dose of heparin was adjusted to maintain an activated clotting time of 220–250 seconds. Despite this, there were no haematological or bleeding complications in this patient. Heparin-coated circuits and heparin-coated hollow fibre membrane oxygenators have been used for ECMO support.<sup>9</sup> However, the impact of heparin-bonded circuits and heparin-bonded silicone membrane oxygenators (when they become available) on the adult ECMO remains to be determined.

The only ECMO-related complication in our patient was impending ischaemic damage to the limb supplied by the cannulated femoral artery. This was obviated by perfusing the distal femoral artery. For a venoarterial mode of ECMO our protocol now includes distal femoral artery perfusion and cannulation of the femoral artery and vein on different sides. The ventilatory settings whilst on ECMO also make important contributions to the overall outcome, as it is imperative to rest the damaged lung.<sup>5</sup> During the first few days of ECMO support we kept mechanical ventilation to a minimum in order to avoid further lung injury.

We believe that extracorporeal life support techniques should be considered in rapidly progressing acute respiratory failure where (1) diagnosis has not been established but is realistically available within a short time, (2) there is a potentially treatable aetiology, (3) no comorbid disease likely to adversely affect the outcome is present, and (4) expertise in extracorporeal techniques is available.

- 1 Feldman C, Kallenbach JM, Reinach SG, Hurwitz MD, Thorburn JR, Koornhof HJ. Community-acquired pneumonia of diverse aetiology: prognostic features in patients admitted to an intensive care unit and a "severity of illness" score. *Intensive Care Med* 1989;15:302–7.
- 2 MacFarlane JT. Acute infection of lower respiratory tract. In: Weatherall DJ, Ledingham JGG, Warrell DA, eds. *Oxford textbook of medicine*. Vol. 15. 2nd edn. New York: Oxford Medical Publications, 1987:91–100.
- 3 Zapol WM, Snider MT, Hill JD. Extracorporeal membrane oxygenation in severe acute respiratory failure. A randomized prospective study. *JAMA* 1979;242:2193.
- 4 NHLBI-NIH. *Extracorporeal support for respiratory insufficiency*. Bethesda, MD: DHEW Publication. 1980.
- 5 Gattinoni L, Pesenti A, Mascheroni D. Low-frequency positive pressure ventilation with extracorporeal CO<sub>2</sub> removal in severe acute respiratory failure. *JAMA* 1986;256:881–5.
- 6 Anderson HL III, Delius RE, Sinard JM, McCurry KR, Shanley CJ, Chapman RA, et al. Early experience with adult extracorporeal membrane oxygenation in the modern era. *Ann Thorac Surg* 1992;53:553–63.
- 7 Bosken C, Lenfant C. Extracorporeal membrane oxygenation revisited . . . again. *Ann Thorac Surg* 1992;53:551–2.
- 8 Sinard JM, Bartlett RH. Extracorporeal life support in critical care medicine. *J Crit Care* 1990;5:265–78.
- 9 Aranki SF, Adams DH, Rizzo RJ, Couper GS, DeCamp MM, Fitzgerald DJ, et al. Femoral veno-arterial extracorporeal life support with minimal or no heparin. *Ann Thorac Surg* 1993;56:149–55.

*Thorax* 1995;50:1319–1321

## Recombinant human DNase in management of lobar atelectasis due to retained secretions

Bsher A Touleimat, Craig S Conoscenti, Jonathan M Fine

### Abstract

**Recombinant human deoxyribonuclease (rhDNase) is an agent which reduces the viscoelasticity of purulent sputum. Two cases are reported in which rhDNase was utilised for the management of lobar atelectasis due to retained purulent secretions.**

(*Thorax* 1995;50:1319–1321)

**Keywords:** atelectasis, sputum, recombinant human DNase.

Abundant purulent airway secretions with resultant plugging is a common clinical problem. Conditions associated with mucus plugging include cystic fibrosis, bronchiectasis, and ineffective cough due to neuromuscular weakness. The viscoelastic properties of these pur-

ulent secretions are due primarily to the presence of highly polymerised, polyanionic deoxyribonucleic acid (DNA), often as extracellular fibrils.<sup>1</sup> The major source of this DNA are the nuclei of degenerating polymorphonuclear leucocytes.<sup>2</sup>

Recombinant human deoxyribonuclease (rhDNase) hydrolyses DNA and has been shown to decrease in vitro the viscoelasticity of sputum from patients with cystic fibrosis.<sup>3</sup> In one study the inhalation of nebulised rhDNase for six days in patients with cystic fibrosis resulted in a 10–20% improvement in forced expiratory volume in one second (FEV<sub>1</sub>) and forced vital capacity (FVC) compared with placebo.<sup>4</sup> In a recent long term study of patients with cystic fibrosis, daily rhDNase administration resulted in a mean improvement in FEV<sub>1</sub> of nearly 6%.<sup>5</sup>

Given these encouraging results, we have used rhDNase to clear obstructing sputum in two patients with atelectasis who failed to respond to conventional therapy.

### Case 1

A 33 year old man with quadriplegia was admitted with fever, chills, and cough. On physical examination he had a respiratory rate of 24/min and a temperature of 38°C. Chest examination revealed decreased breath sounds. The cardiovascular system, abdomen, and extremities were normal. The admission chest

Section of Pulmonary and Critical Care Medicine, Norwalk Hospital, Norwalk, Connecticut 06856, USA

B A Touleimat  
C S Conoscenti  
J M Fine

Reprint requests to:  
Dr J M Fine.

Received 22 September 1994  
Returned to authors 14 December 1994  
Revised version received 24 January 1995  
Accepted for publication 26 January 1995