

## Case reports

A commentary on the following four case reports appears on page 100.

### Pulmonary endocrine cells in plexogenic pulmonary arteriopathy associated with cirrhosis

J R Gosney, M Rešl

#### Abstract

**A clear association has been described between numbers of pulmonary endocrine cells and the migration and/or proliferation of myofibroblasts which is thought to underlie the vascular changes seen in plexogenic pulmonary arteriopathy due to cardiac shunts and primary pulmonary hypertension. In contrast, the pulmonary endocrine system in a subject with florid pulmonary plexogenic arteriopathy associated with cirrhosis was entirely normal, suggesting possible differences in its pathogenesis.**

(Thorax 1995;50:92-93)

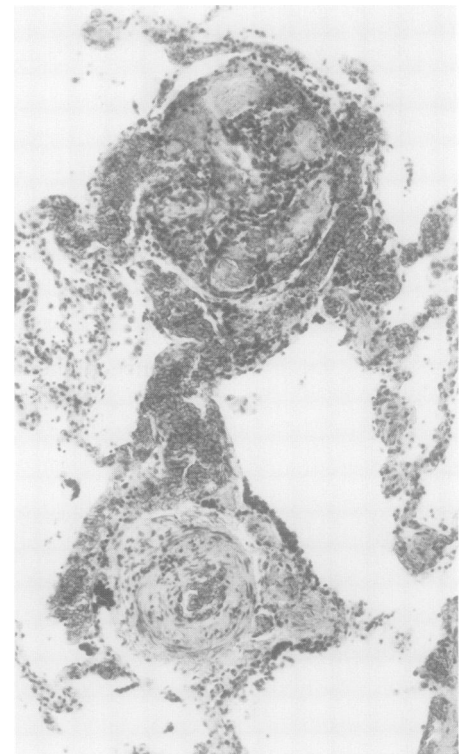
**Keywords:** pulmonary endocrine cells, plexogenic pulmonary arteriopathy, cirrhosis.

Plexogenic pulmonary arteriopathy is a form of hypertensive pulmonary vascular disease characterised by a histopathological triad: plexiform lesions, concentric laminar intimal fibrosis, and fibrinoid vasculosis.<sup>1</sup> It occurs in three groups of patients – those in whom it develops without apparent cause when it is known as primary pulmonary hypertension, those with cardiac shunts through which blood is forced from the systemic into the pulmonary circulations, and those in whom it arises as a rare complication of cirrhosis or portal venous thrombosis. In the lungs of patients in the first two groups there is a clear relation between the activity of plexogenic pulmonary arteriopathy and numbers of pulmonary endocrine cells, particularly those containing gastrin releasing peptide.<sup>2</sup> The case described here is the first in which we have had the opportunity to examine the pulmonary endocrine system in lungs affected by plexogenic pulmonary arteriopathy due to cirrhosis.

#### Case report

A 44 year old woman with longstanding cirrhosis complicated by portal venous thrombosis

and portal hypertension died of ruptured oesophageal varices. She bore all the usual clinical stigmata of chronic liver failure, although the cause of her cirrhosis was unknown. There was, however, no evidence that it had an autoimmune basis. There was no suggestion clinically during life that she had developed pulmonary hypertension; arterial blood gas tensions and pulmonary vascular pressures had not been measured. The cause of death and underlying pathology were confirmed by necropsy when the liver showed advanced micronodular cirrhosis without specific features and the heart, great vessels, and lungs were macroscopically normal. When the lungs were examined histologically, however, there was modest muscular hypertrophy of muscular pulmonary arteries and muscularisation of arterioles, but florid plexogenic pulmonary arteriopathy with widespread laminar intimal fibrosis and numerous plexiform lesions at various stages of development (fig 1). There was no evidence of pulmonary thromboembolism nor of fibrosis. The pulmonary endocrine system was studied by immunolabelling with the avidin-biotin complex method sections from 12 blocks of tissue, six from each lung, for protein gene product (PGP) 9-5 which is a general marker of pulmonary endocrine cells, and for their major secretory products in man<sup>3</sup>:



**Figure 1** Small muscular pulmonary artery showing active intimal proliferation (bottom) adjacent to a still developing plexiform lesion (top). Both involve migration and proliferation of vascular myofibroblasts. Stain: haematoxylin and eosin; magnification  $\times 150$ .

Department of Pathology, University of Liverpool, Liverpool  
J R Gosney

Faculty Hospital, Hradec Kralove, Czech Republic  
M Rešl

Reprint requests to:  
Dr J R Gosney, University Department of Pathology, Royal Liverpool University Hospital, Liverpool L69 3BX, UK.

Received 29 July 1993  
Returned to authors 3 September 1993  
Revised version received 1 December 1993  
Accepted for publication 6 December 1993

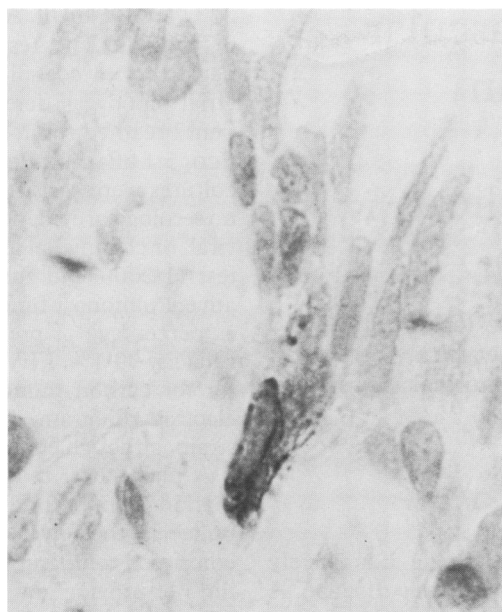


Figure 2 Typical pulmonary endocrine cell deeply buried within the epithelium of an intrapulmonary bronchus. These were entirely normal in morphology, number, distribution and content. ABC method for PGP 9.5; magnification  $\times 1000$ .

gastrin releasing peptide, calcitonin, calcitonin gene-related peptide, and serotonin. Three similarly sampled and studied pairs of lungs from age matched subjects (41, 42, and 48 years), free from cardiopulmonary or hepatic disease, were used as controls. The pulmonary endocrine system in the patient with cirrhosis was entirely normal in its morphology, content, and distribution<sup>3</sup> with 3.1 cells per 10 000 epithelial cells (2.7, 3.24, and 2.57 in controls), 63% of which contained gastrin releasing peptide (60%, 64%, and 65% in controls), with most of the remainder containing calcitonin (fig 2).

### Discussion

The pathogenesis of the plexogenic pulmonary arteriopathy which develops in occasional subjects with cirrhosis or portal venous hypertension is unknown.<sup>4</sup> It may be caused by a humoral agent present at an increased concentration or in an abnormal form as a consequence of hepatic dysfunction rather than a direct effect of disturbed haemodynamics, although the agent or agents which might be responsible are unknown.

Previous studies of patients with plexogenic pulmonary arteriopathy due to cardiac shunts

or primary pulmonary hypertension have shown a striking association between the activity of the process, specifically the migration and/or proliferation of vascular myofibroblasts which is a central feature of its pathogenesis,<sup>5</sup> and numbers of pulmonary endocrine cells, particularly those containing gastrin releasing peptide.<sup>2</sup> In patients with plexogenic pulmonary arteriopathy due to conditions like this there may be more than 100 pulmonary endocrine cells per 10 000 epithelial cells, a concentration more than 30 times as great as that in the subject described here. Since gastrin releasing peptide is known to be trophic to fibroblasts in culture,<sup>6</sup> this and possibly other products of pulmonary endocrine cells may have a stimulatory influence on pulmonary vascular myofibroblasts. Although the plexogenic pulmonary arteriopathy in the patient reported here was widespread and active with numerous plexiform lesions and vigorous activity of myofibroblasts, there was nothing to suggest that pulmonary endocrine cells and their products were in any way involved.

If the products of pulmonary endocrine cells are not a factor in the pathogenesis of plexogenic pulmonary arteriopathy when it develops in cirrhosis, what other humoral agents might be responsible? One possible mediator of the effect is endothelin-1, a potent pulmonary vasoconstrictor with powerful mitogenic properties which has recently been found in large amounts in the pulmonary endothelium of subjects with pulmonary hypertension and plexogenic pulmonary arteriopathy,<sup>7</sup> but we have not had the opportunity to investigate this peptide in the case described here.

This report suggests that there might be differences between the pathogenesis of plexogenic pulmonary arteriopathy when it complicates cirrhosis, and that when it develops under other circumstances.

- 1 Hatano S, Strasser T, eds. *Primary pulmonary hypertension*. Geneva: World Health Organization, 1975.
- 2 Gosney J, Heath D, Smith P, Harris P, Yacoub M. Pulmonary endocrine cells in pulmonary arterial disease. *Arch Pathol Lab Med* 1989;113:337-41.
- 3 Gosney JR. *Pulmonary endocrine pathology: endocrine cells and endocrine tumours of the lung*. Oxford: Butterworth-Heinemann, 1992.
- 4 Matsubara O, Nakamura T, Uehara T, Kasuga T. Histochemical investigation of the pulmonary artery in severe hepatic disease. *J Pathol* 1984;143:31-7.
- 5 Smith P, Heath D, Yacoub M, Madden B, Caslin A, Gosney J. The ultrastructure of plexogenic pulmonary arteriopathy. *J Pathol* 1990;160:111-21.
- 6 Rozenfurt E, Sinnott-Smith J. Bombesin stimulation of DNA synthesis and cell division in cultures of Swiss 3T3 cells. *Proc Natl Acad Sci USA* 1983;80:2936-40.
- 7 Giaid A, Yanagisawa M, Langleben D, Michel RP, Levy R, Shennib H, et al. Expression of endothelin-1 in the lungs of patients with pulmonary hypertension. *N Engl J Med* 1993;328:1732-9.