

## LETTERS TO THE EDITOR

### Improvement in sodium cromoglycate delivery from a spacer device

The study by Dr O'Callaghan *et al* (June 1993;48:603-6) is an interesting attempt to study some of the variables affecting drug delivery from holding chambers. Such studies are essential if we are to use these devices optimally, and it could be argued that it is unethical to proceed to radioisotope deposition studies without such basic data. It would, however, be wrong to make general recommendations based on a single study, particularly as previous studies assessing various chambers have shown that a number of factors, including chamber volume and valve design, can alter the dose delivered from a chamber.<sup>1,2</sup> Among other variables, this study attempts indirectly to assess the possible effect of static on the dose available from a holding chamber by using an "antistatic" spray. It should be noted, however, that the dose <5 µm available at one second with this spray is very similar to previously published results with a large volume chamber in which an antistatic spray was not used,<sup>1</sup> and the dose in particles <5 µm available at 20 seconds in this study when using the spray is very similar to the dose obtained in the previous study at 30 seconds without a spray.

The half life of the aerosol in the previous study was in the region of 15-20 seconds, which is significantly greater than that obtained in this study with the spray. Inspection of images produced with labelled aerosols would also suggest that impaction, influenced by gravity, is the principal cause of drug loss in large volume spacers.<sup>3</sup>

Similarly, the results with multiple actuations differ in magnitude from previously reported results. In a previous study<sup>1</sup> the "respirable" dose delivered per actuation when using four actuations in a large volume chamber was reduced, but only to that delivered from a metered dose inhaler alone, suggesting that, for certain chambers, two actuations can be used with little effect on efficiency.

It is possible that these discrepancies are due to the choice of chamber or formulation of metered dose inhaler, although my previous unpublished work suggests that the Fisonair performs at least as well as the other large volume spacers available. The formulation of the metered dose inhaler used delivers a relatively high dose and hence generates a denser aerosol than will be the case for most therapeutic metered dose inhalers; this may be relevant to the results. Alternatively, some other unrecognised factor may be influencing these results. Preliminary results with an electrometer suggest that variable static charge can be induced on a chamber by the way in which it is handled, but the relevance of this to clinical practice needs to be determined. Reviewing the available evidence, further work is required to clarify these and other related issues.

MARK L EVERARD  
Princess Margaret Hospital for Children,  
Perth,  
Western Australia 6001

- 1 Clark AR. In-vitro assessment of spacer and reservoir devices. In: Dalby RN, Evans RM. *Respiratory drug delivery II*. Lexington: University of Kentucky, 1992:470-82.
- 2 Everard ML, Clark AR, Milner AD. Drug delivery from holding chambers with attached facemask. *Arch Dis Child* 1992;67:580-5.
- 3 Newman SP, Millar AB, Lennard-Jones TR, Moren F, Clarke SW. Improvement of pressurised deposition with Nebuhaler spacer device. *Thorax* 1984;39:935-42.

**AUTHOR'S REPLY** I strongly agree that studies of drug delivery from spacer devices are essential to optimise therapeutic effect, and that it may be unethical to proceed to radioisotope deposition studies without such basic data.

Delivery devices vary dramatically, as do drug formulations. We are in the process of analysing a large number of inhalational devices and drug formulations. Experiments have shown that static charge on spacers does, in fact, change considerably under the influence of several factors. It is therefore important to state whether a new or old spacer device is used, and the exact conditions of use in laboratory and clinical studies involving spacer devices.

Our recent work suggests that the Fisonair does perform at least as well as other large volume spacers, and our results are comparable to those obtained by Fisons in their laboratory in Loughborough (Dr A Clark, personal communication). We therefore feel that the increase in drug available for inhalation following the use of an antistatic agent in a new spacer is a real finding.

Multiple actuations into a spacer device should be avoided when using the Fisonair spacer with Intal, as recommended by the manufacturer. Subsequent work on Tilade endorses this finding.

Further work is certainly required to optimise drug delivery from spacer devices.

C O'CALLAGHAN  
Leicester Royal Infirmary,  
PO Box 65,  
Leicester LE2 7LX,  
UK

### Photodynamic therapy for treatment of bronchial carcinomas

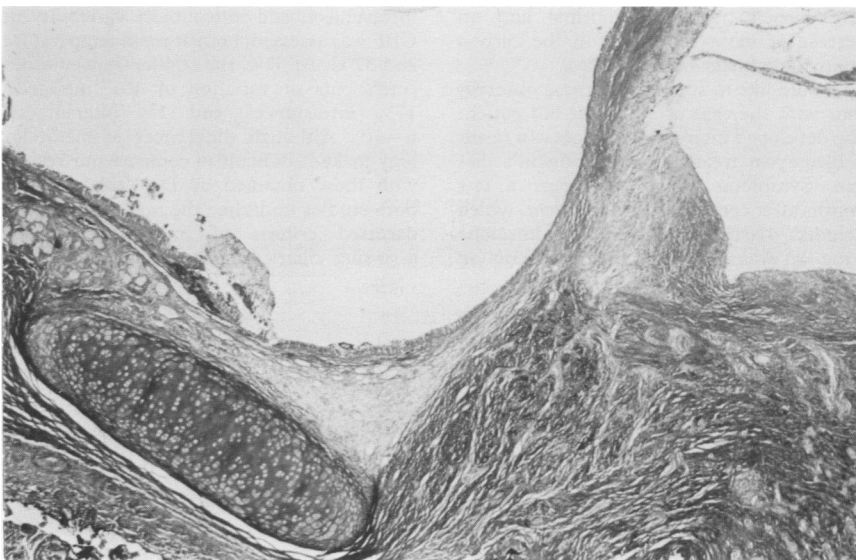
We were interested to read the paper by Dr S G T Smith and coworkers (May 1993;48:474-80) in which the authors describe the effects of photodynamic therapy (PDT) on the tissue of the normal trachea in rats. The authors state that PDT has no effect on cartilage in the presence of granulation tissue. By two months the histology of the rat's trachea returned to normal.

Recently we had the opportunity to study the effect of PDT in human material.<sup>1</sup> A patient presented with shortness of breath caused by a tumour at the orifice of the right main bronchus. Histological investigation revealed typical bronchial carcinoid. After NdYAG laser treatment viable tumour tissue was still present in the dorsal wall of the right main bronchus. PDT was given to treat the residual tumour. After nine months follow up no tumour recurrence was seen, but the right main stem bronchus gradually developed a stenosis necessitating bronchoscopic dilatation. During one of these procedures a perforation of the dorsal wall of the right main bronchus occurred. A sleeve lobectomy was performed immediately afterwards.

In the resected specimen no residual tumour was seen. Bronchial cartilage and epithelium were intact, with fibrosis in the resected specimen of the bronchial ring between the cartilage tissue (figure).

Our histological finding confirms the data reported by Smith in rats. This observation is important, especially if any bronchoscopic therapy is attempted to improve resectability, or in cases with operable tumours in which too much damage to normal tissue may compromise any additional surgery.<sup>2,3</sup>

G SUTEDJA  
R RISSE  
J C VAN MOURIK  
P E POSTMUS  
Free University Hospital Amsterdam,  
PO Box 7057,  
1000 MB Amsterdam,  
The Netherlands



Histology of the right main bronchus after sleeve lobectomy.