

Pleural mesothelioma associated with non-Hodgkin's lymphoma

Maurizio Tondini, Gaetano Rocco, Mario Travaglini, Gerolamo Rossi, Alfonsina Buscemi, Lina de Fazio

Abstract

Occupational exposure to asbestos has been associated with an increased incidence of lung and gastric cancers, mesotheliomas, and myelolymphoid malignancies. A new observation of a patient with indirect exposure to asbestos who developed mesothelioma and plasmacytoid lymphocytic non-Hodgkin's lymphoma is described. This report and the previously described stimulation of B lymphocytes by asbestos suggests that the association of mesothelioma with lymphoid and plasma cell malignancies is not merely a coincidence.

(Thorax 1994;49:1269-1270)

Occupational exposure to asbestos has been increasingly associated with B cell neoplasms such as leukaemias, multiple myelomas, and non-Hodgkin's lymphomas, the latter being observed mostly in the stomach and the oral cavity.^{1,2} However, the association between these tumours and mesothelioma is rarely described. To date only five cases of such an association have been reported, the mesothelioma being associated with multiple myeloma,^{3,4} multicentric reticulohistiocytosis,⁵ chronic lymphatic leukaemia, and poorly differentiated lymphocytic lymphoma.⁶

We report a further patient who had occupational exposure to asbestos and presented with mesothelioma and associated plasmacytoid lymphocytic non-Hodgkin's lymphoma.

Case report

A 58 year old previously healthy man was referred with clinical and radiographic evidence of a left pleural effusion in August 1991. He had a smoking history of 10 cigarettes a day. In

addition he had a 30-year history of professional exposure to asbestos-containing insulating materials. On examination no enlarged lymph nodes nor hepatosplenomegaly was found. The erythrocyte sedimentation rate was 120 mm/h. Serum immunophoresis showed a monoclonal IgMK peak with IgM of 37.7 g/l. A diagnostic thoracentesis yielded 650 ml of a straw-coloured fluid which was negative for rheumatoid factor, Gram stain and acid-fast bacilli, and neoplastic cells. The lactate dehydrogenase (LDH) level was 1700 IU/l.

A computed tomographic scan of the chest showed an irregular pleural margin in the left axillary area, but no enlarged mediastinal nodes nor pulmonary lesions. Bronchoscopic examination was negative, and analysis of the bronchoalveolar lavage fluid yielded 200 000 cells/mm³ with 87% macrophages, 12.5% lymphocytes, 0.5% neutrophils. The results of flow cytometric analysis of lymphocyte surface antigens, both in the bronchoalveolar lavage fluid and the blood, are shown in the table. Some asbestos fibres, but no neoplastic cells, were detected. Repeated cytological examination of the sputum showed no evidence of malignancy.

Based on these findings, a left thoracoscopy was performed, yielding one litre of sero-sanguineous fluid. Disseminated nodules were seen on the parietal pleural surfaces. A biopsy specimen yielded an epithelial malignant mesothelioma (fig 1), with negative staining for CEA, Leu-M1, B 72.3, and SP₁ (pregnancy specific β_1 glycoprotein). The presence of a concurrent plasmacytoid lymphocytic non-Hodgkin's lymphoma was confirmed by a bone marrow biopsy from the iliac spine. The tumour was of low grade malignancy and infiltrated up to 70% of the bone marrow (fig 2). An abdominal ultrasound examination and a gastroscopy were negative for infiltration or other malignancies.

The patient commenced a daily regimen of 5 mg chlorambucil and 25 mg prednisone. A dose of 18 000 000 IU β -interferon was injected in the pleural space. After one month the monoclonal peak decreased but the pleural effusion continued to recur and chest radiography showed pleural nodularity and thickening. Intrapleural cisplatin (20 mg) was then administered with some regression of both the effusion and the pleural nodules. In December 1991 a firm subcutaneous lump located at the thoracoscopic site was noted.

In March 1992 the patient developed multiple osteolytic areas in the ribs and the right femur and worsening general condition, and he died in April 1992 without visible nodal or parenchymal organ involvement. A post mortem examination was not performed.

Discussion

The association of pleural mesothelioma and non-Hodgkin's lymphoma may be explained by immunological abnormalities occurring in patients exposed to asbestos who have presented with or without radiological evidence of pleural or pulmonary lesions. These ab-

Department of Respiratory Diseases

M Tondini
G Rocco
M Travaglini
G Rossi
A Buscemi

Service of Hematology

L de Fazio

"E. Morelli" Regional Hospital, Sondalo (Sondrio), Italy

Reprint requests to:
Dr G Rocco, Via Agricoltura
20, 23037 Tirano (Sondrio),
Italy.

Received 10 September
1993

Returned to authors
5 November 1993

Revised version received

1 February 1994

Accepted for publication

7 February 1994

Flow cytometric analysis of lymphocyte antigens in the bronchoalveolar lavage (BAL) fluid and the blood

	BAL fluid (%)	Blood (%)	Normal range (%)
CD 3+	88.1	94	63-84
CD 4+	47.2	67.7	34-58
CD 8+	42.9	21.1	18-39
CD 16+ (NK)	5	2.2	5-22
CD 20+	—	1.3	5-12
HLA-DR	64.1	55.5	4-19
CD4/CD8	1.1	3.2	

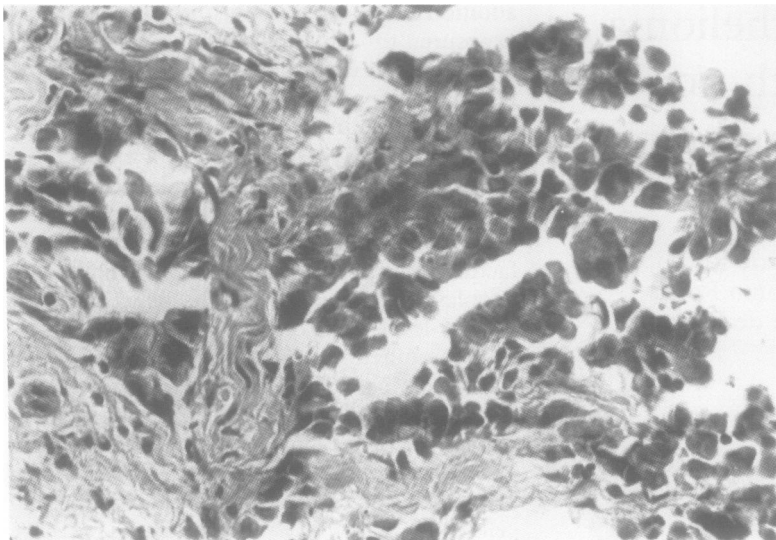


Figure 1 Tubulopapillary pattern of growth of epithelial diffuse malignant mesothelioma. Stain: haematoxylin and eosin, original magnification $\times 250$ reduced to 85% in origination.

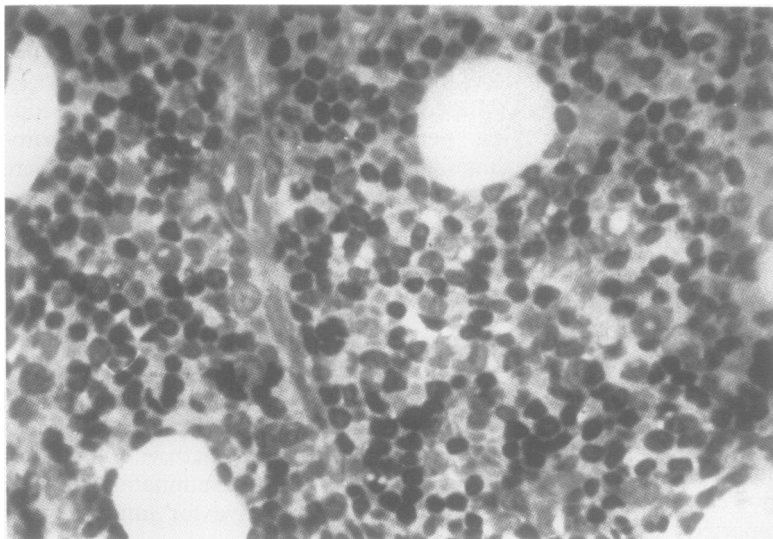


Figure 2 Bone marrow specimen showing neoplastic infiltration by lymphoid and plasma cells. Stain: May-Grunwald-Giemsa, original magnification $\times 250$ reduced to 80% in origination.

normalities are thought to result from an intense stimulation of the humoral immune response and the B lymphocytes – that is, raised immunoglobulin and C3 levels, occasional appearance of non-organ specific autoantibodies, rheumatoid factor, and circulating immunocomplexes.⁷ In addition, other studies have reported a decreased total number of circulating T lymphocytes resulting in a compromised delayed hypersensitivity.⁸

An association between lymphoid and plasma cell malignancies has been noted in patients with asbestos-related pleural and pulmonary disease.¹⁻⁶ An explanation for this is that inhaled asbestos fibres are transported via

the lymphatics and the bloodstream to the various organs. This view is supported by the detection of asbestos fibres in the bone marrow of patients with acute leukaemia.⁹

Asbestos is believed to be responsible for the intense stimulation of B lymphocytes which, in turn, may result in: (1) lymphoid or plasma cell hyperplasia leading, on occasion, to cancer; and (2) decreased T lymphocyte activity which may also favour the development of B cell malignancies.^{6,8}

In our patient no radiological evidence of previous exposure to asbestos was seen. However, flow cytometric analysis of the serum showed an increased number of T lymphocytes due to increased CD4, a remarkable immune activation expressed by a high number of HLA-DR cells and a decreased proportion of natural killer (NK) lymphocytes. A high percentage of activated T lymphocytes (HLA-DR+) were also found in the bronchoalveolar lavage fluid.

Although explainable, the association of non-Hodgkin's B cell lymphomas with mesothelioma is rare. Ozesmi and coworkers¹⁰ showed an increased development of mesotheliomas, lymphomas, and the association of mesothelioma and lymphoma in mice receiving an intraperitoneal injection of fibrous zeolite (similar to asbestos) compared with those receiving only talc or saline solution.

Based on the recent literature, the relation between exposure to asbestos and mesothelioma, lung and gastric cancers, and lymphoid B cell neoplasms appears clear. More epidemiological studies are needed to assess the risk of developing lymphoid and plasma cell malignancies in patients with occupational or environmental exposure to asbestos.

The authors thank Dr Alessandro Castello from the Dept. of Surgical Pathology of I.R.C.C.S. San Matteo, Pavia, Italy, for his contribution to this study.

- Ross R, Dworsky R, Nichols P, Paganini-Hill A, Wright W, Koss M, *et al.* Asbestos exposure and lymphomas of the gastrointestinal tract and oral cavity. *Lancet* 1982;ii: 1118-9.
- Schwartz DA, Vaughan TL, Heyer NJ, Koepsell TD, Lyon JL, Swanson GM. B-cell neoplasms and occupational asbestos exposure. *Am J Ind Med* 1988;14:661-71.
- Perry MC, Solinger A, Farhangi M, Luger A. Plasmocytomas and mesothelioma. *Med Pediatr Oncol* 1978;5: 205-12.
- Hayashi Y, Mizuo K, Hayashi K. An autopic case of double cancer of multiple myeloma and malignant mesothelioma. *Nippon Naika Gakkai Zasshi* 1989;78:1611-2.
- Honeybourne D, Kellet JK. A mesothelioma presenting with multicentric reticulohistiocytosis. *Postgrad Med J* 1985;61: 57-9.
- Efremidis AP, Waxman JJ, Chahinian AP. Association of lymphocytic neoplasia and mesothelioma. *Cancer* 1985; 55:1056-9.
- Zerva LV, Constantopoulos SH, Moutsopoulos HM. Humoral immunity alterations after environmental asbestos exposure. *Respiration* 1989;55:237-41.
- Kagan E, Salomon A, Cochrane JC, Kuba P, Rocks PH, Webster I. Immunological studies of patients with asbestosis. I. Studies of cell-mediated immunity. *Clin Exp Immunol* 1977;28:261-7.
- Kishimoto T. Cancer due to asbestos exposure. *Chest* 1992; 101:58-63.
- Ozesmi M, Patiroglu TE, Hillerdal G, Ozesmi C. Peritoneal mesothelioma and malignant lymphoma in mice caused by fibrous zeolite. *Br J Ind Med* 1985;42:746-9.