New techniques *Series editor: P M A Calverley*

Transtracheal oxygen delivery

J Shneerson

Conventional tracheostomies have been used for many years to deliver oxygen with the patient breathing spontaneously or in conjunction with positive pressure ventilators. The insertion of a transtracheal catheter specifically to deliver oxygen, however, dates only from Heimlich's studies published in 1982.[1] He showed that in dogs and man a normal oxygen saturation could be maintained by the delivery of oxygen directly into the trachea. He developed a percutaneous catheter suitable for clinical use, and has subsequently shown that it is satisfactory for long term use and that most patients preferred it to the conventional oxygen delivery systems.[2] The impetus for the refinement of transtracheal catheters came from the opportunities that they give to conserve oxygen and to cut the costs of domiciliary oxygen treatment.

Percutaneous catheters

The Oxycath (Laboratoire Cometh, Lyon), which is used especially in Europe, has a long intratracheal portion with multiple fenestrations.[3] The Scoop catheter (Trans-tracheal Systems, Denver, Colorado) is similar and is widely used in the United States.[4] Both these percutaneous catheters are introduced into the trachea under local anaesthesia. The procedure is usually straightforward, though care has to be taken to avoid thyroid tissue, which is very vascular. The insertion track takes about six weeks to become established and during this period there is a risk that it may be lost if the catheter becomes displaced. With the Scoop catheter a stent is inserted initially into the trachea and replaced after about a week by the catheter. This is subsequently removed twice daily for cleaning (or more frequently if the tracheobronchial secretions are profuse).

Tunnelled catheters

The alternative to the percutaneous approach is to insert a tunnelled transtracheal catheter. Most experience has been gained with the intratracheal oxygen catheter or ITOC (Cook, Critical Care, Bloomington, Wisconsin).[5 6] This is composed of silicone and has a much shorter intratracheal portion than the percutaneous catheters. It is implanted surgically under local or more usually general anaesthesia. A transverse incision is made in the suprasternal notch and the catheter inserted into the trachea. It is stitched to the outer tracheal wall and tunnelled under the skin and over the sternum to an exit point over the upper abdomen (figure). Prophylactic antibiotics are advisable to reduce the risk of postoperative infections along the catheter track. Once in use the catheter is flushed with 2 ml of normal saline twice daily to maintain its patency.

Problems with transtracheal catheters

Transtracheal catheters require an initial insertion procedure and are more complex for the patient to use than the conventional face masks and nasal cannulas. The implantation of the tunnelled catheter is a more extensive procedure than that needed for the percutaneous catheters, but the subsequent maintenance is easier for the patient. Care has to be taken with the percutaneous catheters to prevent loss of the track into the trachea during the first few weeks after insertion. The track

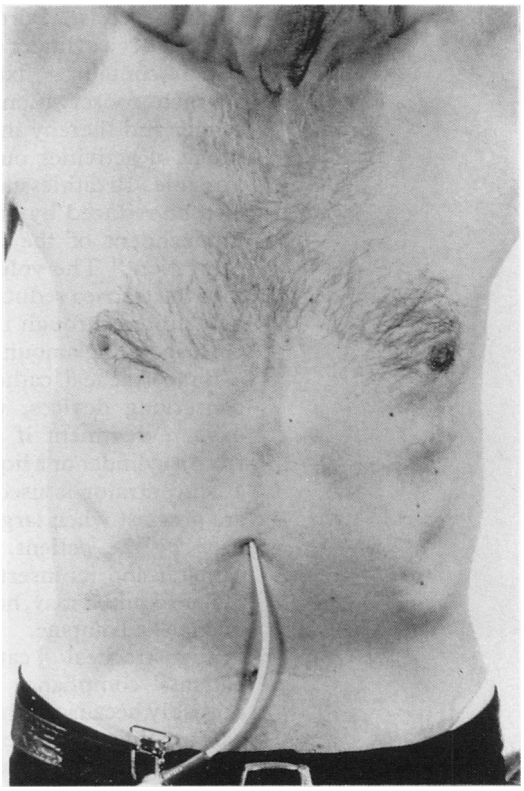

Tunnelled intratracheal oxygen catheter showing the exit point over the upper abdomen (From Jackson et al,[6] reproduced by courtesy of the British Medical Journal.)

Newmarket General Hospital, Newmarket, Suffolk CB8 7JG
J Shneerson

Reprint requests to:
Dr Shneerson

may become infected with either type of catheter and occasionally they are displaced or fractured.[7] Mucus plugs may form on the end of the transtracheal catheters and occasionally cause tracheal obstruction requiring bronchoscopy.[8] Mucolytics have been used to try to prevent this complication, but the response is variable. Haemorrhage and surgical emphysema are rarely severe enough to be clinically important.

Advantages of transtracheal catheters

Why then should transtracheal catheters be considered if they have these disadvantages?

Firstly, they are cosmetically superior to face masks and nasal cannulas. This is particularly so with the tunnelled catheters, which are completely concealed apart from the exit site over the abdomen. The percutaneous catheters protrude from the skin overlying the trachea, but are less obvious than the conventional alternatives. Transtracheal catheters are also more comfortable to use than face masks and nasal cannulas.

Transtracheal catheters reduce the volume of oxygen required by the patient. Most of the studies with both the percutaneous and the tunnelled types of catheter have shown oxygen requirements to be reduced by around half, both at rest and during exercise.[4 9 10] None of the oxygen is lost around the face and less of the dead space in the upper airway is wastefully oxygenated. Oxygen requirements are also reduced because the oxygen delivered into the trachea during expiration is available during early inspiration, when inspiratory flow is greatest.

The value of oxygen conservation is greatest during exercise. Portable oxygen is supplied from either a cylinder or a liquid source, both of which contain a fixed quantity of oxygen. Oxygen conservation makes the supply last longer and thereby increases the mobility and range of activities outside the home that are possible. Breathlessness during exercise may also be reduced by an additional mechanism, independent of the improvement in oxygen saturation.[11] The volume of oxygen delivered into the trachea reduces the volume that has to be inspired through the mouth and nose by a corresponding amount.[12]

Transtracheal catheters, like other oxygen conserving devices, will reduce the cost of oxygen treatment if the oxygen is delivered from a cylinder or a liquid source, but not when a concentrator is used. The potential savings are greatest when large volumes of oxygen are used by the patient. The initial cost of the catheter and its insertion and the supervision that is required may, however, largely offset this financial advantage.

Transtracheal catheters improve the patients' compliance with oxygen treatment, probably because of their cosmetic benefits and because they are more comfortable to use. The length of time each day that patients receiving long term oxygen treatment are well oxygenated can be increased, particularly when they spend a considerable time outside their homes. The catheters are also useful in this group of subjects in two specific circumstances. The first is when such high flow rates of oxygen are needed that adequate oxygen saturations cannot be maintained with nasal cannulas or face masks without troublesome drying of the upper airway. Transtracheal catheters overcome this difficulty both because they bypass the upper airway and because they need lower flow rates to achieve an equivalent oxygen saturation.[13] Secondly, they enable more precise control and more stable delivery of the desired inspiratory oxygen flow rate. This may be essential if carbon dioxide retention during oxygen treatment is a hazard for the patient and if ventilatory assistance is to be avoided.

Indications for transtracheal catheters

Although transtracheal catheters may be indicated to facilitate long term oxygen treatment they are more usually indicated when a portable system is being considered. This immediately poses two problems: how to assess who would benefit from portable oxygen and whether transtracheal catheters would be better than the alternative oxygen delivery devices for the individual patient. Investigation of the benefit obtained from portable oxygen treatment requires repeated exercise tests with the patient unaware of whether he is receiving air or oxygen and what the flow rate is. Careful questioning is needed to assess how much the patient values the extra mobility that a portable system might provide. The alternative oxygen conserving devices (reservoir nasal cannulas and inspiratory phased oxygen devices) do not require the same degree of cooperation from the patient, but they have their own drawbacks. Reservoir nasal cannulas, for instance, are very conspicuous and may fail if the expiratory time is short or inspiratory flow rates very high, as may readily occur during exercise. The inspiratory phased delivery systems may fail if the patient breathes through his mouth or if the respiratory rate is rapid and the tidal volume small. These two devices are nevertheless preferable if oxygen conservation is likely to be needed for only a short period as the need for the insertion of the transtracheal catheter is then avoided. If oxygen conservation is likely to be needed in the long term a transtracheal catheter is often preferable. Patients should, in general, be less than 70 years old, their chronic lung disease should be stable or nearly so, and it should be this rather than, for instance, osteoarthritis of the hip that limits their mobility. There should also be no serious non-respiratory disease, such as malignancy or extensive diabetic complications, which would be likely to limit the usefulness of a transtracheal catheter in the long term.

The present uncertainties about the precise indications for these oxygen conserving techniques, and which one to choose for the individual patient, have largely limited experience with them to specialist centres. Their use and that of transtracheal catheters in particular are, however, likely to increase as the emphasis falls increasingly on improving the quality of life

and mobility of patients with chronic lung diseases and not simply on prolonging a sedentary and homebound existence.

1 Heimlich HJ. Respiratory rehabilitation with transtracheal oxygen system. *Ann Otol Rhinol Laryngol* 1982;**91**:643–7.
2 Heimlich HJ, Carr GC. Transtracheal catheter technique for pulmonary rehabilitation. *Ann Otol Rhinol Laryngol* 1985;**94**:502–4.
3 Artaud M. Transtracheal oxygenotherapy. *Bull Eur Physiopathol Respir* 1986;**22**(suppl 9):34–6S.
4 Christopher KL, Spofford BT, Brannin PK, Petty TL. Transtracheal oxygen therapy for refractory hypoxemia. *JAMA* 1986;**256**:494–7.
5 Johnson LP, Cary JM. The implanted intratracheal oxygen catheter. *Surg Gynecol Obstet* 1987;**165**:74–6.
6 Jackson M, King M, Hockley S, Wells F, Shneerson JM. Early experience with an implantable intratracheal oxygen catheter. *BMJ* 1990;**300**:909–10.
7 Walsh DA, Govan JR. Long term continuous domiciliary oxygen therapy by transtracheal catheter. *Thorax* 1990; **45**:478–81.
8 Christopher KL. Spofford BT, Petrun MD, McCarty DC, Goodman JR, Petty TL. A program for transtracheal oxygen delivery. *Ann Intern Med* 1987;**107**:802–8.
9 Banner NR, Govan JR. Longterm transtracheal oxygen delivery through microcatheter in patients with hypoxaemia due to chronic obstructive airways disease. *BMJ* 1986;**293**:111–4.
10 Hoffman LA, Dauber JH, Ferson PF, Openbrier DR, Zullo TG. Patient response to transtracheal oxygen therapy. *Am Rev Respir Dis* 1987;**135**:153–6.
11 Wesmiller SW, Hoffman LA, Sciurba FC, Ferson PF, Johnson JT, Dauber JH. Exercise tolerance during nasal cannula and transtracheal oxygen delivery. *Am Rev Respir Dis* 1990;**141**:789–91.
12 Couser JI Jr, Make BJ. Transtracheal oxygen decreases inspired minute ventilation. *Am Rev Respir Dis* 1989; **139**:627–31.
13 Leger P, Gerard M, Mercatello A, Robert D. Transtracheal catheter for oxygen therapy of patients requiring high oxygen flows [abstract]. *Respiration* 1984;**46**(suppl 1):103.