

AUTHOR'S REPLY Dr Trevisani and colleagues suggest that the routine washings taken at fiberoptic bronchoscopy is not worthwhile in the diagnosis of lung cancer. In his results he cites that seven out of 32 patients (22%) in the group without endoscopic evidence of malignancy (group B) had positive washings when biopsy gave negative results. This would mean that these seven patients would have undergone a further investigation for a diagnosis. Also washings actually gave a higher yield in their group B than did biopsy (59% compared with 53%). They go on to state that post-bronchoscopy sputum may be useful because it gave the only positive result in 10 out of 47 patients (21%), six of whom were in group B, and that this was statistically significant. According to these figures, washings are slightly superior to both post-bronchoscopy sputum and biopsy specimens in terms of percentage yield in group B, and far less time consuming given that 109 sputum samples had to be examined in 47 patients to provide 57 positive results. We believe that these results support our view that washings should be done routinely.

We are not surprised that the improvement in yield with washings does not reach statistical significance because the numbers concerned are small (in fact, the yield from washings reported by Dr Trevisani and colleagues is better than ours). Our point, however, was that for maximum diagnostic yield during bronchoscopy all three procedures should be performed.

The results reported by Dr Semple also show that, even though tumours were seen bronchoscopically, cytology gave the only positive result in a proportion of cases. One of the reasons why our study was initiated was the diversity of cytological techniques being used by different bronchoscopists in the same district who sent samples to the same laboratory. Our aim was to determine the best combination of techniques to produce a standardised protocol throughout the district so that future analysis could be simplified. We would certainly welcome collaboration or comparison with other respiratory units—especially, as Dr Semple suggests, with regard to audit.

VHF MAK
MR HETZEL
IDA JOHNSTON
Lung Function Laboratory,
Rayne Institute,
University College Hospital,
London WC1E 6AU

Transcarinal needle aspiration in the diagnosis of mediastinal adenitis in a patient infected with the human immunodeficiency virus

Dr G J Serda and colleagues report that transcarinal needle aspiration is useful in the diagnosis of tuberculosis in a patient with HIV infection (May 1990;45:414-5). Needle aspiration of cervical lymph nodes has also been found to be useful in the diagnosis of tuberculosis in populations with a high incidence of tuberculosis, with or without³ HIV infection. We have found needle aspiration of cervical lymph nodes to be useful in the diagnosis of tuberculosis in two patients with HIV infection.

A 26 year old male intravenous drug user, known to be infected with HIV, presented with a two week history of cough, fever, and rapidly enlarging bilateral cervical lymphadenopathy. There was no past history of

tuberculosis. His sputum was smear positive for acid fast bacilli. Needle aspiration of 0.1 ml of pus from a cervical lymph node showed acid fast bacilli on the smear and grew *Mycobacterium tuberculosis*.

A 43 year old man presented with a three month history of fever and weight loss. There was extensive cervical, axillary, and paraortic lymphadenopathy. A clinical diagnosis of lymphoma was considered. A cervical lymph node biopsy and aspiration were performed. Smears of the needle aspirate showed acid fast bacilli, identified on culture as *M tuberculosis*. A subsequent test for HIV gave a positive result, though he was not in any high risk group.

In both cases a drop of needle aspirate was used to prepare smears for Ziehl-Nielsen staining and cytological examination. The aspirate was inoculated directly on to Lowenstein-Jensen medium and the syringe and needle were flushed out with Kirschner's medium.

Lymph node aspiration is less invasive for the patient than open lung biopsy and safer for the surgeon. It is a simple and quick investigation which may provide a rapid diagnosis of infection with acid fast bacilli in HIV patients with lymphadenopathy.

CD SHELDON
N C BARNES
D T D HUGHES
Department of Chest Medicine,
Royal London Hospital,
London E1 1BB

- 1 Dominguez A, Pena JM, Gonzalez JJ, et al. The spectrum of lymphadenopathy in HIV-positive patients. Prospective analysis of 45 cases. *Rev Clin Esp* 1989;184:57-60.
- 2 Lau SK, Wei WI, Hsu C, Engzell UCG. Fine needle aspiration biopsy of tuberculous cervical lymphadenopathy. *Aust NZ J Surg* 1988;58:947-50.
- 3 Singh JP, Chaturvedi NK, Das A. Role of fine needle aspiration cytology in the diagnosis of tubercular lymphadenitis. *Indian J Pathol Microbiol* 1989;32:100-4.

AUTHOR'S REPLY We thank Dr Sheldon and colleagues for their interest in our paper. They report the diagnosis of tuberculous infection of cervical lymph nodes by means of percutaneous fine needle aspiration in two patients infected with HIV.

During the last 24 months we have studied 17 patients with tuberculous cervical adenitis. Material from percutaneous fine needle aspiration provided the diagnosis in five patients, none of whom was infected with HIV. Despite this low sensitivity we believe that this procedure is an important first step that may allow a rapid diagnosis in patients with suspected tuberculosis and enlarged peripheral lymphadenopathy. It is important, however, to be aware of the reduced specificity of smears from needle aspirates in children and HIV positive patients, in whom infection of lymph nodes with non-tuberculous mycobacteria is more frequent than in HIV negative adults.^{1,2} A definite diagnosis of tuberculous adenitis is only provided by identification of *M tuberculosis* on culture, and this may take several weeks.

We agree that peripheral lymph node aspiration may overcome the need for a surgical approach in the management of superficial tuberculous lymphadenitis.³

Our report was intended to illustrate the use of a flexible transbronchial needle passed through a fiberoptic bronchoscope to sample deep mediastinal nodes for the diagnosis of

tuberculous adenitis. This removed the need for surgery.

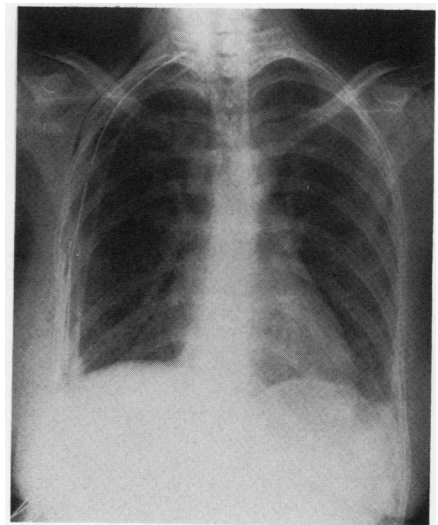
F RODRIGUEZ DE CASTRO
J CAMINERO
G JULIA SERDA
P CABRERA
Sección de Neumología,
Hospital Nuestra Señora del Pino,
35005 Las Palmas GC,
Spain

- 1 Anonymous. Scrofula today [editorial]. *Lancet* 1983;i:335-6.
- 2 American Thoracic Society. Mycobacterioses and the acquired immunodeficiency syndrome. *Am Rev Respir Dis* 1987;136:492-6.
- 3 Campbell IA. The treatment of superficial tuberculous lymphadenitis. *Tubercle* 1990; 71:1-3.

Horner's syndrome occurring as a complication of pleurectomy

There have been six recorded cases of Horner's syndrome following insertion of an intercostal chest drain (the latest having been reported by Campbell and colleagues in *Thorax*¹). I have recently seen a 19 year old woman complaining of a small right pupil and drooping of the right eyelid.

Nine months previously, while 16 weeks' pregnant, she had undergone right parietal pleurectomy under general anaesthesia for recurrent right pneumothorax with the insertion of both apical and basal chest drains. Afterwards she complained of mild drooping of her right eyelid and a small right pupil but was told that this was likely to be due to the anaesthetic. These eye problems persisted after the birth of her baby and she was referred to the neurology clinic. On examination she had a meiotic right pupil that was reactive to light, a very mild ptosis on the right, but no discernible enophthalmos. The diagnosis of Horner's syndrome was made. The postoperative apical chest drain had been placed at the level of the right first rib where the sympathetic chain is separated from the parietal pleura by a thin fascial layer called the endothoracic fascia (figure).² This woman's Horner's syndrome was presumably caused by the apical drain pressing on the sympathetic chain and made more likely by the absence of the cushioning effect of the parietal pleura. We suggest that apical drains should be placed no higher than the third rib



Chest radiograph showing the postoperative apical chest drain at the level of the right first rib.