

# Eosinophilic granuloma of the lung presenting as a solitary pulmonary nodule

Carl J Fichtenbaum, George M Kleinman, Raymond G Haddad

## Abstract

**A symptomless 58 year old man had an eosinophilic granuloma of the lung that presented as a solitary pulmonary nodule rather than the usual diffuse reticulonodular shadow on the chest radiograph. Only one previous case presenting in this way has been described.**

Eosinophilic granuloma of the lung is a variant of histiocytosis X.<sup>1,2</sup> Typically, the granuloma in the lung causes diffuse shadowing on the chest radiograph. Although patients may present with cough or dyspnoea, it is not unusual for them to be symptomless despite having diffuse shadowing on the chest radiograph. We describe a patient with a single small nodule diagnosed as eosinophilic granuloma of the lung by open lung biopsy.

## Case report

A 58 year old white man was admitted for elective repair of bilateral inguinal hernias. His past history was remarkable for heavy ethanol abuse and a 42 pack year history of cigarette smoking. He had a one month history of a dry, non-productive cough. A preoperative chest radiograph showed a 1 cm nodule in the right middle lobe (fig 1), confirmed by computed tomography to be non-calcified and without evidence of other infiltrates or adenopathy. No old chest radiographs were available. Pulmonary function studies showed a normal vital capacity (94% predicted) and mild airflow limitation ( $FEV_1/FVC = 72\%$ ). The patient was referred to a thoracic surgeon, who performed an excisional biopsy of the lesion.

The specimen was a 10 × 7 × 2 cm right middle lobe. Sectioning disclosed an irregular, yellow white nodule (9 × 9 × 3 mm), which microscopically (fig 2) contained numerous large cells with granular eosinophilic cytoplasm, pale convoluted nuclei and occasional small nucleoli. Many eosinophils, plasma cells, lymphocytes, and neutrophils were present. S-100 protein was detected immunohistochemically in the cytoplasm of most of the large cells. Electron microscopy showed Birbeck granules (X bodies) within the cytoplasm of these cells. The pathological diagnosis was eosinophilic granuloma of the lung.

## Discussion

Eosinophilic granuloma is one manifestation of histiocytosis X, a granulomatous disorder affecting the mononuclear phagocytic cell system. Typically patients are cigarette smokers<sup>2</sup> with few complaints. The typical radiographic appearance of eosinophilic granuloma of the lung is a diffuse reticulonodular infiltrate in the middle and upper lung zones, the nodules ranging in size from 2 to 10 mm. Unusual radiographic features include hilar and mediastinal adenopathy, pleural effusions, pneumothorax, and multiple nodules with or without cavitation—and even normal chest radiographs.<sup>3</sup>

Microscopically, multiple infiltrates are seen in the interstitium, sometimes surrounding small bronchioles. The Langerhans cell, which is characteristic of histiocytosis X, has pale eosinophilic cytoplasm and an irregularly folded nucleus that occasionally contains a small nucleolus. These findings may be confused with reactive inflammatory changes of endothelial cells, type II pneumocytes, and alveolar macrophages, though all of these are negative for S-100 protein and they lack the characteristic raquet shaped Birbeck granules of eosinophilic granuloma seen on electron micrographs. Most commonly, eosinophilic granuloma of the lung is mistaken for interstitial pulmonary fibrosis, which often contains Langerhans cells. Rarely it is confused with bronchiolitis obliterans organising pneumonia or malignancy.<sup>2,4-6</sup>

A few cases of eosinophilic granuloma of the lung with multiple nodules on the chest

Department of  
Internal Medicine  
C J Fichtenbaum

Department of  
Pathology  
G M Kleinman

Section of Pulmonary  
Diseases  
R G Haddad

Bridgeport Hospital  
and Yale University,  
School of Medicine,  
Bridgeport,  
Connecticut, USA

Address for correspondence:  
Dr C J Fichtenbaum,  
Department of Medical  
Education, Bridgeport  
Hospital, PO Box 5000,  
Bridgeport, Connecticut  
06610, USA.

Accepted 21 May 1990

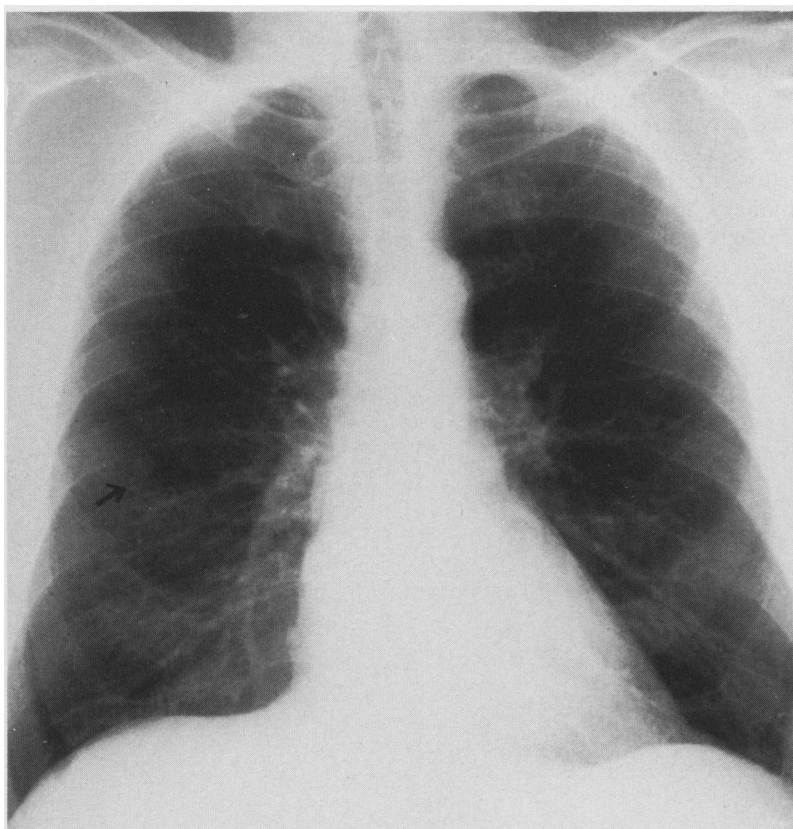
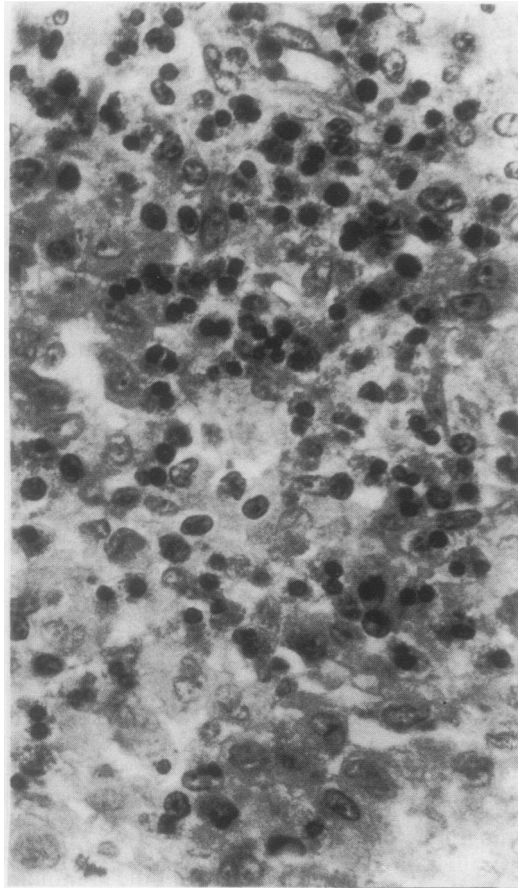


Figure 1 Posteroanterior chest radiograph showing a 1 cm nodule in the right middle lobe (arrow).

Figure 2 Microscopic section of the nodule showing a mixed population of Langerhans cells with irregular pale nuclei, eosinophils, and lymphocytes. (Haematoxylin and eosin.)



radiograph, suggesting malignancy, have been reported, and there is a single report of eosinophilic granuloma of the lung presenting as a solitary nodule.<sup>6</sup>

The pathological differential diagnosis of this nodule includes plasma cell granuloma, pulmonary fibrous histiocytoma, sclerosing haemangioma of the lung, intravascular bronchioalveolar tumour, and eosinophilic granuloma of the lung. Plasma cell granuloma is a localised reactive condition with numerous plasma cells, other inflammatory cells, and fibrosis. Pulmonary fibrous histiocytoma is a circumscribed grey-tan tumour

that may have a variable composition of lymphocytes, plasma cells, histiocytes, and vascular proliferation. Sclerosing haemangioma of the lung is a circumscribed, solid, tan-yellow tumour that may contain areas of old and recent haemorrhage. Microscopically, there are compact polygonal cells with copious eosinophilic cytoplasm in a papillary pattern, sometimes continuous with bronchiolar epithelium. Intravascular bronchoalveolar tumour usually appears as multiple nodules. Microscopically eosinophilic cells surround a mass of hyalinised stroma. Electron microscopy and immunocytochemistry have shown that this tumour is a histiocytoid haemangioendothelioma. Our patient's nodule lacked the characteristics of all these conditions.

In our patient a neoplasm seemed to be the most likely diagnosis given the history of heavy tobacco smoking in a middle aged man, and as this was potentially curable by resection an open procedure was performed.

The aetiology of eosinophilic granuloma of the lung is unknown. Treatment is largely symptomatic. Corticosteroids and chemotherapeutic agents have been tried in uncontrolled studies with variable success. The mortality is 2–6%, with a high rate of spontaneous remission. No further treatment was recommended in our patient because of the absence of symptoms and of disseminated disease. He remained symptom free two years after lobectomy, and a chest radiograph at this time showed no further abnormalities.

- 1 Lichtenstein L. Histiocytosis X: interpretation of eosinophilic granuloma of the bone, Letterer-Siwe disease and Schuller-Christian disease as related manifestations of a single nosologic entity. *Arch Pathol* 1953;56:84–102.
- 2 Marcy TW, Reynolds HY. Pulmonary histiocytosis X. *Lung* 1985;163:129–50.
- 3 Pomeranz SJ, Proto AV. Histiocytosis X, unusual-confusing features of eosinophilic granuloma. *Chest* 1986;89:88–92.
- 4 Friedman PJ, Liebow AA, Sokoloff J. Eosinophilic granuloma of the lung. *Medicine (Baltimore)* 1981;60:385–96.
- 5 Basset F, Corrin B, Spencer H, et al. Pulmonary histiocytosis X. *Am Rev Respir Dis* 1978;118:811–20.
- 6 Hammar SP. Extrinsic allergic alveolitis-pulmonary histiocytosis X. In: Dall DH, Hammar SP, eds. *Pulmonary pathology*. New York: Springer, 1988:392–412.