

## Benign thymic cysts in Hodgkin's disease: report of a case and review of published cases

C R LEWIS, A MANOHARAN

*From the Department of Clinical Haematology, St George Hospital, University of New South Wales, Kogarah, Sydney, Australia*

Mediastinal masses are a frequent finding in patients with Hodgkin's disease, and usually represent either mediastinal lymphadenopathy or a diseased thymus gland.<sup>1</sup> In some rare patients, however, the mediastinal mass may be due to diffuse thymic hyperplasia<sup>2</sup> or benign thymic cysts.<sup>3</sup> In each of the 10 reported cases of thymic cysts in Hodgkin's disease, the diagnosis of the thymic cysts was made either during investigations for persistent mediastinal mass after completion of radiotherapy or chemotherapy or during investigation of the mediastinal mass at "relapse."<sup>3-7</sup> In this report we describe a patient with Hodgkin's disease in whom thymic cysts were diagnosed at presentation; the cysts resolved completely after effective chemotherapy.

### Case report

A 26 year old man presented in August 1984 with a nine month history of swelling of the left side of the neck, associated with alcohol induced pain in the left cervical region, severe night sweats and fevers, and weight loss of 7 kg.

Physical examination showed widespread lymphadenopathy affecting the left cervical, bilateral supraclavicular, and left axillary regions. There was no hepatosplenomegaly or any clinical evidence of superior vena cava obstruction.

Excision biopsy of a left cervical lymph node showed histological features of nodular sclerosing Hodgkin's disease—substantial interconnecting bands of collagenous fibrous tissue surrounding nodules of mixed cellularity with many lacunar cells. An initial chest radiograph showed a massive anterior mediastinal mass (fig 1), and computed tomographic scanning of the thorax showed the mass to have large areas of solid tumour and several loculated cystic areas (fig 2). A fine needle aspiration of one of these cysts yielded serous fluid and, although several large mononuclear cells were seen on microscopic examination, there were no diagnostic Reed-Sternberg cells. There was also no evidence of any underlying tissue necrosis. An abdominal computed tomography scan was normal, as were the results of other staging investigations.

The staging indicated IIB Hodgkin's disease and chemotherapy with MOPP (nitrogen mustard, vincristine, procarbazine, and prednisone) was started. At the completion

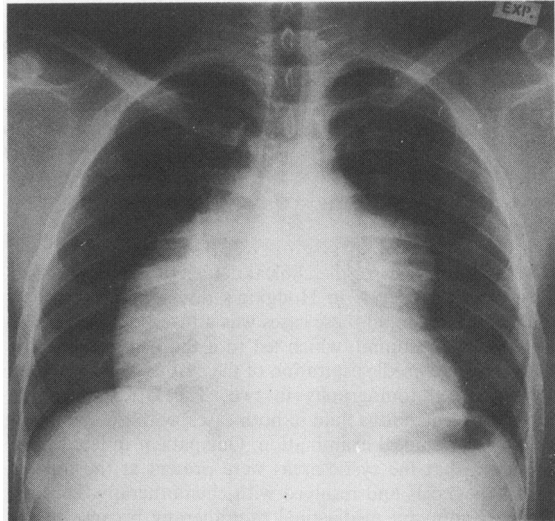


Fig 1 Chest radiograph showing mediastinal mass.

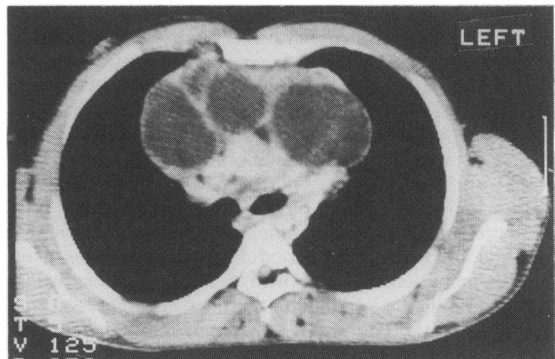


Fig 2 Thoracic computed tomography scan (2.5 cm below the manubriosternal joint) showing areas of tumour and several translucent cystic areas.

of six courses of treatment, there was complete resolution of clinical lymphadenopathy and repeat thoracic computed tomography showed normal appearances. He subsequently received adjuvant radiotherapy to the mediastinal region. Ten months after completion of radiotherapy he remains well and disease free.

Address for reprint requests: Dr A Manoharan, St George Hospital, Kogarah, NSW 2217, Australia.

Accepted 28 August 1986

*Benign thymic cysts in Hodgkin's disease: review of published cases*

Patient No.	Sex/age (y)	Hodgkin's disease		Treatment	Diagnosis of thymic cysts	Reference
		Histology	Stage			
1	M/29	MC	IIB	DXRT/vinblastine	At thoracotomy for residual mediastinal mass	3
2	F/25	NS	IIB	MOPP/DXRT/ vinblastine	At thoracotomy for residual mediastinal mass	3
3	F/40	NS	IIB	MOPP/DXRT/ vinblastine	At thoracotomy for residual mediastinal mass	3
4	M/17	MC	NR	DXRT/COPP	At necropsy after persistent mediastinal mass	4
5	M/23	MC	IIIB	MOPP/DXRT	At thoracotomy for new mediastinal mass	4
6	M/29	MC	IA	DXRT/MOPP/ ABVD	At thoracotomy after CT showed persisting mediastinal mass in relapse not responding to ABVD	4
7	F/21	NS	IIA	MOPP	At thoracotomy for persistent mediastinal mass	5
8	F/23	NS	IIA	DXRT	At thoracotomy for increasing mediastinal mass	6
9	F/28	NS	IIA	DXRT	At thoracotomy for increasing right hilar mass	6
10	M/39	NS	NR	DXRT/MOPP	FNAB of cystic lesion on CT scan for increasing mediastinal mass	7
11	M/26	NS	IIB	MOPP	FNAB of cystic lesion on CT scan at presentation	This report

MC—Mixed cellularity; NS—nodular sclerosing; DXRT—radiotherapy; MOPP—nitrogen mustard, vincristine, procarbazine, prednisone; COPP—cyclophosphamide, vincristine, procarbazine, prednisone; ABVD—adriamycin, bleomycin, vinblastine, DTIC; FNAB—fine needle aspiration biopsy; CT—computed tomography.

**Discussion**

The table summarises the clinical details of the 11 reported cases of thymic cysts in Hodgkin's disease. The common clinical feature in all these cases was a mass localised in the anterior mediastinum, which led to a thoracotomy in nine cases and fine needle aspiration of the cystic lesions revealed by computed tomography in two. The latter procedure yielded a clear serous fluid in both cases, with no malignant cells on cytological examination. Our patient differed from others in that the cystic areas were present at the time of initial diagnosis and resolved with chemotherapy. He then received adjuvant mediastinal radiotherapy because of the increased risk of local relapse in patients with bulky mediastinal masses.

Thymic cysts apparently may accompany active Hodgkin's disease, either at initial presentation or at relapse, or may manifest themselves after completion of effective treatment. The pathogenesis of thymic cysts in patients with Hodgkin's disease is not clear. The suggestion that the cystic changes represent treatment induced degeneration of the disease is not relevant to our patient. Furthermore, in at least some of the previously reported patients from the days before computed tomography, the thymic cysts could have been present at the time of initial presentation and persisted throughout the treatment period. Finally, the cysts, as in our patient, may actually clear with treatment—evidence that tends to refute the explanation that they may represent simple thymic cysts. This also raises the possibility that, among

patients previously treated who had a large mediastinal mass detected by routine radiography alone, some may have had cystic areas that also resolved after treatment.

The presence of thymic cysts in patients with Hodgkin's disease appears to have no clinical importance, provided that it is recognised. It may present a diagnostic difficulty and if the finding is interpreted as representing residual or progressive disease, further treatment may increase the likelihood of illness and death. The use of thoracic computed tomography and fine needle biopsy may offer accurate diagnosis without major surgical intervention.

**References**

- 1 Keller AR, Castleman B. Hodgkin's disease of the thymus gland. *Cancer* 1974;33:1615–23.
- 2 Tartas NE, Korin J, Dengra CS, Barazzutti LM. Diffuse thymic enlargement in Hodgkin's disease. *JAMA* 1985;254:406.
- 3 Katz M, Piekarski JD, Bayle-Weisgerber C, Laval-Jeantet M, Teillet F. Residual mediastinal mass following radiation therapy for Hodgkin's disease. *Am Radio* 1977;20:667–72.
- 4 Baron RL, Sagel SS, Baglan RJ. Thymic cysts following radiation therapy for Hodgkin's disease. *Radiology* 1981;141:593–7.
- 5 Anonymous. Case records of the Massachusetts General Hospital (Case 47, 1982). *N Engl J Med* 1982;307:1391–7.
- 6 Murray JA, Parker AC. Mediastinal Hodgkin's disease and thymic cysts. *Acta Haematol* 1984;71:282–4.
- 7 Kin HC, Noshier J, Haas A, Sweeney W, Lewis R. Cystic degeneration of thymic Hodgkin's disease following radiation therapy. *Cancer* 1985;55:354–6.