Thorax 1981;36:695-696

Hydralazine lung

BH BASS

From the Department of Medicine, Good Hope General Hospital, Sutton Coldfield, West Midlands

It has been known since 1954[1] that some patients treated for hypertension with the vasodilator hydralazine, may develop a syndrome indistinguishable from systemic lupus erythematosus (SLE). Pulmonary involvement in this syndrome is extremely rare, and for this reason a case of this is reported.

Case report

Mrs RB, a housewife aged 48 years, was seen as an outpatient in 1978 because of severe hypertension. Her blood pressure at the time of her first visit was 260/150 mmHg. Left ventricular enlargement was present and her cardiogram showed a left ventricular strain pattern. The optic fundi showed grade II hypertensive changes. The blood urea was elevated at 9·0 mmol/litre and an intravenous pyelogram revealed normal sized kidneys with only fair excretion of the dye. She was treated with atenolol 100 mg daily together with polythiazide 1 mg daily, and also hydralazine 50 mg tid.

Four weeks later her blood pressure had come down to 160/90 mmHg and she was feeling well.

A year later the blood pressure was 155/85. The blood urea was 7·2 mmol/litre, and the cardiogram revealed less left ventricular strain. The optic fundi were normal.

One week after her last visit to outpatients, she returned with a complaint of extreme breathlessness, haemoptysis of bright red blood occurring daily, and a pleuritic pain in her left lower chest anteriorly. On examination she was obviously ill. A loud pleural rub was heard over the right lower lobe anteriorly (despite the pain being in the left), and the urine contained protein ++ and blood + on routine testing.

The hydralazine was discontinued immediately and the following investigations were carried out: haemoglobin = 6·5 g/dl; ESR 92 mm/hour; antinuclear factor (ANF) positive to a titre of 1 in 400; DNA positive to titre of 1 in 640; LE latex tests—positive; smooth muscle and mitochondrial antibodies—negative. A chest radiograph (fig 1) showed diffuse fluffy miliary shadowing bilaterally.

Two weeks after stopping the hydralazine she was feeling very much better. The haemoptyses had stopped and her breathing was normal. The pleural rub had disappeared. The chest radiograph (fig 2) showed clearing of the shadowing.

Address for reprint requests: Dr BH Bass, Department of Medicine, Good Hope General Hospital, Sutton Coldfield, West Midlands B75 7RR.

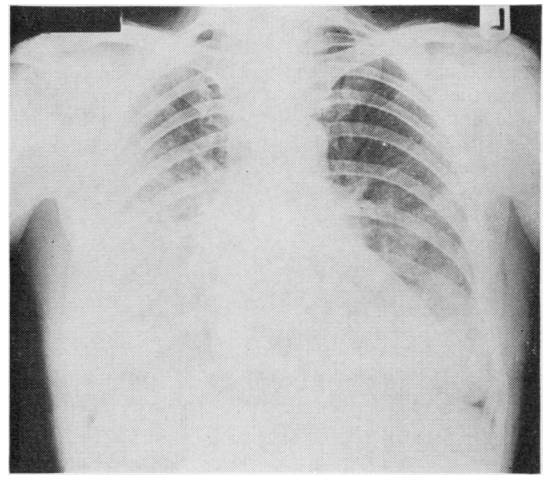

Fig 1 *Radiograph of chest showing bilateral pulmonary infiltration at time of severe illness.*

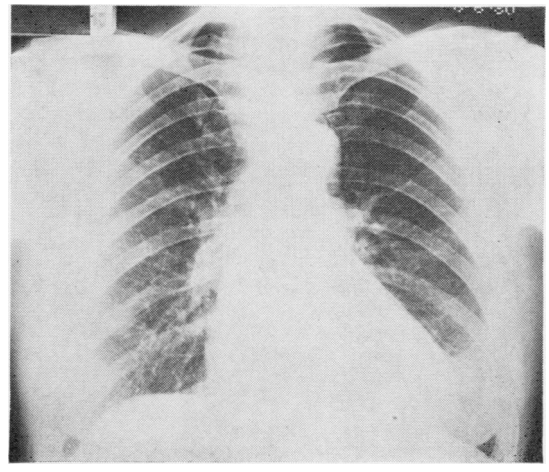

Fig 2 *Radiograph of chest two weeks after stopping hydralazine, showing clearing of pulmonary shadowing.*

Thorax: first published as 10.1136/thx.36.9.695 on 1 September 1981. Downloaded from http://thorax.bmj.com/ on April 23, 2024 by guest. Protected by copyright.

One month later, her blood picture was normal (Hb = 13·0 g/dl), and the ESR had fallen to 26 mm/hour. Proteinuria (300 mg %) was still present.

Because of this reaction to hydralazine, her acetylator status was determined using sulphadimidine and she proved to be a slow acetylator.

Discussion

Pulmonary involvement in the SLE syndrome associated with hydralazine therapy is very rare. A case described by Ripe[2] exhibited pulmonary infiltrates after 11 months of treatment with hydralazine, but the serological tests were negative, and there is doubt as to whether this could be considered to be part of the syndrome.

Pleural effusion has been described, together with LE cells in the pleural fluid in a single case,[3] but involvement of the lung was found in only three cases in a fairly large series of 44 patients demonstrating the hydralazine LE syndrome.[4]

The present case illustrates severe pulmonary involvement in a patient taking hydralazine who was subsequently shown to be a slow acetylator. The pulmonary abnormality was reversed by prompt discontinuation of the drug, but the serological tests continue to show raised titres against DNA with a positive ANF.

References

1 Dustan HP, Taylor RD, Cocoran AC, Page IH. Rheumatic and febrile syndrome during prolonged hydralazine treatment. *JAMA* 1954;**154**:23-9.

2 Ripe E, Nilsson BS. Pulmonary infiltrations during dihydralazine treatment in a slow isoniazid inactivator. *Scand J Respir Dis* 1972;**53**:56.

3 Weinstein J. A case of hydralazine induced systemic lupus erythematosus with pleural effusion. *Am J Med* 1978;**65**: 553.

4 Perry HM. Late toxicity of hydralazine resembling systemic lupus erythematosus or rheumatoid arthritis. *Am J Med* 1973;**54**:58.

Thorax: first published as 10.1136/thx.36.9.695 on 1 September 1981. Downloaded from http://thorax.bmj.com/ on April 23, 2024 by guest. Protected by copyright.