

Short reports

Lung bullae, bronchiectasis, and Hashimoto's disease associated with ulcerative colitis treated by colectomy

J M SHNEERSON

From the Department of Thoracic Medicine, Westminster Hospital, London

Ulcerative colitis has many systemic manifestations, such as erythema nodosum and iritis, and is now recognised as a multi-system disease. A patient is reported in whom total colectomy for ulcerative colitis was followed by development of autoimmune haemolytic anaemia, Hashimoto's disease, and pulmonary bullae and bronchiectasis. The association of these conditions with ulcerative colitis and the similarity of their immunological mechanisms are discussed.

Case report

The patient (EH), aged 29 years, developed diarrhoea during her second pregnancy in 1954. She delivered a normal child but despite high doses of cortisone for six months afterwards, profuse bloody diarrhoea persisted and necessitated a colectomy in 1955 and a proctectomy in 1957. The whole colon was ulcerated and crypt abscesses and pseudo-polyps were present. Histological examination confirmed ulcerative colitis.

She began to have recurrent chest infections in 1969. Her chest radiograph, which had previously been normal, showed basal shadowing, especially on the right, and thin-walled bullae (figure). A bronchogram in 1976 showed mild cylindrical bronchiectasis in the right middle and lower lobes and the left lower lobe. In 1976, her voice became hoarse and a serum T4 was only 51 nmol/l (normal 70-160) and TSH 12.9 mU/l (normal <2.8). Her antithyroglobulin and thyroid microsome antibodies were strongly positive, and her thyroglobulin tanned red cell titre was positive at 1/4800. By 1978 she required 0.25 mg thyroxine daily.

In March 1978 her haemoglobin fell to 9.8 g/dl with 25.6% reticulocytes, a direct Coombs' test was positive, and haptoglobins were absent. Her serum contained a strongly positive IgG auto-anti e at 37°C, antinuclear factor was positive at 1/80, DNA binding was negative, Rose Waaler negative, IgG 16.6 g/l, IgM 0.6 g/l, IgA 0.6 g/l, C3 0.4 g/l (normal 0.7-1.7), and C4 was normal. Her HLA group was A1, 3, B7, 8. Immunofluorescence using a preparation of rat colon was negative but there was a mild diffuse fluorescence with bronchial mucosa and mucous glands. No fluorescence was seen on chondrocytes. Alpha-1-antitrypsin was 2.5 g/l (normal 1.8-3.0).

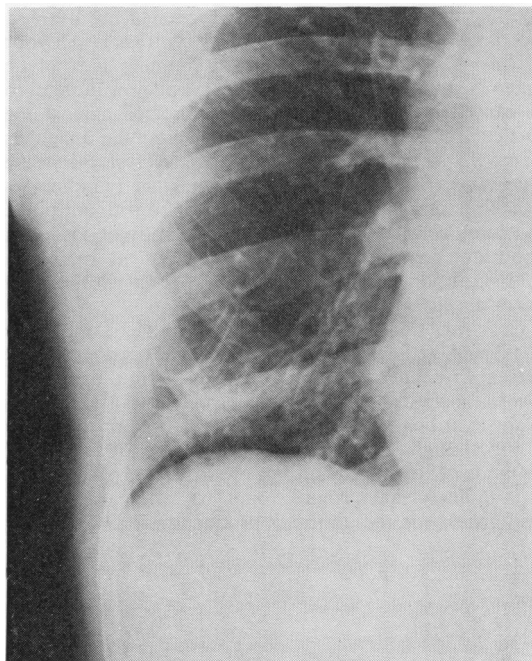


Figure Chest radiograph showing basal shadowing and thin-walled bullae.

Her anaemia required a maintenance dose of about 10 mg prednisone daily. Chromium 51 studies showed that haemolysis was confined to the spleen. Splenectomy was performed in September 1979 and prednisone withdrawn. Her haemoglobin remained normal, but she developed severe polyarthralgia, worst in her wrists, and copious, persistently purulent sputum. This did not respond to inhaled beclomethasone. Tests for phagocytic function (*Staphylococcus aureus* and *Candida* killing) were normal. Prednisone was restarted in March 1980, and her polyarthralgia improved and sputum production lessened.

Discussion

Autoimmune haemolytic anaemia is an uncommon but well-documented association of ulcerative colitis¹ and is usually, as in this case, of the warm type and caused by IgG

antibody. Bullae have not been recorded before, and there has only been one brief mention of thyroiditis occurring with ulcerative colitis² and one report of bronchiectasis³. The significance of the association of these conditions with ulcerative colitis is still doubtful because the few reported cases could have occurred by chance. The present case, however, suggests that the association is a real one since both conditions have occurred in a single patient with ulcerative colitis and, furthermore, in one who also has another well-recognised and demonstrably autoimmune complication.

The pathogenesis of the bronchiectasis is uncertain. It could be the result of diminished resistance to infection but its association with bullae, indicative of acinar destruction, suggests that both are the result of autoaggressive disease. The finding of antibodies against bronchial mucosa and mucous glands, although only weakly positive, is in favour of this. Hashimoto's disease, autoimmune haemolytic anaemia, and ulcerative colitis itself are all now thought to be caused primarily by antibodies directed against the particular tissues. In autoimmune haemolytic anaemias macrophages are required to complete cell lysis but in the other two conditions it results from killer lymphocytes attaching to cells which are already coated with antibody. It is not certain which anti-thyroid antibody is most important in Hashimoto's disease,⁴ but in ulcerative colitis antibodies to *E coli* 014 cross-react with colonic mucosal cells.

Cross-reaction between pulmonary antigens and those in thyroid, red cell or colon could have occurred in the present case, but the time course of the various conditions makes this unlikely. Over-ready production of antibodies against various endogenous tissues is more probable, and is now thought to be the result of a failure of suppressor lymphocytes to prevent antibody release from plasma cells. It is unlikely that "rogue clones" of plasma cells were responsible for the antibody production in this patient,

since no monoclonal band of immunoglobulins was detected.

Autoimmune haemolytic anaemia may appear for the first time after colectomy⁵ as in this case, but it is noteworthy that the thyroiditis and bronchiectasis also occurred in this way. Thus, although colectomy abolishes the risk of colonic carcinoma, it does not appear to extinguish the abnormal immunological processes that are an integral part of ulcerative colitis. With increased awareness of the possibility that bronchial and acinar diseases may be associated with ulcerative colitis, a range of conditions, similar to those seen with rheumatoid arthritis, may soon be recognised.

I would like to thank Dr PA Emerson for permission to report this patient under his care and Professor JR Hobbs and Dr P Haslam for their immunological studies.

References

- 1 Arner O, Brohult J, Engstedt L, Karlson R, Sällström T. Auto-immune hemolytic anemia in ulcerative colitis, cured by colectomy. *Acta Med Scand* 1971; **189**:275-7.
- 2 Becker KL, Titus JL, Woolner LB, McConahey WH. Significance of morphologic thyroiditis. *Ann Intern Med* 1965; **62**:1134-8.
- 3 Kraft SC, Earle RH, Roesler M, Esterly JR. Unexplained bronchopulmonary disease with inflammatory bowel disease. *Arch Intern Med* 1976; **136**:454-9.
- 4 Calder EA, Irvine WJ. Cell-mediated immunity and immune complexes in thyroid disease. *Clin Endocrinol Metabol* 1975; **4**:287-318.
- 5 Bardana EJ Jr, Pirofsky B. Auto-immune hemolytic anemia and ulcerative colitis: a multisystem immunodeficiency disease? *Arch Allergy Appl Immunol* 1970 **37**:325-36.