

Impalement wound of the chest

A GROSSI, B MEZZACAPO, G BIAGI, G GOTTI

From the Department of Thoracic and Cardiovascular Surgery, University of Siena, Medical School, Siena, Italy

This report describes a case of impalement wound of the chest and its successful surgical management.

Case report

A 18-year-old man was admitted on 26 June, 1980, as an emergency to the S Maria della Scala Hospital in Siena after driving his car into a fence. A wooden pole penetrated the right side of the chest, immobilising him in his seat for about half an hour. He did not lose consciousness. Before removing him from the car, firemen had to saw through the pole, after some unsuccessful attempts to draw it out of the chest. A chest film taken on admission showed the image of the end of the pole with two large nails in it, in the right side of the chest. There was a pneumothorax but no haemothorax (fig 1).

The patient was transferred to the Institute of Thoracic

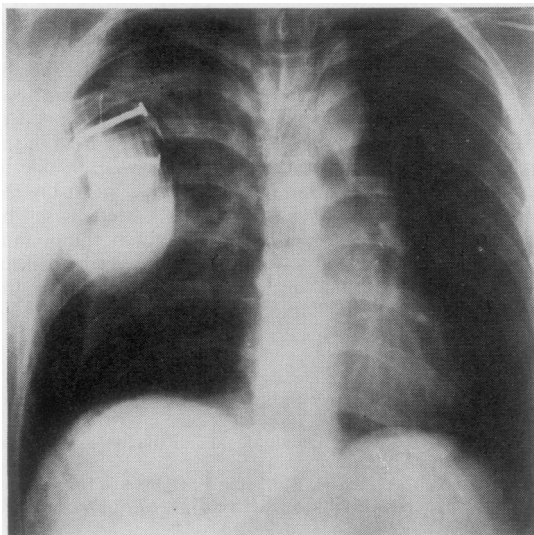


Fig 1 PA chest radiograph at the time of the patient's hospital admission. Note partial collapse of the lung, absence of haemothorax, and prominent nails in the intrathoracic pole.

Address for reprint requests: Professor A. Grossi, Università Degli Studi di Siena, Istituto di Chirurgia Toracica e Cardiovascolare, 53100 Siena, Italy.

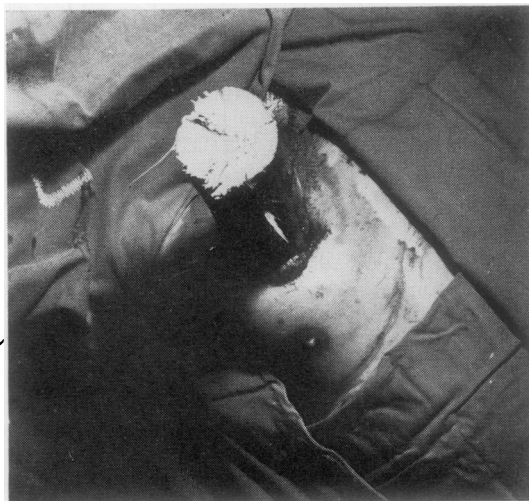


Fig 2 Preoperative view of the impaled chest.

and Cardiovascular Surgery. He was conscious and moderately dyspnoeic. His blood pressure was 140/90 mmHg and the pulse rate 120 per minute, regular. He was not cyanosed. Between the subclavicular and mammary region of the right side of the chest a pole protruded anteriorly, about 8 cm in diameter (fig 2). The space between the skin and the pole was completely sealed by torn clothes, so that no respiratory sucking sounds were audible. After induction of general anaesthesia the patient was placed in the supine position with the right side of the chest slightly elevated for an anterolateral thoracotomy in the fifth intercostal space. Before opening the chest, the protruding portion of the pole was draped with a sterile towel and plastic drape to allow it to be handled in a sterile manner. After opening the chest, the pole was extracted under direct vision along the original track, after turning down the large fence nails in the end with an heavy orthopaedic instrument. Blood, clots and large fragments of clothes were removed from the pleural cavity. The right upper lobe was lacerated as far as the lobar hilum, without involvement of bronchial vascular components. There was a displaced fracture of the third right rib and extensive laceration of the pectoral muscles and skin anteriorly. Posteriorly, there were comminuted fractures of the eighth and ninth ribs, laceration of the intercostal vessels and a good deal of muscle contusion.

Repair of the upper lobe and the parietal lesions was accomplished with minimal removal of viable tissue. After irrigation the pleural cavity was drained. Fractured ribs were immobilised with pericostal heavy chromic catgut sutures. The thoracotomy was then closed and the impalement wound repaired after applying antibiotics locally. Controlled ventilation was used for 24 hours. The postoperative course was uncomplicated and the patient was discharged on the twentieth postoperative day.

Discussion

Impalement of the chest is rare. Romero and colleagues,¹ reporting one case, were able to find only two similar published cases.^{2,3}

Our experience shows that the patient may survive impaled at his seat for up to 30 minutes without life-threatening disturbance of vital functions. Any attempt to remove the foreign body until the chest can be opened must be resisted. Safe extraction of the pole can be achieved only under direct vision after thoracotomy and control of the major vessels. A chest radiograph soon after admission, whenever it is feasible, is a source of

invaluable information about the shape of the intra-thoracic portion of the pole as in our patient. Awareness of the presence of large nails alerted us to have available appropriate orthopaedic surgical instruments.

We restricted lung excision to a minimum, being concerned about the risk of empyema in any residual pleural space. We adopted the same conservative approach for the parietal wounds, retaining as much tissue as possible to achieve sealing of the pleural cavity. However, because of the extensive loss of pectoral muscles, skin cover only was possible. In spite of the adverse experience of Romero and colleagues,¹ we found this procedure to be effective and safe.

References

- ¹ Romero LH, Nagamia HF, Lefemine AA, Foster ED, Wysocki JP, Berger RL. Massive impalement wound of the chest. *J Thorac Cardiovasc Surg* 1978;**75**:832-5.
- ² Asch MJ, Lippman M, Nelson RJ, Moore TC. Truck aerial impalement injury of the thorax. Report of a case in an 8-year-old boy. *J Pediatr Surg* 1974;**9**:251-2.
- ³ Marable SA, Maloney JV jr. Bilateral transfixion injury of the thorax. *J Thorac Cardiovasc Surg* 1963;**45**:161-5.