

Operation for sigmoid oesophagus

A J NAKVI AND W C BARNSELY

From the Cardiothoracic Unit, University of Newcastle, Freeman Hospital, Newcastle upon Tyne

Sigmoid deformity of the thoracic oesophagus is an uncommon complication of longstanding achalasia of the cardia. As the disease advances the dilated upper segment of the oesophagus elongates and sags below the level of the narrow lower segment causing mechanical obstruction. Whereas Heller's cardiomyotomy is the operation of choice for simple achalasia, it is regarded as inadequate when sigmoid deformity is present.¹ Reconstructive operations on the other hand are often too formidable for old and frail patients. We describe a surgical technique for dealing with this condition and report a patient in whom long-term functional improvement has been achieved by its use.

Case report

A 55-year-old woman was admitted to hospital because of dyspnoea and central chest pain which followed a large meal eight hours earlier. She had suffered from mild dysphagia, often associated with chest pain, since she was 19 years old. During the previous six months, on several occasions she had had to force the food down with large volumes of water. There was also a history of frequent respiratory tract infections. On physical examination there was mild cyanosis of the lips and nail beds and slight clubbing of the fingernails. The jugular venous pressure was raised but there was no peripheral oedema. Her heart was in sinus rhythm and the heart sounds were normal. Coarse crackles were heard over the whole chest. A chest radiograph showed that the oesophagus was markedly dilated and was filled with fluid and gas. It projected into the right hemithorax.

At oesophagoscopy a large volume of food residue was sucked out from the lumen of the oesophagus. The oesophageal mucosa was pale and appeared almost trabeculated. The instrument was not passed into the stomach because the cardia could not be located. Barium studies confirmed the presence of sigmoid deformity (fig 1).

She was operated upon on 18 July 1975. The cardia and distal oesophagus were approached through a left posterolateral thoracotomy. The mediastinal pleura was incised and the oesophagus was mobilised from the hiatus to the level of the arch of the aorta. The upper segment was tortuous and grossly dilated. Its funnel-shaped dependent portion, lying across the

diaphragm, occupied most of the right hemithorax. After completion of a standard cardiomyotomy, an F 50 oesophageal bougie was passed from the mouth into the stomach to prevent inadvertent narrowing of the reconstructed oesophagus. With the bougie in this position the posterior wall of the dependent loop, and the oesophagus above it, were inverted vertically as far up as the level of the inferior pulmonary vein (fig 2). The two pouches were approximated with interrupted 3/0 silk sutures. The oesophageal hiatus was also narrowed with three interrupted linen sutures.

The patient's postoperative course was uncomplicated and she was able to swallow normal diet on the tenth day after operation. Subsequent barium studies (fig 3) showed free flow of barium into the stomach, although some residual deformity and consequently stasis remained which could possibly have been avoided if a more liberal inversion of the oesophagus had been undertaken. At present, three and a half years after the operation, she is swallowing normally and remains symptom-free. In the recent barium studies the appearance of the lower oesophagus remains essentially unchanged.

Discussion

Dilatation and hypertrophy of the upper segment of the thoracic oesophagus are the outstanding features of longstanding achalasia of the cardia. In some patients with marked dilatation there is often an elongation of the oesophagus as well which produces tortuosity and results in sigmoid deformity. As the oesophagus fills up, the most dependent part of the sigmoid loop descends, accentuates the angle between it and the lower segment and acts as a sump. Complete obstruction, although rare, may occur. Pulmonary complications from inhalation of the oesophageal contents are common. Patients with this condition present a problem for which there is not at present a generally accepted line of treatment. Any surgical procedure which will permanently relieve the distressing symptoms of this lesion must remove the mechanical factors of obstruction. This result is less likely to be achieved by cardiomyotomy alone.¹ Various surgical procedures have been recommended for the treatment of this condition yet no one method has proved entirely satisfactory. Partial or total resection of the thoracic oesophagus has been used by Wangenstein² and others.^{3,4} While immediate relief of

Present address: Harefield Hospital, Harefield, Middlesex.

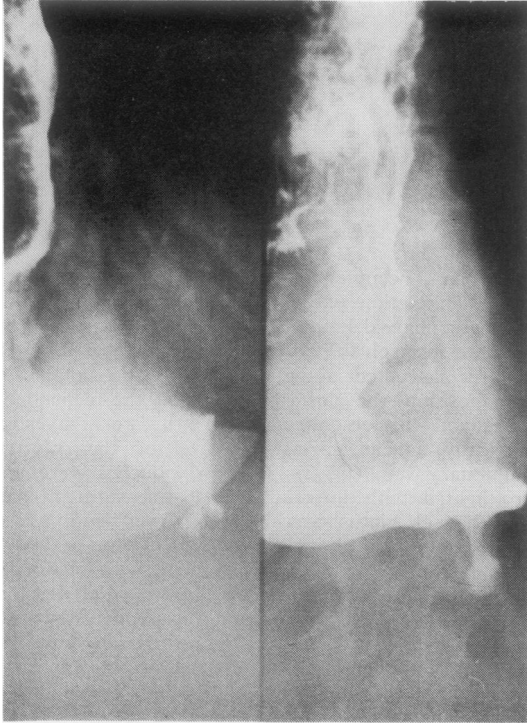


Fig 1 *Preoperative barium swallow showing part of the dependent loop and the short narrow segment of the oesophagus.*

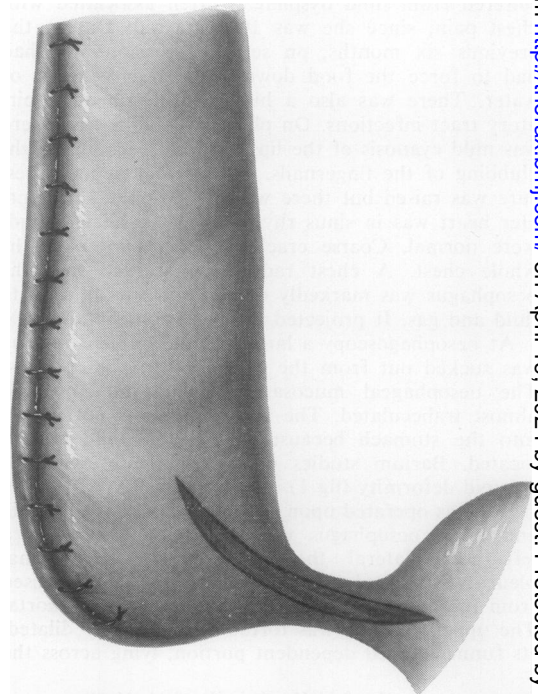


Fig 2 *Diagrammatic sketch shows reconstructed oesophagus.*

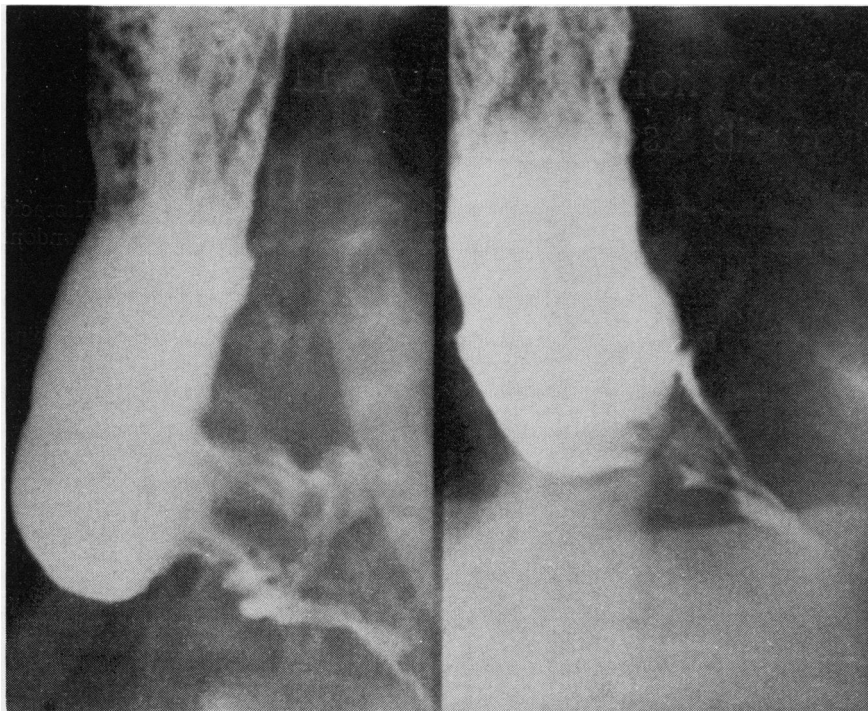


Fig 3 Postoperative barium swallow shows residual deformity and stasis. However, barium passes freely into the stomach.

symptoms may be offered by such procedures, reflux oesophagitis with its sequelae ultimately supervenes in a high percentage of cases.⁵ Moreover, the radical nature of these procedures makes them less than desirable for the treatment of what is basically a benign condition, particularly in old people. The technique described here achieves the objective of relieving dysphagia by a combination of cardiomyotomy and inversion and plication of the dilated oesophagus. This method is simple and the morbidity associated with more radical procedures is avoided. The present case demonstrates that this procedure may provide a solution to an uncommon surgical problem.

References

- 1 Ellis FG. The aetiology and treatment of achalasia of cardia. *Ann R Coll Surg* 1962; **30**:155-79.
- 2 Wangenstein OH. A physiologic operation for megaesophagus. *Ann Surg* 1951; **134**:301-18.
- 3 Le Roux BT, Wright JT. Cardiospasm. *Br J Surg* 1961; **48**:619-33.
- 4 Barrett NR. Achalasia of cardia: reflections upon a clinical study of over 100 cases. *Br Med J* 1964; **1**:1135-40.
- 5 Wingfield HV, Karwowski A. The treatment of achalasia by cardiomyotomy. *Br J Surg* 1972; **59**:281-4.