

# A manometric assessment of oesophagogastrostomy

D. W. WARD and H. R. MATTHEWS

*The Gastroenterology Unit and the Regional Cardiothoracic Unit, Broadgreen Hospital, Thomas Drive, Liverpool L14 3LB*

**Ward, D. W. and Matthews, H. R. (1976).** *Thorax*, 31, 656–659. **A manometric assessment of oesophagogastrostomy.** Intraluminal pressures were recorded in 14 patients who had undergone oesophagogastrectomy. Seven of these had a mid-thoracic and seven a high cervical oesophagogastrostomy. The incidence of postoperative reflux complications in each group was noted. No pressure gradient across the anastomosis was detected in any patient but the upper oesophageal sphincter was shown to be retained as a functioning unit in all cases. It is considered that the thoracic anastomosis provides no demonstrable barrier to reflux. In addition, a high cervical oesophagogastrostomy does not adversely affect the upper oesophageal sphincter. The wider application of this latter procedure may be associated with a decreased incidence of postoperative reflux complications.

One of the simplest ways of restoring alimentary continuity after resection of the lower oesophagus is by direct anastomosis of the mobilized stomach to the oesophageal remnant in the thorax somewhere below the aortic arch. Free gastro-oesophageal reflux commonly results, producing troublesome symptoms of oesophagitis, haemorrhage, and stricture formation.

If a more extensive oesophageal resection is undertaken and an oesophagogastric anastomosis is fashioned in the neck, these complications seem to occur less frequently. To investigate possible reasons for this we have measured intraluminal pressures in patients previously subjected to an oesophageal resection with either a thoracic or cervical oesophagogastric anastomosis.

## PATIENTS AND METHODS

Fourteen patients (8 male and 6 female) aged 40 to 74 years were studied 6 to 80 months after oesophageal resection. The postoperative course was reviewed in each with regard to reflux symptoms and stricture formation, and oesophageal manometry was performed.

Seven of these patients (group I) had undergone a standard oesophagogastrectomy for carcinoma of the lower oesophagus. The lower third of the organ had been resected together with a portion of stomach, and a subaortic, thoracic anastomosis was constructed.

The remaining seven patients (group II) had undergone a complete thoracic oesophagectomy without any gastric resection. Reconstruction was by a cervical anastomosis to the fundus of the stomach. Five of these operations were for carcinoma (3 lower third, 2 middle third), one for achalasia after an unsuccessful Heller's operation, and one was for an extensive reflux stricture with two peptic ulcers in the oesophagus.

**MANOMETRY** The patients fasted for at least six hours before the test and lay comfortably supine throughout. Local anaesthesia was not employed. A triple-lumen tube, graduated in centimetres, was passed via the mouth until the three distal side openings, spaced 5 cm from each other, lay well within the stomach. Each lumen had an internal diameter of 1.4 mm, was continuously perfused with previously boiled water at a rate of 5.4 ml/hour, and was connected proximally via a bench-mounted transducer to one channel of a Devices M4 recorder. On this the transmitted pressure changes were reproduced, together with a signal indicating each swallow as recognized by the attendant nurse.

After a basal tracing had been obtained from the stomach the tube was withdrawn 0.5 cm at a time in a carefully controlled manner. A profile of pressure changes, occurring both at rest and on swallowing, was thus obtained from the stomach, the oesophageal remnant, the cricopharyngeal

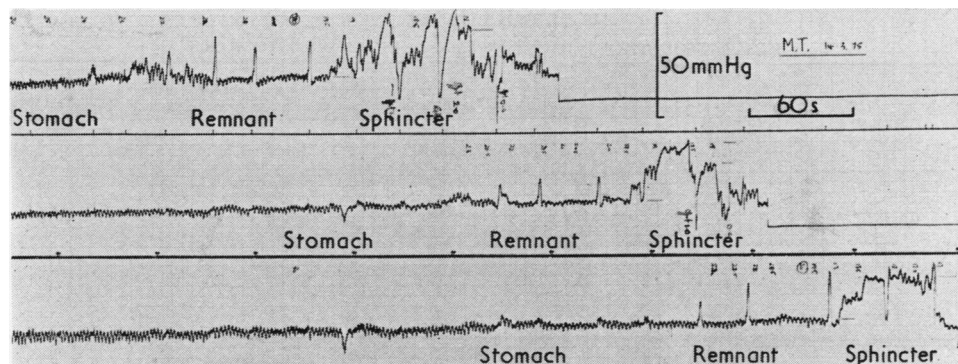


FIGURE 1 A typical pressure tracing recorded with the three-lumen tube.

region, and the mouth in every patient (Figure). Each record was then analysed for the following data: (1) the distance, in centimetres, of the oesophagogastric anastomosis from the lips; (2) the presence of any pressure gradient at this anastomosis; (3) the distance of the distal limit of the upper oesophageal sphincter from the lips; (4) the length of the remaining oesophagus; (5) the length of the upper sphincter; and (6) the maximum resting pressure of this sphincter (mmHg). These measurements were calculated as the average of three readings obtained in each case from the triple-lumen tube. In all patients, except one with the aperistaltic oesophagus of achalasia, the position of the anastomosis was readily determined by noting the emergence of oesophageal type contractions after swallowing.

## RESULTS

**GROUP I—THORACIC ANASTOMOSES** No gradient was recorded in any patient at the anastomosis, but three patients (HR, AT, ED) showed transient spastic contractions in the terminal oesophagus.

The mean length of oesophagus remaining in this group was 12.1 cm (Table I). The mean length of the upper sphincter was 3.2 cm, and its mean resting pressure 44 mmHg above the intra-oesophageal level. This pressure is considerably higher than that in normal subjects who have a mean pressure of 18 mmHg in our laboratory (range 10–25 mmHg). Sphincter demarcation was good in six patients and fair in one. Relaxation on swallowing occurred satisfactorily in all.

One patient (AT) had an established reflux stricture after operation which had required oesophagoscopy and dilatation on three occasions. She could take only liquids and semisolids. Two others had mild reflux symptoms and a fourth had intermittent dysphagia, possibly due to spasm.

**GROUP II—CERVICAL ANASTOMOSES** No gradient was recorded at the anastomosis in any patient and the oesophageal remnant was only 0.5 to 3.5 cm long (mean 2.0 cm) (Table II). The mean length of the upper sphincter was 2.7 cm and its mean resting pressure 29 mmHg; this was lower than in group I patients but still higher than in

TABLE I  
RESULTS OF GROUP I PATIENTS—THORACIC ANASTOMOSES

Patient	Age at Operation (yr)	Interval to Study (mth)	Level of Anastomosis (cm)	Distal Limit of Upper Sphincter (cm)	Length of		Maximum Pressure of Upper Sphincter (mmHg)
					Oesophageal Remnant (cm)	Upper Sphincter (cm)	
JH	53	14	28	19	9	4	46
EW	47	13	29	16.5	12.5	3.5	53
HR	40	28	28.5	16.5	12	3.5	65
AT	68	49	33	16	17	3.5	45
JD	67	60	28	17	11	2	43
ED	73	59	32.5	17	15.5	2	19
GG	69	80	26.5	18.5	8	4	37
Mean	60	43.3	29.4	17.2	12.1	3.2	44

TABLE II  
RESULTS OF GROUP II PATIENTS—CERVICAL ANASTOMOSES

Patient	Age at Operation (yr)	Interval to Study (mth)	Level of Anastomosis (cm)	Distal Limit of Upper Sphincter (cm)	Length of		Maximum Pressure of Upper Sphincter (mmHg)
					Oesophageal Remnant (cm)	Upper Sphincter (cm)	
TR	69	24	19	17	2	2.5	25
JH	74	9	19.5	19	0.5	1.5	9
MJ	71	21	Achalasia	15	Achalasia	2.5	20
EP	64	6	18	16.5	1.5	2.5	27
TB	73	8	21	19	2	3.5	53
RI	55	28	18.5	15	3.5	2.5	39
MT	59	25	22	19.5	2.5	3.5	29
Mean	66	17.3	19.7	17.7	2.0	2.7	29

normal subjects. Again the sphincter was well demarcated in six but poorly in one. Relaxation occurred in each case after swallowing.

No patient had serious reflux complications but two had mild reflux symptoms, one of whom experienced occasional sticking of food if she failed to masticate properly.

#### DISCUSSION

Thoracic oesophagogastrectomy has generally proved to be a satisfactory operation for carcinoma involving the lower oesophagus, but reflux complications are a significant problem in patients who do not succumb to recurrent tumour at an early stage. Such complications occur in up to 47% of patients having the standard procedure (Boyd *et al.*, 1975). As the relief of dysphagia is an indication for operation in the first place the development of a reflux stricture in particular constitutes a serious failure of treatment.

While the number of patients with cervical oesophagogastrostomy is at present too small to permit a valid statistical analysis of the comparative incidence of postoperative reflux symptoms, initial experience suggests that these may be considerably reduced after the higher anastomosis. The present study was undertaken in an attempt to identify some physiological factors that might be responsible. In particular we have sought an answer to two main questions:

1. Does the standard thoracic anastomosis generate any sphincteric activity?
2. Does the construction of a cervical anastomosis close to the upper oesophageal sphincter impair or destroy the function of that sphincter? If it did, the procedure would be strictly contraindicated.

The first question is answered by the results in group I. No patient showed across the anastomosis

any measurable pressure gradient which might form a barrier to reflux and so protect the oesophageal remnant (with a mean length of 12.1 cm) from gastric contents. Moreover, it is possible that these anastomoses are effectively held open by the negative intrathoracic pressure (transmitted equally to the oesophagus above and the stomach below). The first and only barrier to reflux then would be the upper oesophageal sphincter.

In the patients of this series, no attempt had been made to construct a valve mechanism at the anastomosis by fundoplication or similar technique. Even if such procedures are shown experimentally to produce a high pressure zone the extra oesophageal tissue required may preclude adequate surgical clearance of tumour margins and, therefore, favour the local recurrence of malignancy.

Because of these considerations it is logical to propose the construction of an anastomosis in the neck much closer to the upper sphincter of the oesophagus, provided the function of that sphincter is not adversely affected. Results in group II patients indicated that it is not. Mean sphincter pressure was higher than in normal subjects and mean sphincter length was reduced by only 0.5 cm compared with group I. Also, in contrast to the thoracic anastomoses, the negative intrathoracic pressure in the cervical group is transmitted to the stomach alone, the anastomosis in the neck and the oesophageal remnant above being subject to a positive atmospheric pressure. This will tend to close the anastomosis.

Of separate interest in this study is the finding that upper sphincter pressures were greater in both groups of patients than in normal subjects. In the light of similar findings in patients with hiatal hernia (Hunt, Connell, and Smiley, 1970) this may suggest that upper sphincter spasm is

occurring in response to reflux into the oesophagus more in patients with a thoracic anastomosis than in those with a cervical anastomosis.

Rather than being destroyed, therefore, the upper sphincter seems to be retained as a functional unit close to the high anastomosis, and at the same time the length of oesophagus remaining potentially exposed to refluxed material is greatly reduced.

Other possible advantages of the cervical anastomosis can be cited. There may exist within the upper thorax a level or tidemark (Lancet, 1971) above which refluxed contents infrequently pass and only momentarily remain during routine daily activity. This level may vary in different individuals depending on numerous factors, including posture and bodily configuration, but resection of a greater part of the oesophagus will make it more likely that both the anastomosis and the oesophageal remnant lie above this point. Secondly, more radical oesophageal resection will reduce the likelihood of tumour recurrence from submucosal spread (McKeown, 1972). Finally, if leakage develops at an anastomosis, that occurring in the neck will produce a cervical abscess which is easily drained. Leakage from a thoracic anastomosis would give rise to a mediastinal abscess probably requiring drainage by a second thoracotomy. Multiple anastomoses, necessary in colonic or jejunal replacement procedures, are of course not required.

In this unit, cervical oesophagogastrostomy has been performed only where insufficient clearance remained below the aortic arch after removal of

the initial lesion. The indications should perhaps now be widened to include all lesions which require oesophageal resection and for which colonic or jejunal reconstruction is not appropriate. The only contraindication would be found in those cases where so much stomach has had to be removed that there remains insufficient tissue to reach to the neck.

Facilities and equipment were financed in part by the Nuffield Foundation and the North West Cancer Research Fund. We thank Mr. B. J. Bickford for permission to study patients under his care and the nursing staff of the Gastroenterology Unit, Broadgreen Hospital, for valuable assistance.

#### REFERENCES

- Boyd, A. D., Cukingnan, R., Engelman, R. M., Localio, S. A., Slattery, L., Tice, D. A., Bardin, J. A., and Spencer, F. C. (1975). Esophagogastrostomy: analysis of 55 cases. *Journal of Thoracic and Cardiovascular Surgery*, **70**, 817.
- Hunt, P. S., Connell, A. M., and Smiley, T. B. (1970). The cricopharyngeal sphincter in gastric reflux. *Gut*, **11**, 303.
- Lancet (1971). Resection of the oesophagus. (Editorial). *Lancet*, **2**, 30.
- McKeown, K. C. (1972). Trends in oesophageal resection for carcinoma (with special reference to total oesophagectomy). *Annals of The Royal College of Surgeons of England*, **51**, 213.

Requests for reprints to: Dr. D. W. Ward, Burnley General Hospital, Casterton Avenue, Burnley BB10 2PQ.