

Pulmonary blastoma

M. J. PEACOCK¹ and F. WHITWELL

Cardio-Thoracic Surgical Centre, Broadgreen Hospital, Liverpool

Peacock, M. J. and Whitwell, F. (1976). *Thorax*, 31, 197–204. **Pulmonary blastoma.** Pulmonary blastoma is now accepted as a distinctive neoplasm. It remains rare, and only 28 cases have been reliably recorded. A further two cases are now reported, and the previous literature is reviewed. There are no specific clinical or radiological features of pulmonary blastoma. The presentation can be that of any other pulmonary tumour although a peripheral situation is usual and a large size is often attained before detection. Pulmonary blastoma is a mixed tumour with malignant epithelial and connective tissue components with a distinctive resemblance to fetal lung. The treatment of choice is surgical excision but the overall prognosis is poor. It is doubtful whether the tumour has a true blastomatous origin.

The first example of a pulmonary embryoma, or blastoma, was described by Barnard in 1952, and three cases of this rare tumour were reported by Spencer in 1961. We have found only 24 other cases in the literature. Two further cases are now reported, and the clinical and pathological features of these 30 cases are summarized.

CASE REPORTS

CASE 1 At Darwin, in July 1969, an Australian aboriginal woman, judged to be 30 years old, was found to have a round opacity in the upper zone of the right lung in a routine chest radiograph (Fig. 1).

She admitted to a long-standing cough but denied other symptoms. Mantoux and Heaf tests were negative and many sputum examinations failed to show acid-fast bacilli. No radiological change was noted after courses of penicillin and oxytetracycline. The patient then disappeared, as is the wont of her race, but was found again nearly three years later in June 1972 by a field survey team. No further symptoms had developed and clinical examination was negative, but a repeat chest radiograph showed a considerable increase in size of the original opacity. Sputum examinations for fungi, neoplastic cells, and acid-fast bacilli were negative. It was thought that the lesion was a granuloma and, as tuberculosis is common among aboriginal people, a diagnosis of tuberculoma was considered. Treatment with

isoniazid, ethambutol, and rifampicin was therefore started, but after a further 12 months the lesion had again increased in size (Fig. 2). The patient was transferred to Adelaide where tomographs suggested central cavitation (Fig. 3).

In August 1973, following a normal bronchoscopy, thoracotomy revealed a soft, well-defined mass, 3 cm across, lying within the apical segment of the right lower lobe. There was no attachment to adjacent structures, the regional lymph nodes appeared uninvolved, and the rest of the right lung appeared normal; apical segmental resection was therefore performed.

Her postoperative course and convalescence were normal.

Surgical Specimen This consisted of a segment of lung containing a subpleural tumour, 3.5 cm across. The cut surface (Fig. 4) was white and soft and the tumour was sharply demarcated from the surrounding lung tissue, which showed some compression.

Microscopically the tumour consisted of numerous branching ducts and clefts lined by well-differentiated layers of columnar and cuboidal epithelium (Fig. 5). These epithelial elements were embedded in a cellular stroma composed of spindle cells and myxomatous tissue containing some smooth muscle fibres. In places the duct-like structures appeared to be differentiating from solid areas of pale-staining polygonal cells (Fig. 6), and in many places the ducts were lined by stratified cells (Fig. 7). These cells were regular

¹Present address: Thoracic Surgical Centre, City Hospital, Greenbank Drive, Edinburgh EH10 5SB.

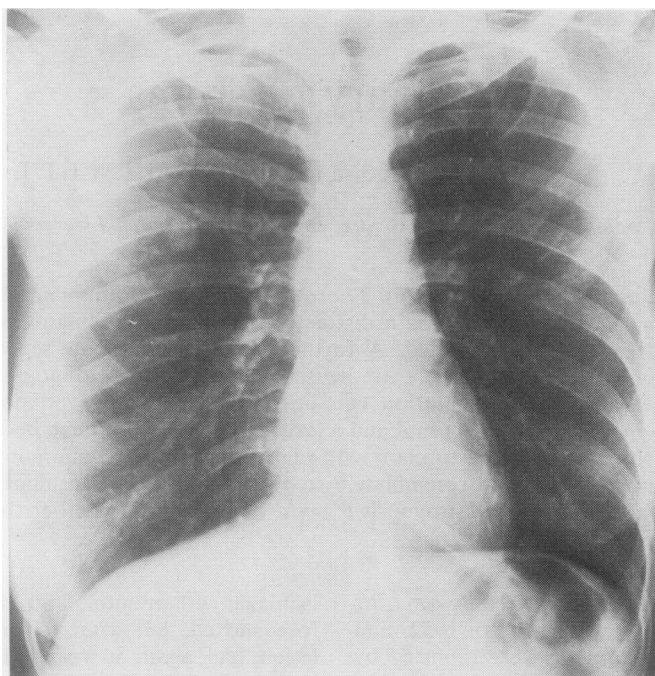


FIG. 1. *Case 1. PA chest film at time of first presentation. A rounded opacity is visible in the right upper zone.*

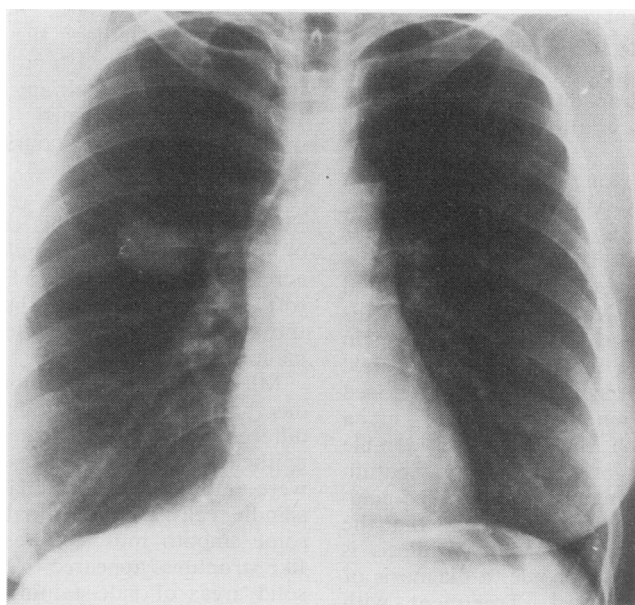


FIG. 2. *Case 1. PA chest film showing the increase in size of the lesion over a period of four years.*

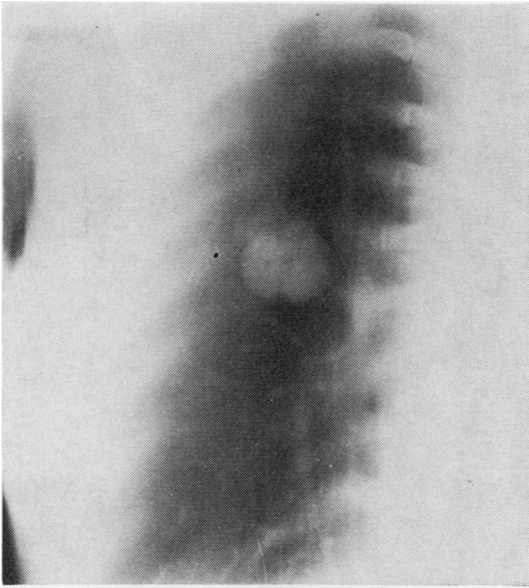


FIG. 3. Case 1. Tomographic appearance, suggesting early central cavitation. Note the well-defined margin of the opacity.

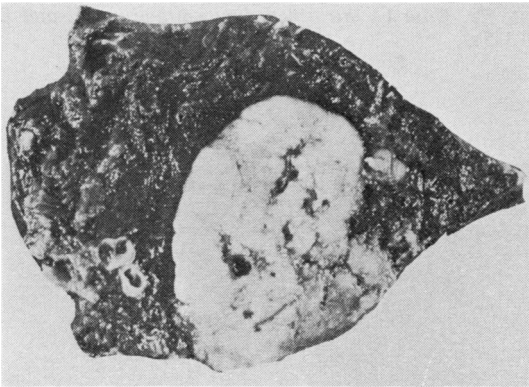


FIG. 4. Case 1. Cut surface of the resected apical segment. The lesion is clearly seen with several small areas of haemorrhage and necrosis. Although abutting on the pleural surface, the tumour has not penetrated that layer. The surrounding lung is compressed.

and showed few mitotic figures. The appearance was that of a pulmonary blastoma.

The patient was well and the chest radiograph clear six months after returning to her mission-station home. This is the first known case in Australia.

CASE 2 In June 1965, a 23-year-old soldier was admitted to a Royal Air Force hospital in

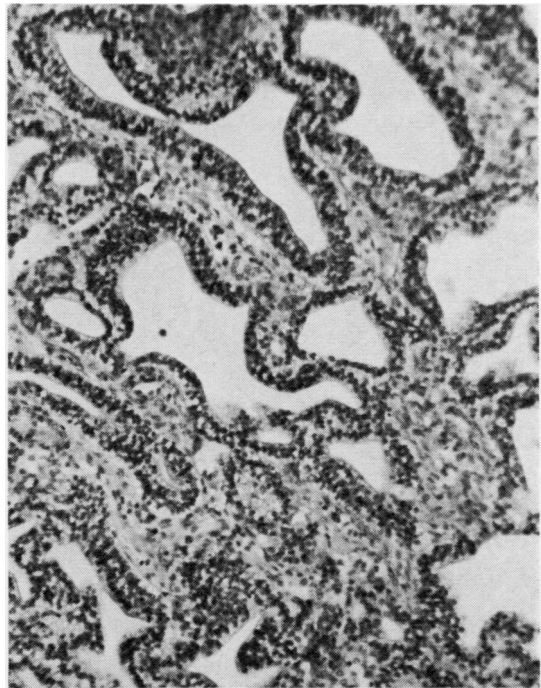


FIG. 5. Case 1. General acinar appearance of tumour (Haematoxylin and eosin $\times 85$).

Britain with fever, dry cough, and left pleuritic pain of acute onset. A chest radiograph showed a diffuse opacity in the left upper zone and a diagnosis of pneumonia was made. Response to routine treatment including antibiotics was rapid and within a few days the patient was afebrile and much improved. However, the radiographic abnormality persisted and he was transferred to Broadgreen Hospital for further investigations.

At that time he had a residual ache in the left chest and mild exertional dyspnoea, but the only abnormal finding was diminution of air entry over the whole of the upper left chest. However, the radiological opacity (Fig. 8) had increased to cover most of the left lung. Tomography showed a large bilobed mass occupying most of the left chest and compressing the main bronchus. Bronchoscopy confirmed anteroposterior flattening of the left bronchus but was otherwise negative. Pleural aspiration produced 500 ml of bloodstained fluid containing numerous large cells in small clumps, thought to be mesothelial. Sputum cytology and a Casoni test were normal, as were an intravenous pyelogram and a scalene node biopsy.

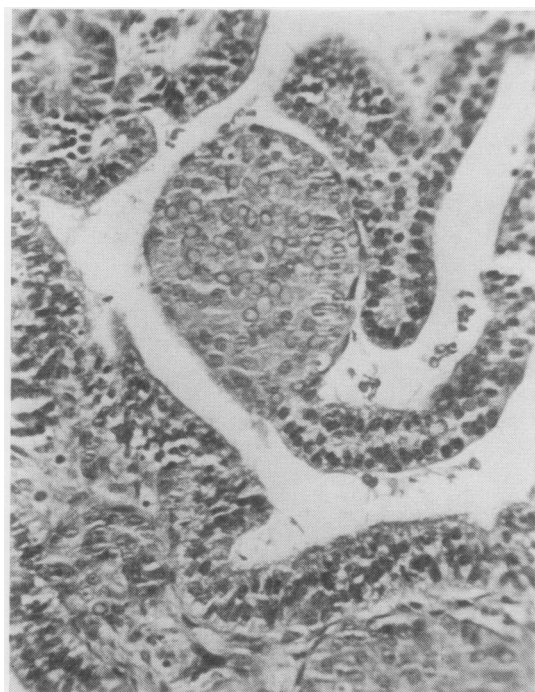


FIG. 6. Case 1. Clumps of pale-staining polygonal cells in continuity with acinar epithelium (H and E $\times 183$).

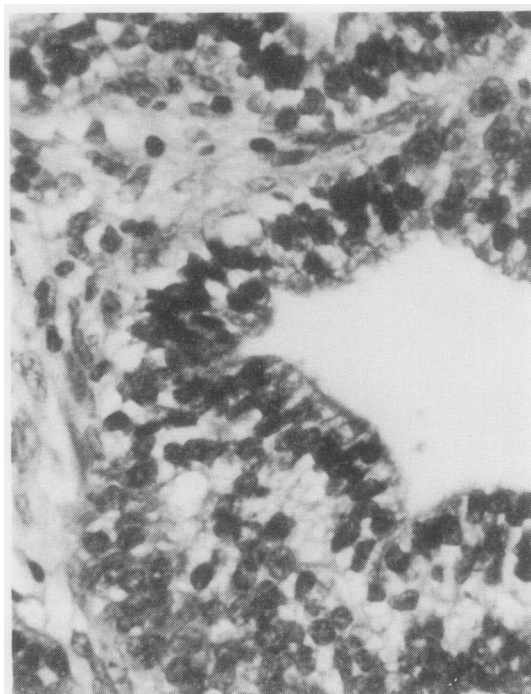


FIG. 7. Case 1. Stratified duct epithelium (H and E $\times 335$).

Six weeks after initial presentation, left thoracotomy was performed and revealed a large tumour occupying most of the left upper lobe. Residual bloodstained pleural effusion was present in loculi, but the tumour was firmly adherent to parietal pleura, including the mediastinal surface. A frozen section of the tumour was reported as 'embryoma', and pneumonectomy was performed. Mediastinal adherence made this a difficult procedure, but tumour clearance was apparently achieved and no regional lymph node involvement was noted. The patient made an uneventful recovery and after two weeks returned to the military hospital for convalescence.

Surgical Specimen The left lung was covered by thick white pleural membrane and the lobes were adherent. The upper lobe was enlarged and firm due to two masses occupying the apical and lingular areas, and the lower lobe was partially collapsed.

On section (Fig. 9) the upper lobe was almost entirely replaced by a lobulated tumour which bulged through the pleural membrane in the

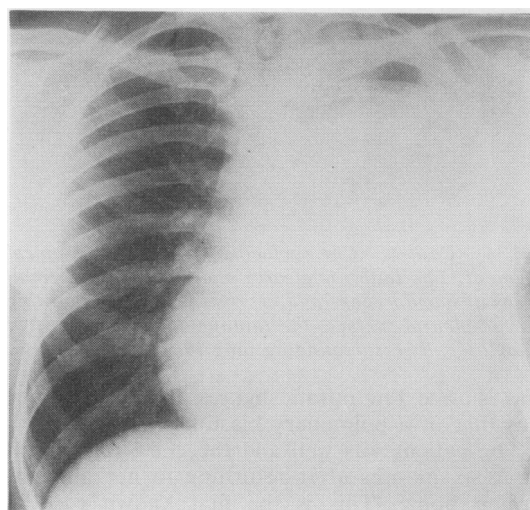


FIG. 8. Case 2. PA chest film several weeks after clinical presentation. There is a diffuse opacity over most of the left lung field with an apical fluid cap and displacement of the cardiac shadow to the right.

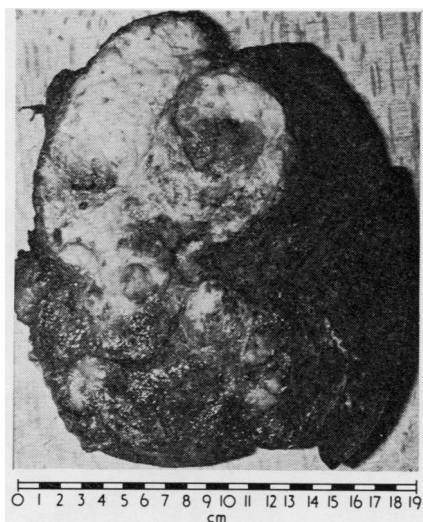


FIG. 9. Case 2. Cut surface of the left lung. The lower lobe is compressed. The upper lobe is largely replaced by white tumour in which can be seen areas of necrosis.

apical and lingular segments. The cut surface was white and slimy in places while in other areas it was granular and grey. Extensive necrosis and areas of haemorrhage were present. Bronchi were involved by the tumour but no bronchial origin could be demonstrated.

Microscopically the tumour was composed of primitive mesenchymal tissue containing numerous irregular tubules lined by columnar and cuboidal epithelial cells (Fig. 10). Some tubules and the epithelial lining cells contained mucin while other tubules were lined by hyperchromatic cells showing mitotic activity but little cytoplasm (Fig. 11). The stroma contained many smooth muscle bundles and some areas of cartilage (Figs 12 and 13). Solid polygonal-cell areas surrounded many of the tubules. The tumour was very vascular with large thin-walled blood spaces, but there was extensive necrosis. Parts of the tumour had a collagenous capsule.

The appearance was that of a malignant pulmonary blastoma.

Subsequent Course After a few weeks of reasonable health the patient rapidly deteriorated with left chest pain and increasing dyspnoea. He was readmitted to hospital where it was noted that the mediastinum was displaced to the right. Aspiration of the left pneumonectomy space produced 1800 ml of bloodstained fluid and was followed by some improvement.

Aspiration was repeated twice in the succeeding two weeks, on each occasion producing 1000 ml of fluid. Although the patient was losing weight there was no sign of metastases. However, it seemed likely that extensive local recurrence had occurred in the left chest so cytotoxic drugs were given systemically; this resulted in such symptomatic improvement that the patient was discharged home where he remained active and well for a further two months. He then developed severe chest pain, deteriorated rapidly, and died within six months of his original presentation.

At necropsy the left hemithorax was filled with necrotic haemorrhagic and cystic tumour surrounded by a litre of bloodstained fluid. The tumour had encircled the heart and infiltrated its surface. It was also involving the left hemidiaphragm, the spine, and the ribs and was infiltrating the intercostal muscles anteriorly. There was no sign of tumour spread to any other part of the body.

PATHOLOGY AND NATURE OF THE NEOPLASM

The gross and histological appearances seen in these two cases are typical of the neoplasm

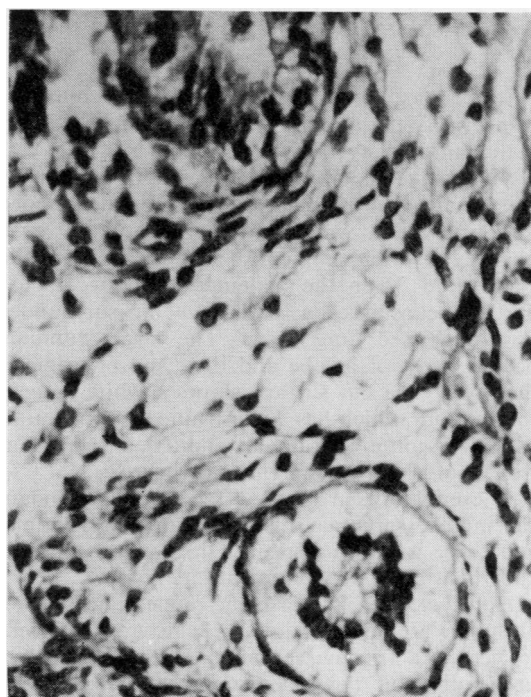


FIG. 10. Case 2. Mesenchymal tissue containing tubules (H and E $\times 335$).

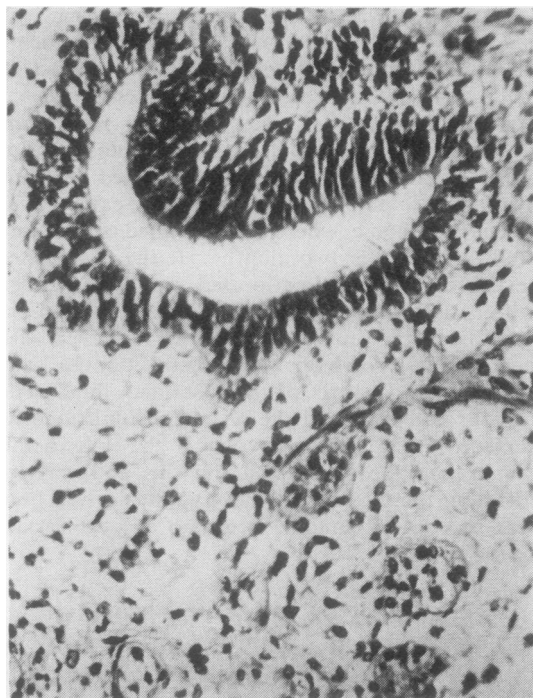


FIG. 11. Case 2. Embryonic-looking acinus in mesenchyme (H and E $\times 183$).

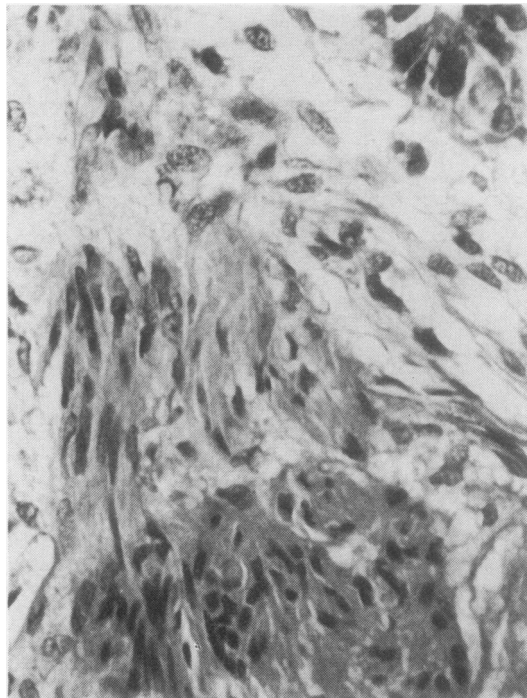


FIG. 12. Case 2. Smooth muscle bundles in tumour mesenchyme (Haematoxylin Van Gieson $\times 335$).

described as pulmonary blastoma and illustrate respectively the more benign form and the highly malignant variety.

The macroscopic appearance of pulmonary blastoma is that of a sharply demarcated, rounded tumour which, when small, is situated peripherally, is often subpleural, and has no bronchial connection. Even the malignant tumours appear partly encapsulated as well as being surrounded by compressed lung tissue. The larger tumours occupy most of a lobe and their site of origin is then lost. The cut surface shows a white or grey soft tumour which has a shiny mucoid appearance but may contain granular and friable areas as well as areas of haemorrhage or necrosis.

These features are more often seen in secondary carcinoma, sarcoma, and haemangiopericytoma, and there is nothing specific in the gross appearance of a blastoma to indicate its nature.

However, the microscopic appearances of a blastoma are usually quite specific and sufficient to permit a frozen section diagnosis. There is a uniformity of the microscopic descriptions in nearly all the published cases. The epithelium-lined tubes or tubules have a very close re-

semblance to fetal lung tissue and are quite unlike acini found in adenocarcinoma. These tubules are surrounded by primitive-looking mesenchymal stroma, which also looks neoplastic and which differentiates into fibrocytic tissue, involuntary muscle, and, occasionally, cartilage. The epithelium-lined clefts frequently end in bulbous solid nests of polygonal often clear epithelial cells.

Barnard (1952) described the first case as an embryoma, noting its similarity to a nephroblastoma, but he also called it a variety of carcinoma. Spencer (1961) also used the description of carcinosarcoma in describing the histological features of some cases, though he was the first to apply the term blastoma to these neoplasms.

In the WHO international *Histological Typing of Lung Tumours*, Kreyberg (1967) includes blastomas in group 1X, which includes mixed tumours and carcinosarcoma. In 1968 Barson, Jones, and Lodge described a case and reviewed the previously published examples. They considered that the tumour is a distinctive type of carcinosarcoma in which the epithelial element is an adenocarcinoma with a characteristic and pro-

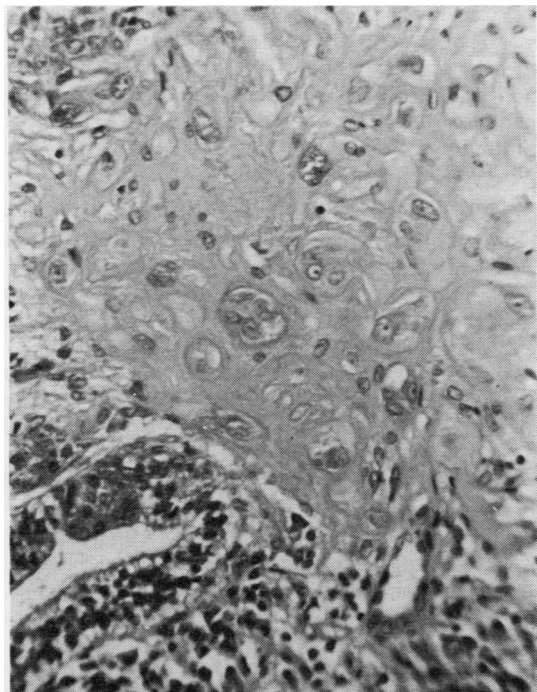


FIG. 13. Case 2. Cartilaginous change in tumour mesenchyme (H and E $\times 183$).

bably coincidental histological resemblance to fetal lung tissue. Apart from the histology of the tumour they thought that the age distribution of published cases was against the tumour having a blastomatous origin. Moreover, they say that to classify a pulmonary blastoma as a type of carcinosarcoma while retaining the blastomatous view of its histogenesis is a contradiction in terms.

Davis and his colleagues (1972) studied 10 examples of mixed tumours of the lung using the criteria set up by the WHO. The series included two cases complying with the descriptions of pulmonary blastoma, but there were also three cases where the histological appearances were transitional between carcinosarcoma and pulmonary blastoma, including squamous carcinomatous areas. These workers consider that a separate histogenesis for the different types of mixed tumours of the lung is unlikely.

In spite of the pronounced histological resemblance of these tumours to primitive lung tissue and the inclusion of cartilage and smooth muscle elements within the tumours, making them appear comparable to nephroblastoma and hepatoblastoma, we find it difficult to accept a

blastomatous origin to these tumours, largely because of the age distribution of the patients.

CLINICAL FEATURES OF 30 PUBLISHED CASES¹

AGE AND SEX DISTRIBUTION Ranging from 2 months to 77 years, the cases occur with peak incidence between 40 and 60 years of age, as shown in Fig. 14; 83% of cases occurred between 10 and 60 years of age.

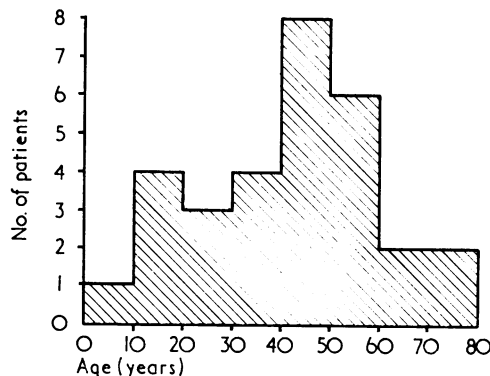


FIG. 14. Age distribution of 30 cases.

Males are affected nearly three times as frequently as females, and the mean age of the male patients is higher than that of the females, 45 compared to 36 years.

The tumour does not affect the ageing population as does bronchial carcinoma, nor does it usually occur in infants and young children as do other embryonic tumours.

PRESENTATION The commonest symptom is haemoptysis but this occurred in only 12 cases. Cough is recorded as having been present in 10 cases, and seven of the 30 lesions were detected as an unexpected radiological abnormality. As one might expect, no pattern of clinical presentation points to pulmonary blastoma.

INVESTIGATIONS Similarly, there are no specific radiological features which help to differentiate this tumour from any other pulmonary neoplasm, granuloma, etc. Sputum cytology showed malignant cells in only one instance, atypical cells were seen in two other cases, and needle biopsy, although infrequently performed, is recorded as having been positive on only one occasion.

¹Full tabulated data are available on application to the authors

Bronchoscopy findings are not recorded in seven cases but, of the remainder, tumour was visible in only six and other significant endoscopic abnormality such as bronchial distortion occurred in six others.

No additional investigation proved to be of any specific value.

SPREAD

The Table summarizes the available information.

There is no regular pattern of spread. The usual pathways seem to be utilized as for any other malignant process. However, the primary lesions, initially at least, compress the adjacent lung tissue rather than infiltrate it in contrast to carcinoma. Hilar nodes are not frequently involved (14%) and each of the four patients so affected died within several months.

There are five instances of lesions appearing in either the opposite lung or in another part of the originally affected lung, but it is impossible to say whether these are additional primary lesions or whether they represent metastatic spread.

TABLE
SPREAD

Extent at Time of Treatment or Presentation	Number of Cases	Subsequent Course
None	19	4 died from surgical complications 1 died from incidental disease 4 subsequently developed distant metastases 10 free from spread at time of reporting
Hilar nodes	4	All died within several months, 2 with distant metastases
Local, within the chest	5	Only 1 survived more than a year; 1 developed distant metastases
Distant	2	Although 1 had multiple lesions in both lungs, he remained well for 24 years

TREATMENT

In most cases, treatment has been surgical, 10 undergoing pneumonectomy, 11 lobectomy, and three lesser pulmonary resections. The remaining

six patients had cytotoxic agents, radiotherapy or no treatment at all, and the longest survival in this group of poor-risk patients was seven months. Obviously the generally accepted treatment is surgical removal, lobectomy being the minimum recommended.

PROGNOSIS

Although follow-up figures are obviously not complete, a number of observations can be made.

Seventeen of the 30 patients died, 10 from causes directly related to the tumour itself, in less than one year from presentation.

Three of the surviving patients were known to have local or metastatic spread. This leaves only 10 patients known to be alive with no clinical evidence of spread at the time of reporting.

Only five patients are known to have survived five years or more.

There are several instances of slow growth observed radiologically over a number of years, so the pulmonary blastoma, like other neoplasms, has a variable growth rate in different individuals.

We wish to thank Mr. D. R. Craddock, Dr. R. Hunter, and Dr. R. Rowland for assistance with case 1 and Mr. B. J. Bickford and Wing Commander P. Robertson for assistance with case 2.

REFERENCES

- Barnard, W. G. (1952). Embryoma of lung. *Thorax*, **7**, 299.
- Barson, A. J., Jones, A. W., and Lodge, K. V. (1968). Pulmonary blastoma. *Journal of Clinical Pathology*, **21**, 480.
- Davis, P. W., Briggs, J. C., Seal, R. M. E., and Storrington, F. K. (1972). Benign and malignant mixed tumours of the lung. *Thorax*, **27**, 657.
- Kreyberg, L. (1967). *Histological Typing of Lung Tumours*, p. 20. WHO, Geneva.
- Spencer, H. (1961). Pulmonary blastomas. *Journal of Pathology and Bacteriology*, **82**, 161.

Requests for reprints to: M. J. Peacock, FRCS, Thoracic Surgical Centre, City Hospital, Greenbank Drive, Edinburgh EH10 5SB.