Thorax (1971), **26**, 424.

Maintenance of chest wall stability: a further report

B. T. LE ROUX and P. STEMMLER

The Thoracic Unit, Wentworth Hospital, Durban, and the Department of Surgery, University of Natal

The need to maintain stability of the chest wall with stainless steel strips in three unusual sets of circumstances is explained. That 'flail' chest is not synonymous with 'stove-in' chest is made clear.

Some of the problems which relate to the maintenance of chest wall stability were discussed in a previous paper (le Roux, 1964). In respect of restoration of rigidity of the chest wall after resection of rib and sternal tumours, acrylic resin has now been used in 58 patients. Rigidity has been effectively restored in all. In three cases, one illustrated (Fig. 1 a–c), the prosthesis has had to be removed after three months because of persistent infection in relation to it. After removal of the prosthesis in these three patients, the chest wall was stable and a further manoeuvre aimed at maintenance of stability was not necessary.

In the previous paper on this subject, mention was made of the use of stainless steel struts to support the sternum after correction of pectus excavatum (Paltia, Parkkalainen, Salamaa, and Wallgren, 1959 ; Adkins and Blades, 1961 ; Jensen, Schmidt, and Garamella, 1962). There are commercially available steel struts (Jensen *et al.*, 1962) made of specially annealed cold rolled alloy 302 surgical stainless steel, in lengths which range from 14 to 41 cm, and 12 to 14 mm in breadth. Three unusual sets of circumstances made it necessary to use similar struts[1], since techniques of maintenance of chest wall stability previously described were thought likely to prove unsatisfactory.

The purpose of this paper is to describe the three cases in which stainless steel struts were used to maintain chest wall stability.

CASE REPORTS

CASE 1 A woman of 28 years had a severe degree of pectus excavatum. In addition there was a deep depression in the left anterior chest wall, immediately below an unusually small left breast. Mobilization of the sternum, resection of deformed costal cartilage, and dicing of deformed left ribs rendered the chest wall unstable, and the manoeuvre aimed at maintenance of stability after correction of pectus excavatum usually employed (a Steinmann's pin laid across the gap created by excision of deformed cartilage, deep to the sternum, and superficial to the lateral ribs) was inappropriate because of the instability of the left lower ribs on which the pin would have needed to rest. A stainless steel strut, suitably curved, was so placed, deep to the sternum and the mobilized left chest wall, and superficial to right-sided ribs and unmolested left ribs, posteriorly, that the desired shape of the thoracic cage was achieved, with stability. Convalescence was uneventful. An early postoperative radiograph is shown (Fig. 2). The strut was a source of pain after 16 weeks. The left posterior extremity of the strut was palpable deep to the skin, close to the long muscles of the back. Under local anaesthesia a small incision was made over the extremity of the strut which was easily and painlessly delivered, grasped in an artery forcep. The chest wall deformity remained corrected.

CASE 2 A labourer fell from the third floor of a building under construction, and landed with the left lateral chest wall straddling a baulk of timber. On admission to hospital the patient was little disturbed. Beyond an almost total left traumatic thoracoplasty he had few injuries, none more severe than bruising with abrasions. Remarkable was the absence of any evidence of paradoxical movement of the left chest wall. A radiograph made on admission (Fig. 3) shows the extent of traumatic thoracoplasty. That this patient had a 'stove-in' chest is unquestionable, as is the fact that he did not have a 'flail' chest. Surgical management was undertaken two days after injury, during which interval he had been entirely well, without evidence of embarrassment of respiration, and with normal blood gases. The purpose of an operation was to correct the thoracoplastic deformity which was judged radiographically to be of an extent which reduced by more than half the effective function of the left lung.

Through a left thoracotomy the inwardly displaced ribs, all fractured in more than one place, were disimpacted and mobilized. This manoeuvre converted the 'stove-in' chest to a 'flail' chest injury. Four stainless steel struts, so shaped that they conformed with the convexity of the left chest wall, were placed external to the ribs to which they were held by a

[1]Made at short notice in the workshops at Wentworth Hospital, Durban, by Mr. S. S. Andrew

number of interrupted silk sutures. An early postoperative radiograph is shown (Fig. 4). The left chest wall was stable from the time of recovery of consciousness at the end of the operation. Convalescence was uneventful. The anterior ends of the two rostral steel struts became easily palpable subcutaneously and were a source of pain. All four struts were removed six months after operation, through small incisions in relation to the anterior ends of the struts under general anaesthesia. The struts, grasped in an artery forceps, slipped easily from their beds. The chest wall has remained stable and the patient has returned to work. A chest radiograph made after removal of the struts is shown (Fig. 5).

CASE 3 A 17-year-old boy presented with an unusually large tumour of the left chest wall (Fig. 6). At the apex of the tumour skin was invaded and a biopsy showed the lesion to be a chondrosarcoma. Through an elliptical incision, which skirted the lower border of the tumour, this was excised including most of the six related ribs. Although some skin had to be sacrificed because of tumour invasion, enough was left to cover the gap, so stretched had the skin become over the tumour. Posteriorly, ribs were excised medial to the costotransverse joint. The lung was not invaded. So large was the resultant chest

(a)

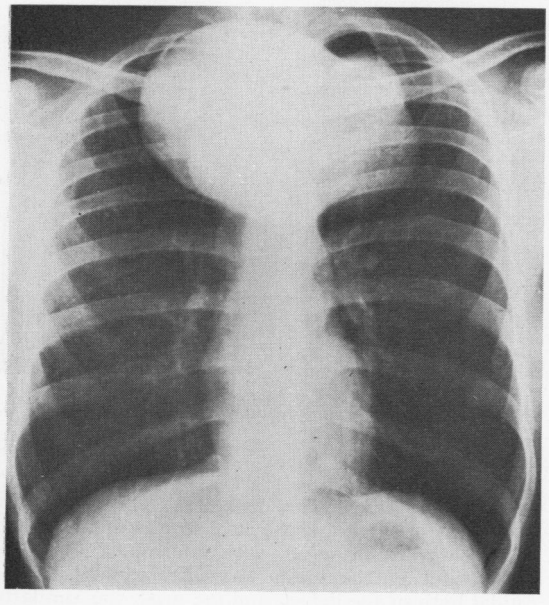

(b)

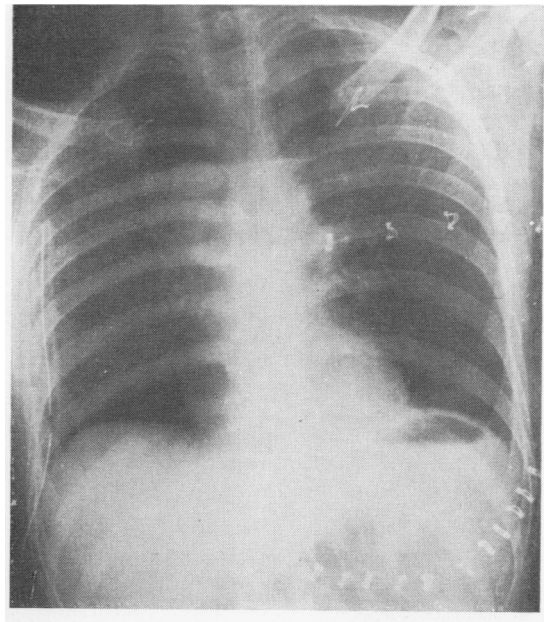

(c)

FIG. 1. *Clinical photograph (a) shows an osteoclastoma growing from the manubrium sterni, involving the medial ends of both clavicles and the first and second costal cartilages of both sides. The tumour was excised; the osseous defect was repaired with acrylic and the cutaneous defect with a skin flap; (b) preoperative chest radiograph; and (c) early postoperative chest radiograph. The acrylic was secured to the clavicles with wire. The Michel clips indicate the extent of the skin flap. There is a fluid level in the early postoperative films. A boggy swelling persisted in relation to the acrylic. Fluid aspirated, although serious, was shown to contain staphylococci. The abscess in relation to the acrylic persisted and this was removed after three months. The chest wall was, by this time, firm, and recovery was thereafter uneventful.*

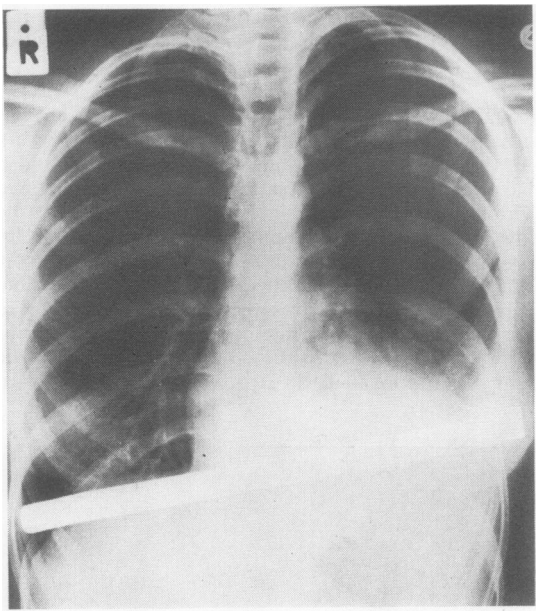

FIG. 2. *Case* 1. *The stainless steel strip used to support the sternum and left lateral chest wall.*

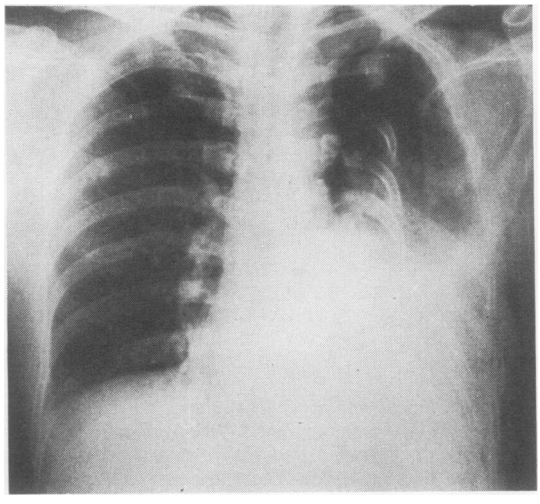

FIG. 3. *Case* 2. *The extent of left traumatic thoracoplasty is shown.*

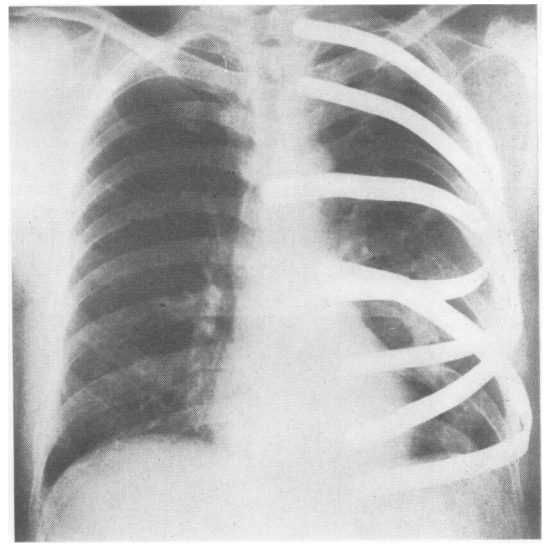

FIG. 4. *Case* 2. *An early postoperative radiograph of the patient whose traumatic thoracoplasty was mobilized and secured with stainless steel strips.*

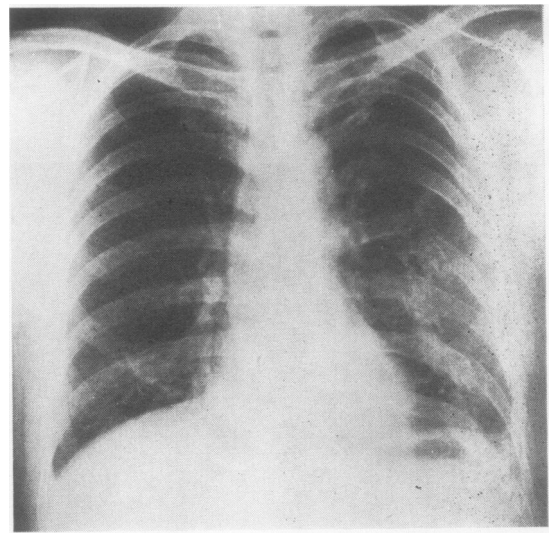

FIG. 5. *Case* 2. *A radiograph after removal of the stainless steel strips.*

wall deformity that there was not available sufficient acrylic resin to make a plate large enough to be effective. Four steel struts were appropriately curved and anchored anteriorly and posteriorly with silk sutures. Marlex mesh was anchored by interrupted silk sutures to the rib which constituted the rostral limit of the defect. The distal limit of the Marlex mesh was held taut and the steel struts were anchored to the Marlex, in series, with interrupted silk. The distal limit of the mesh was then secured to the caudal limit of the defect, and the mesh was similarly secured anteriorly and posteriorly. In effect, the defect

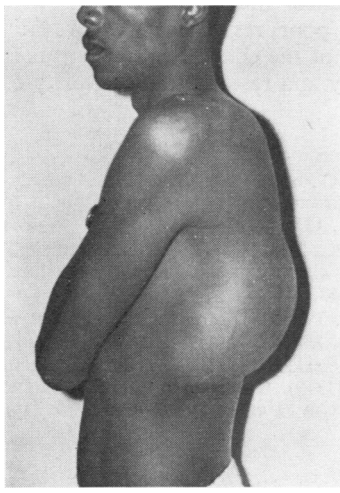

FIG. 6. *Case 3. The extent of the chest wall chondrosarcoma is shown.*

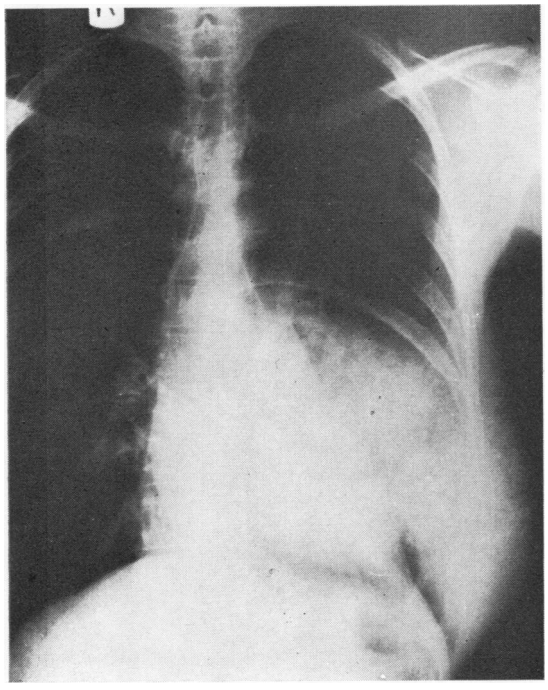

FIG. 7. *Case 3. Preoperative anteroposterior radiograph showing extent of rib destruction from the chondrosarcoma involving the left lateral and posterior chest wall.*

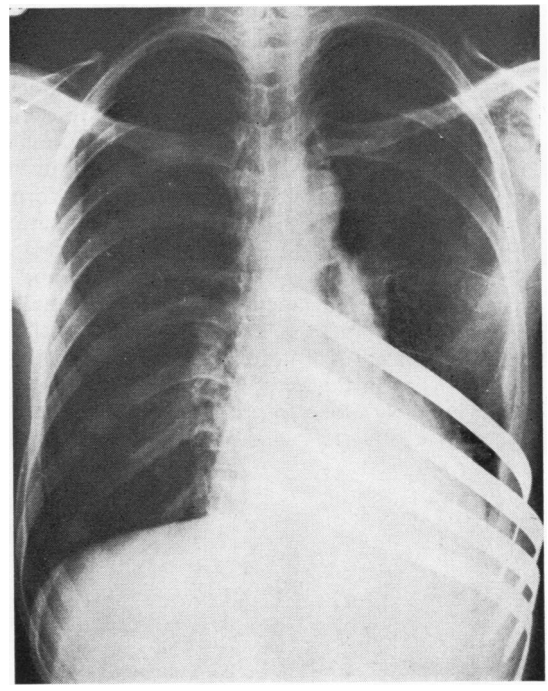

FIG. 8. *Case 3. An early postoperative radiograph after excision of the chondrosarcoma and replacement of the chest wall with Marlex mesh and stainless steel strips.*

was covered with a curtain of Marlex supported and given an appropriate contour to simulate the normal lateral convexity of the thoracic cage by four stainless steel struts. Convalescence was uneventful; the chest was stable throughout and the patient remains well. A preoperative postero-anterior radiograph and an early postoperative radiograph are shown (Figs. 7 and 8).

DISCUSSION

The unusual combination of pectus excavatum with a deep depression of the left anterolateral chest wall in case 1 prevented the use of a Steinmann's pin to render stable the chest wall after mobilization of the sternum. In case 2, 'stove-in' chest was converted to 'flail' chest at operation to correct a severe degree of traumatic thoracoplasty. Rather than manage surgically induced 'flail' chest with intermittent positive pressure ventilation in a patient pharmacologically rendered apnoeic, it was elected to achieve stability with stainless steel struts, since a thoracotomy had already been made. The unusual size of the defect in the chest wall, necessary for complete removal of a large tumour, in case 3, demanded the use of

an alternative technique for maintenance of chest wall stability since insufficient acrylic resin was available. Marlex is a polyethylene with a high tensile strength easily made into a monofilament from which mesh can be made. It is said to excite less foreign body reaction than, for example, Dacron, Orlon or nylon and is not rejected in the presence of infection. It is available in two forms —a fine, pliable mesh (used in the operation described) available in large sheets (10×14 in ($25{\cdot}4 \times 35{\cdot}6$ cm) and called heavy gauge); and a coarser, more rigid mesh available in smaller sheets (6×6 in ($15{\cdot}2 \times 15{\cdot}2$ cm) and called tracheal mesh). A sheet of Marlex, stretched tautly, to cover the gap in the chest wall in this patient was judged unlikely alone to prevent paradox in early convalescence, and would have resulted in a cosmetically poor result because of the inevitable flattening of the chest. The steel struts contributed to security and restored the convexity of the chest wall.

REFERENCES

Adkins, P. C., and Blades, B. (1961). A stainless steel strut for correction of pectus excavatum. *Surg. Gynec. Obstet.*, **113**, 111.

Jensen, N. K., Schmidt, W. R., and Garamella, T. J. (1962). Funnel chest: a new corrective procedure. *J. thorac Surg.*, **43**, 731.

le Roux, B. T. (1964). Maintenance of chest wall stability. *Thorax*, **19**, 397.

Paltia, V., Parkkalainen, K. V., Salamaa, M., and Wallgren, G. R. (1959). Operative technique in funnel chest. Experience in 81 cases. *Acta chir. scand.*, **116**, 90.