

# The anatomy of the sinus of Valsalva

KENNETH REID

*Nuffield Department of Surgery, The Radcliffe Infirmary, Oxford*

The anatomy of the aortic root has been studied in different species, and common structural features of importance have been detailed. The findings confirm the universal presence of a well-marked ridge limiting the distal extent of the aortic sinuses. Redefining the sinuses in this way shows that normally the coronary ostia lie within the sinus proximal to the ridge and it appears that their position relative to the ridge is related to an animal's fleetness. Aortic cusps in the fresh state have no recoil tendency to bring them into apposition but lie in a collapsed open position. It is suggested that prosthetic outflow valves should imitate the normal valve in this important respect.

The need for accurate knowledge of the aortic root is imperative not only as replacement of diseased aortic valves becomes established surgical practice but also as many of the hitherto accepted ideas concerning coronary blood flow have to be discarded. The early optimism which attended the use of valve prostheses and homo- and heterograft valve substitutes has been to a major extent tempered by later experience, and, although the outlook remains encouraging, it is clear that all valve replacements currently being used fall far short of the ideal. More precise knowledge is essential if further progress is to be made, and this applies especially to the design of future valve prostheses both for replacement and for heart substitute pumps. Additional information about aortic root fluid dynamic events will give an important insight into the way in which coronary blood flow is maintained when severe demands are made on the heart during strenuous exercise and how it may be diminished by a variety of disease processes. This anatomical study was undertaken as a critical and complementary part of a flow study project designed to elucidate the function of the sinus of Valsalva and of the aortic valve closure mechanism (Reid and Bellhouse, 1968a).

## HISTORICAL

The earliest documented interest in the sinus of Valsalva dates from the Renaissance with the description and drawings of Leonardo da Vinci (1513). However, whilst his notes indicate intense theoretical interest in the possible role of the aortic sinus in the closure mechanism of the valve, his drawings of the sinus remain diagrammatic

and he chooses to ignore the position of the coronary arteries (Fig. 1). In passing, it is of interest that Leonardo outlines a method for the construction of a glass model of the aortic root so that the movements of fluid within the sinuses can be closely observed using dye studies. In 1740 was published the first anatomical account of the aortic sinuses (Valsalva, 1740). Valsalva was struck by the uniform presence of sinuses in a variety of birds and mammals and concluded that they must serve a common purpose in all these creatures. He suggested that their main function was to dissipate the violence of systolic contraction by allowing blood to enter the sinuses during systole. His account goes on to relate the sinuses to coronary artery filling, suggesting that this takes place in diastole. While Valsalva gives a detailed description of the valve cusps, somewhat surprisingly, a detailed account of the configuration of a sinus is omitted.

Since 1740, surgical interest in the sinus has been limited to the relatively rare condition of aneurysmal dilatation, most commonly affecting the right and non-coronary sinuses (Hudson, 1965; Burchell and Edwards, 1951). Anatomical descriptions stemming from this give good detailed accounts of the topography of the sinuses in man, although again omitting details of the sinuses themselves (Edwards and Burchell, 1957). A recent study gives a careful histological picture of the aortic root in the dog and also compares the size and position of the right and left coronary ostia (Boucek, Takashita, and Fojaco, 1964). However, because the sinuses themselves lack precise anatomical definition in standard and specialized texts, being invariably described as 'slight dilatations of

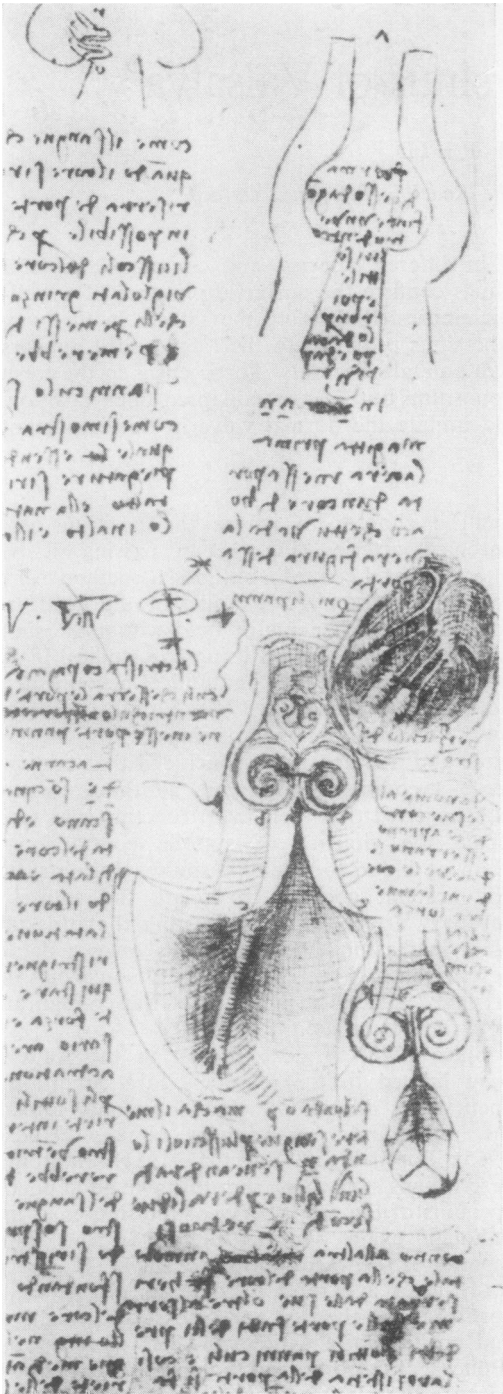


FIG. 1. Drawing of aortic root and glass model by Leonardo da Vinci.

the aorta' (Davies and Davies, 1962), there remains some confusion about the site of the coronary ostia. Edwards and Burchell (1957), in a detailed monograph, do not include the coronary openings within the sinus at all, Boileau Grant and Basmajian (1965) rather ambiguously state that the coronary arteries have their opening just below the level of the free edges of the cusp without stating whether the cusps are open or closed, while Gray's Anatomy (Davies and Davies, 1962) is categorical in stating that the coronaries arise from the level of the attached margin of the cusps and illustrates the openings in two figures, one showing the ostia above and the other below the highest point of the commissures. This confusion derives in part from individual variation, from the examination of dissecting room specimens in which the valve cusps are retracted and shrunken and have therefore a misleading appearance, and from the fact that the sinus is not envisaged as having an anatomically well-defined upper margin.

GENERAL DESCRIPTION

In this study the geometry of the sinus of Valsalva has been compared using material obtained from the sheep, the pig, the dog, the ox, and man. Fresh hearts were incised and the geometry of the aortic root was measured. In addition to measuring the diameters indicated in Fig. 2 and the Table, the form and height of the valve cusps were noted and the position of the coronary ostia was recorded. Where necessary, casts were made to illustrate anatomical features that were not readily apparent and easily measured using fresh tissues. When the results from different animals

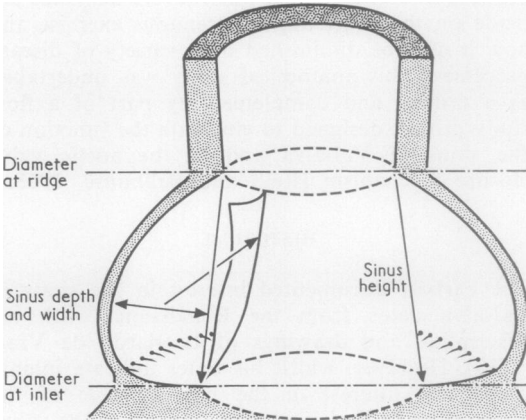


FIG. 2. Diagrammatic section of aortic root.

TABLE

PROPORTIONS OF THE AORTIC ROOT FOR A RANGE OF ANIMALS AND MAN: MEAN VALUES

Animal	No. in Sample	Heart Wt. (g.)	Inlet Radius Ridge Radius	Sinus Depth Ridge Radius	Sinus Width Ridge Radius	Sinus Height Ridge Radius	Cusp Height Ridge Radius
Human (fixed material)	6	285	1.34	0.94	1.06	2.70	—
Ox	6	1,295	1.33	0.75	0.75	1.86	1.35
Pig	7	212	1.45	1.03	0.96	1.92	1.51
Sheep	10	174	1.49	0.89	0.87	1.72	1.39
Dog	4	102	1.45	1.05	0.92	2.00	1.38
Rabbit	4	—	1.40	1.05	1.05	2.00	—
Mean for all animals			1.41	0.94	0.92	2.00	1.45

are compared several striking features emerge that enable a definitive picture of an aortic sinus to be constructed.

The constancy of the proportions of the aortic root geometry in the different species is remarkable, despite a 10-fold difference in heart weight. The measurements reveal that the root of the aorta represents a truncated cone, so that at the level of the highest point of attachment of the cusps the diameter of the aortic orifice has been reduced by between 15 and 20%. The aortic orifice, being fibrous or, in the case of the ox and sheep, partially bone, remains effectively unchanged during the cardiac cycle, whereas the other aortic diameters expand with systole. The effective reduction during systole may therefore be rather less than the 15 to 20% reduction noted in excised hearts. Nevertheless, it is probably correct to think that functionally there is a slight but significant reduction in the aortic diameter at the highest point of the commissures. This means that in all probability the valve cusps are swept forward during systole so as to lie with the mid-point of the tip just within the shoulder formed by this reduced diameter, and indeed this has been observed in later experiments.

The measurements in addition reveal that the greatest depth of a sinus at its mid-point is approximately half the diameter of the aorta at the same point. In other words, the sinuses at their greatest depth lie on a circle with a radius twice that of the aorta. The lateral extent of the sinuses is therefore very considerable, and the standard description of them as 'slight dilatations' is incorrect. Moreover, the floor of the coronary sinuses is formed to a major extent by the muscular shoulder of the interventricular septum with the lowest point of attachment of the valve cusps being to muscle and not to the fibrous annulus. By this means the depth of a sinus is maintained in all movements of the heart and aorta. This situa-

tion does not apply to the non-coronary sinus, and it was noted that its associated cusp was sometimes rather larger than the other two cusps. The appearance of the valve cusps in dissecting room specimens can be unreliable, since they are always rigid and shrunken. In the fresh state, however, the valve cusp lies collapsed in an open and not in the closed position so frequently assumed, so that when it is gently extended it can readily be appreciated that in systole the cusp very nearly occludes its sinus, so that the highest point of the cusp tip is close to the highest point of the commissures (Figs 3 and 4).

It might be argued that if the upper limit of the sinus is anatomically poorly defined, then measuring the height of the sinus would be liable to considerable error. However, one of the most striking features in all the hearts examined was the constancy of a well-defined ridge arching between the highest point of attachment of the cusps. This ridge, although a distinct anatomical feature, has not previously been described, yet it seems to be the natural upper margin of the sinus and is sufficiently pronounced to make visualization of the ostia from above extremely difficult (Figs 5 and 6). It must be emphasized that the ridge represents more than the slow curving shoulder naturally formed by the junction of the aorta and the sinus dilatation, and is generally characteristically shaped and quite sharply angled. A similar ridge is also a prominent feature of the pulmonary sinuses, although it is not so readily seen after death when the vessel is empty and flaccid. The ridge, which is easily palpable if the moist vessel wall is allowed to slip between the finger and thumb, coincides with a reduction in aortic diameter already described, and at this point the wall of the aorta is some four to five times thicker than the wall of the sinus a few millimetres below it, the reduction in thickness being mainly borne by the tunica media. It was noted in elderly hearts



examined in the dissecting room that the ridge itself was often the site of atheromatous formation while the adjacent parts of the sinus and aorta were free of disease (Fig. 7). The ridge forms a fixed anatomical point of reference for describing the position of the coronary ostia. Thus, out of 27 hearts examined at necropsy, on no occasion

did the coronaries arise above the ridge, in 20 the ostia arose just below it, in three the ostia coincided with the ridge, while in four the ostia were rather lower in the sinus. The larger left coronary ostium often seemed lower in the sinus than its smaller fellow. Its superior margin, however, was usually at the same level relative to the ridge as

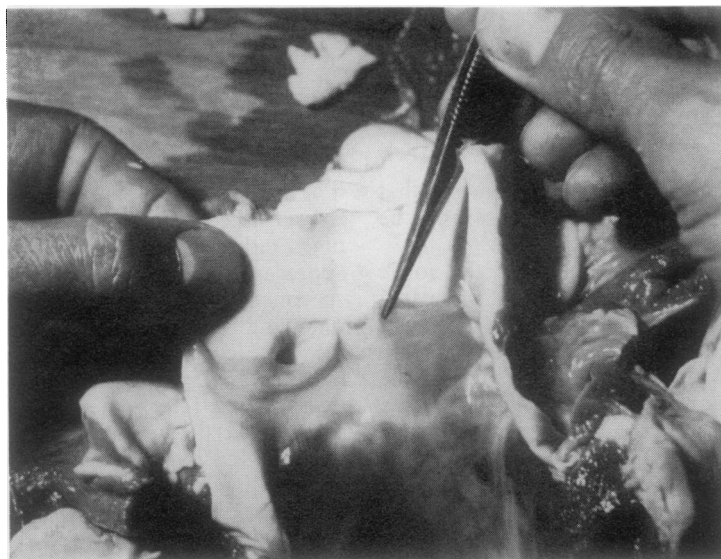

FIG. 3. *Ox aorta. Cusp gently extended.*

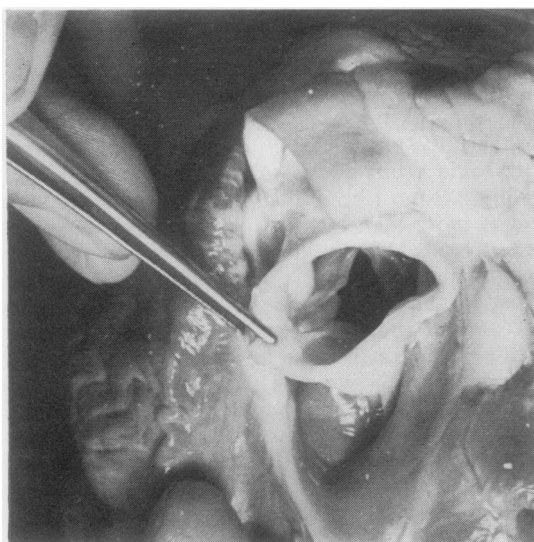


FIG. 4. *Pig heart. Cusps lie collapsed in an open position.*

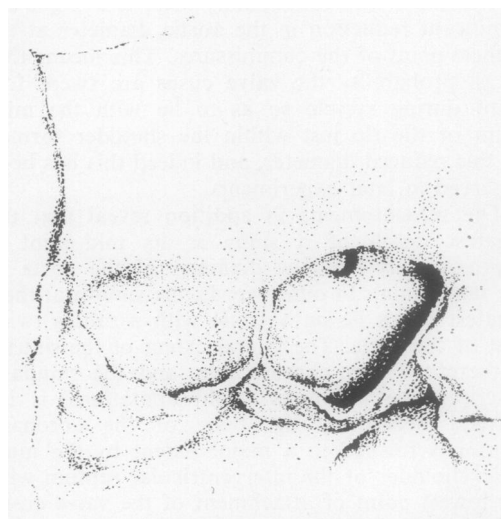


FIG. 5. *Human aortic root (opened). High position of coronary ostium.*

## *The anatomy of the sinus of Valsalva*

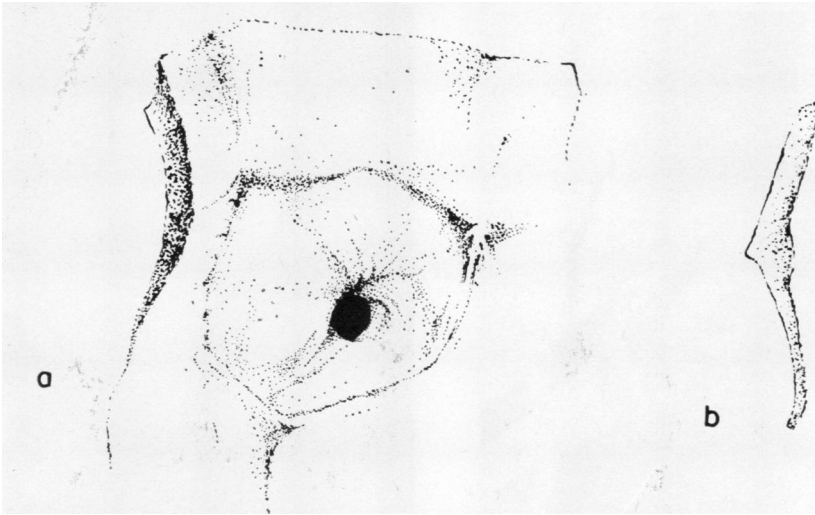


FIG. 6. (a) *Ox aortic root. Low position of ostium.* (b) *Human sinus ridge in profile.*

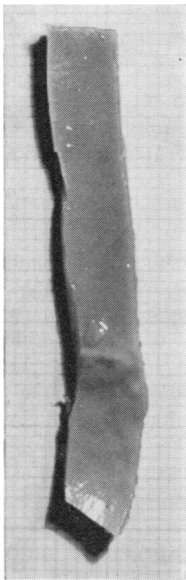


FIG. 7. *Excised portion of 66-year-old male aortic root showing atheroma at sinus ridge (human).*

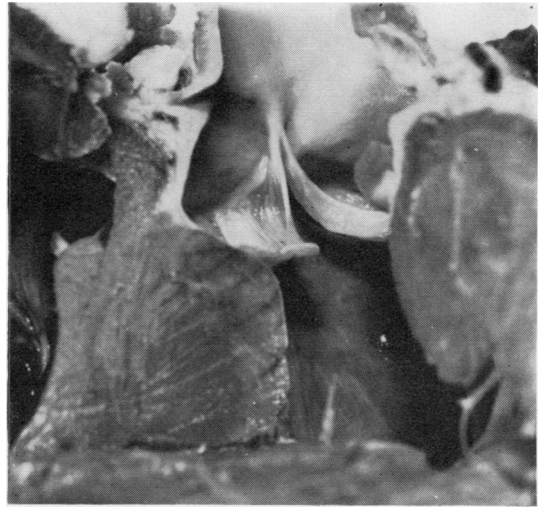


FIG. 8. *Aortic root of dog. Note extent of sinus floor formed by interventricular septum and high position of coronary ostium.*

that of the right coronary artery. The direction of the coronary arteries as they leave the sinuses is always towards the apex of the heart (Fig. 8). This means that the inferior or proximal margin of the coronary ostium presents in its turn a promontory against which fluid circulating in the sinus can abut. It was of great interest that in the group

examined the fleetest of the animals, namely the dog and man, demonstrated the highest position of the coronary ostia (Fig. 9).

While no systematic study of the pulmonary root has yet been undertaken, the pulmonary artery was frequently incised at the same time as measurements of the aorta were being made. The presence of a ridge was confirmed and the general configuration appeared to parallel closely the





FIG. 9. Cast of aortic root (dog).

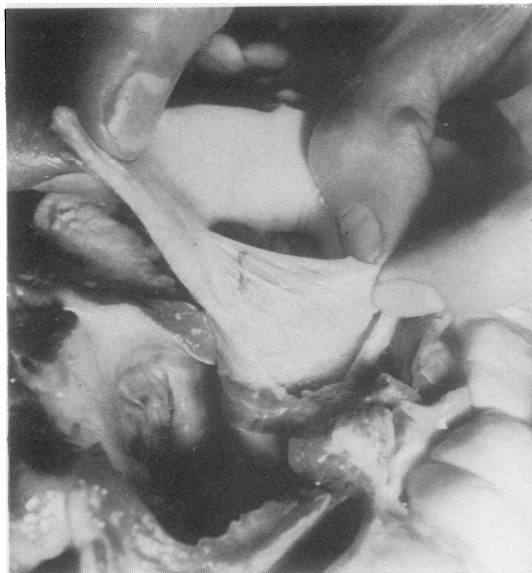

FIG. 10. Posterior aspect of ox cusp showing stranded arrangement of reinforcing fibres.

aortic situation. However, the pulmonary root after death collapses and its shape is lost. The depth of the sinuses was therefore observed in the anaesthetized dog at operation, when they appeared to be of the same order relative to the pulmonary artery as the aortic sinuses to the aorta.

The commissures were also examined in the group of animals studied. Cleland (1964), discussing the surgery of the aortic valve, states that the valve cusps are attached to each other for a distance of 1 to 2 mm. at the base (the highest point of attachment of the valve cusp) where the two cusps run together. In this series, while a very few animals and man occasionally demonstrated macroscopic interlacing of fibres between the cusps, this was not the general arrangement. The inter-digitating collagenous fibres of adjacent cusps and the aortic wall combine to produce a slight but palpable ridge just below the highest point of the commissures dense enough to give a gritty sensation when incised with a scalpel. Despite this, the cusp flaps themselves remain quite separate from one another. The point at which the cusps were most intimately associated is not at the base, the point of insertion of the relatively non-fibrous lunule, but below this, where the denser contact surfaces of the cusps insert. It was often noted that at this same point, but on the sinus surface of the valve cusp, one or two of the principal fibre bundles forming the supporting

tissue of the cusp were frequently quite separated from the cusp although they always inserted into the cusp before reaching the node (Fig. 10).

#### DISCUSSION AND CONCLUSIONS

The more or less identical geometry of the aortic root together with so many other common anatomical species strongly suggests that the haemodynamics of the region in different species may also be closely parallel. Moreover the form and features of the pulmonary root make it seem likely that similar root fluid events occur in this situation. Direct observations of aortic roots in the fresh state confirm the universal presence of a sinus ridge limiting the distal extent of the sinus of Valsalva and indicate that the valve cusps have no significant elastic recoil tending to bring them into apposition but lie collapsed in an 'open' position. It follows from this that some other mechanism in life operates so as to achieve valve closure. It seems likely that many of the complications that have attended the use of aortic valve prostheses that utilize a tri-leaflet principle, notably fatigue and embolic problems, stem from an inherent design fault whereby the leaflets have been made in such a way as to spring back into a closed position (Hufnagel, 1969; Hittmann, 1966). All these prosthetic valves are associated with pressure gradients across them

and marked degrees of turbulence, both indicative of valvular stenosis (Reid and Bellhouse, 1968b). Likewise, the presence and importance of the sinus ridge as inherent in aortic valve geometry has not been fully appreciated. The coincidental observation that the coronary ostia always lie within the sinus of Valsalva as redefined suggests that systolic coronary blood flow is more important than is generally assumed. Especially significant is the different location of the ostia relative to the sinus ridge in fleet and grazing animals. The suggestion is that the fleetest animals have ostia most favourably placed near the ridge so as to exploit the 'ram' effect of blood leaving the ventricle in systole. It seems reasonable to assume that the aortic sinuses are therefore a means of ensuring that the coronary arteries are kept primed with blood during systole (this is borne out by observation of cine-angiograms), regulate coronary flow responses during exercise (Van Citters and Franklin, 1969; Gregg, 1963), and act as pressure recovery chambers initiating valve closure during the latter part of systole. It follows that disruption of aortic root geometry by either disease or surgery would be accompanied by reduction of systolic coronary blood flow and defective valve closure, effects that would be more marked with exercise.

It is suggested that outlet non-return check valves as prostheses should be designed so as to reproduce the essential anatomical features of the

aortic root, namely cusps that at rest lie in the fully open position and are in important relation to a sinus ridge.

## REFERENCES

- Boucek, R. J., Takashita, R., and Fojaco, R. (1964). Functional anatomy of the ascending aorta and the coronary ostia (dog). *Amer. J. Anat.*, **114**, 273.
- Burchell, H. B., and Edwards, J. (1951). Aortic sinus aneurysm with communications into the right ventricle and associated ventricular septal defect. *Proc. Mayo Clin.*, **26**, 336.
- Cleland, W. P. (1964). The surgery of the aortic valve. In *Recent Advances in Surgery*, 6th ed., Ch. 10, p. 186. Ed. Taylor, S. Churchill, London.
- Davies, D. V., and Davies, F., ed. (1962). *Gray's Anatomy, Descriptive and Applied*, 33rd ed. Longmans, London.
- Edwards, J. E., and Burchell, H. B. (1957). The pathological anatomy of deficiencies between the aortic root and the heart, including aortic sinus aneurysms. *Thorax*, **12**, 125.
- Grant, J. C. Boileau, and Basmajian, J. V. (1965). Heart and pericardium. In *Grant's Method of Anatomy*, 7th ed., p. 500. Williams and Wilkins, Baltimore.
- Gregg, D. E. (1963). Physiology of the coronary circulation. *Circulation*, **27**, 1128.
- Hittman Associates Inc., Baltimore, Maryland (1966). *Analytical Report on Six Studies Basic to Consideration of Artificial Heart Programme*, Vol. 2—Technology survey for artificial heart devices 3–41, Section E. Valves.
- Hudson, R. E. B. (1965). The aortic valve. *Cardiovascular Pathology*, Vol. 2, p. 1969. Arnold, London.
- Hufnagel, C. (1969). New Hufnagel tri-leaflet aortic valve. Heyer-Schulte Corporation Medical Products, California.
- Leonardo da Vinci (1513). Aortic pulmonary valves. *Leonardo da Vinci on the Human Body* (1952). By O'Malley, C. D., and Saunders, J. B. de C., pp. 258–274. Henry Schuman, New York.
- Reid, K. G., and Bellhouse, B. J. (1968a). The mechanism of aortic valve closure and the function of the sinus of Valsalva. *Proceedings of the European Congress of Cardiovascular Surgeons, Royal College of Surgeons, London*. Minerva Med., Milan.
- (1968b). *A Bio-engineering Study of the Aortic Root*. University of Oxford, Department of Engineering Science Report.
- Valsalva, A. M. (1740). *Arteriae Magnae Sinus In Opera*. Ed. Morgagni, J. B., Vol. I, p. 129. Venice.
- Van Citters, R. L., and Franklin, D. L. (1969). Cardiovascular performance of Alaska sled dogs during exercise. *Circulat. Res.*, **24**, 33.