

Rupture of the ventricular septum from myocardial infarction

Haemodynamic response to surgical treatment

T. PARTINGTON¹, JANE SOMERVILLE, T. HOLMES SELLORS,
AND L. RESNEKOV

From the Institute of Cardiology and Kettering General Hospital

A patient aged 59 had a coronary thrombosis complicated by a ruptured ventricular septum. This was successfully repaired surgically about three months after the infarct, and some indications and problems connected with this procedure are discussed.

Severe generalized coronary artery disease is usually found in patients who have had rupture of the ventricular septum following myocardial infarction. Despite intensive medical treatment, the mortality of the complication is high and only about 10–15% survive for longer than two months (Sanders, Kern, and Blount, 1956). If surgery is carried out after the first few weeks following rupture, approximately one-third of the patients survive for at least one year (Davison, Degenstein, Yuçeoğlu, Reyes, Levowitz, Dresdale, and Kantrowitz, 1964), which compares favourably with the low survival rate of 7% in medically treated patients (Oyamada and Queen, 1961). Re-opening of the defect may occur after surgical closure but, in spite of this, a good therapeutic and haemodynamic result may be achieved, as the following case illustrates.

CASE REPORT

A head porter at another hospital, aged 59 years, was first admitted to Kettering General Hospital on 21 May 1966. During the previous three weeks he had noticed occasional burning epigastric pain unrelated to exertion or to food. Thirty-six hours before admission he became faint and noted numbness of both arms. Twelve hours later severe retrosternal pain appeared at rest and was still present when he was first examined in hospital one day later. The signs at that time were: blood pressure 150/90 mm. Hg, pulse regular 80/minute, impalpable cardiac impulse, clear heart sounds with no murmurs, normal jugular venous pressure and pulsation, no palpable liver enlargement, and clear lungs. The electrocardiogram

confirmed the presence of posterior infarction showing deep Q waves and ST elevation in leads II and III, and aVF, and the chest radiograph showed no cardiac enlargement. The haemoglobin was 16 g./100 ml., W.B.C. 11,800/c.mm., E.S.R. 65 mm./hr., S.G.O.T. 28 units, L.D.H. 470 units, and blood urea 50 mg./100 ml. Morphine was given and phenindione started. Three days after admission, on May 24, the patient suddenly became breathless at rest and was found to have a loud pansystolic murmur maximal at the left lower sternal edge, and an irregular pulse. The electrocardiogram showed variable heart block, with an atrial rate of 120 and ventricular rate of 75 per minute. The patient was transferred to the National Heart Hospital with the diagnosis of ruptured inter-ventricular septum.

On admission the jugular venous pressure was raised 5 cm. with a dominant V wave, a systolic thrill was palpable at the left sternal edge, and the liver edge was palpable and pulsating 2 cm. below the costal margin. Bilateral basal crepitations were present and the patient was breathless and pale. A further electrocardiogram showed a varying degree of heart block with the Wenckebach phenomenon. A chest radiograph showed slight cardiac enlargement (Fig. 1a) compared with the film taken on admission to Kettering. Prednisone, 40 mg./day, and frusemide (Lasix) were added to his regime, but it was decided not to pace as the myocardium was irritable and there would be difficulty if the septum were ruptured.

High venous pressure and tachycardia persisted and digoxin, 0.25 mg. b.d., was started. Two days later ventricular ectopics increased (Fig. 2a) and dyspnoea worsened. Intravenous procainamide was started, but ventricular ectopics became more frequent and within a few hours ventricular fibrillation occurred (Fig. 2b). The circulation was maintained by external cardiac massage, and eventually he reverted to sinus rhythm with D.C. shock, after sodium bicarbonate,

¹Senior Physician, Kettering General Hospital.

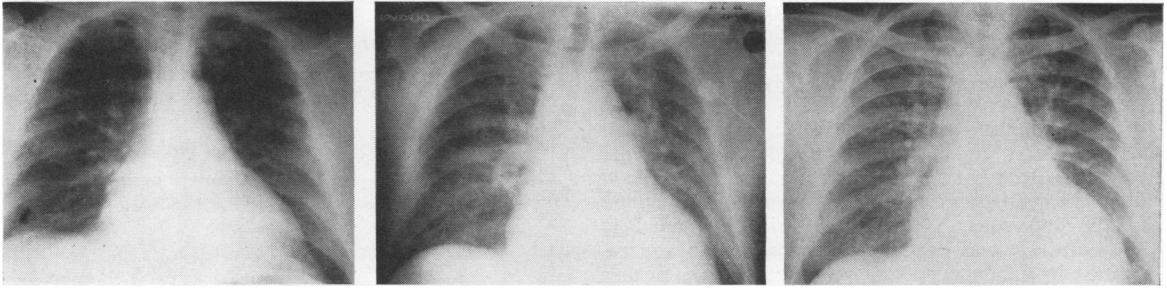


FIG. 1. Chest radiographs prior to operation: (a) three days after the infarction on the day he developed sudden dyspnoea and a pansystolic murmur; (b) three days after cardiac arrest; (c) three months after rupture of the ventricular septum. In gross congestive heart failure.

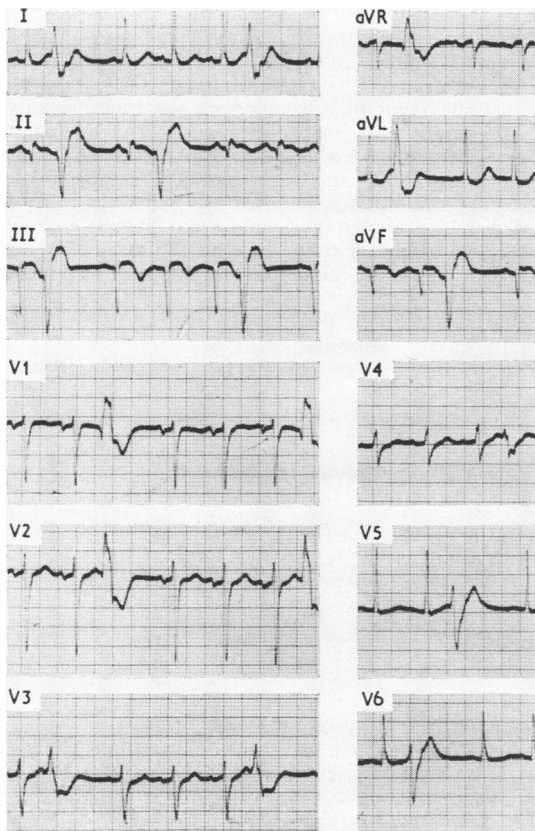


FIG. 2a. Electrocardiogram on morning of 31.5.66 showing posterior infarction and multiple ventricular ectopics.

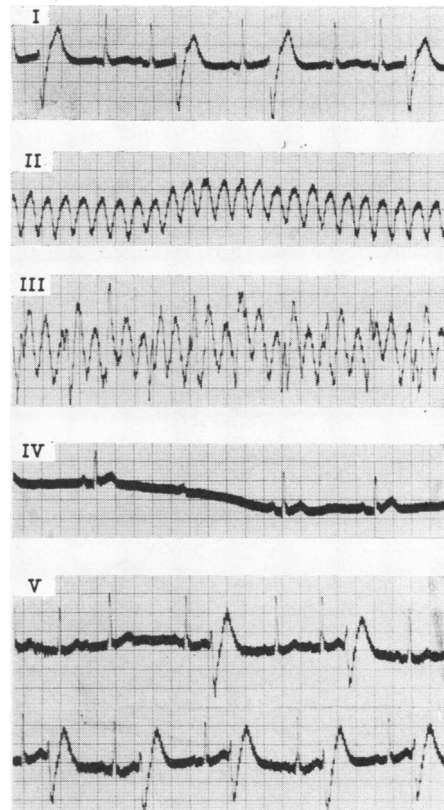


FIG. 2b. Mid-day 31.5.66, continuous recording of lead I: (I) increased frequency of ectopics; (II) ventricular tachycardia; (III) ventricular fibrillation; (IV) following D.C. shock—sinus rhythm and dropped beats; (V) sinus rhythm and ventricular ectopics.

lignocaine, procainamide, and propranolol. Ventricular tachycardia with loss of consciousness occurred five hours later and external cardiac massage was again needed to maintain an adequate cerebral circulation. Sinus rhythm was restored after three D.C. shocks. Following these two cardiac arrests his mental state was good, but severe pulmonary oedema persisted. At this time laboratory tests showed blood urea 100 mg./100 ml., white cell count 16,000/c.mm., L.D.H. 900 units, S.G.O.T. 125 units, and S.G.P.T. 200 units. He was kept on a lignocaine drip and remained in subacute pulmonary oedema for a further week with episodes of atrial fibrillation. His condition gradually improved over the succeeding four weeks despite persistent right-sided heart failure. The physical signs were unchanged with the addition of a loud pulmonary valve closure which was noted seven weeks after the acute myocardial infarction (Figs 3a, b). Low-grade fever, anaemia, and raised sedimentation rate continued for six weeks. During this time antiheart antibodies were found in the serum and it was concluded that he had a post-infarction syndrome.

For a further month the gross heart failure persisted despite intensive therapy. Cardiac catheterization was performed on 16 August 1966 (Table I) and it was decided that closure of the ventricular septal defect would provide the only chance of improving the hopeless state. The patient could only sit out of bed and was too breathless to walk across the ward.

On 1 September 1966 the patient was operated on for closure of the ventricular septal defect. The heart was exposed through a median sternotomy and cardiopulmonary bypass was instituted, using aortic cannulation. The body temperature was reduced to 32° C. The heart was large and flabby and the right atrial pressure unduly high, as had been anticipated

TABLE I
RESULTS OF PRE-OPERATIVE CARDIAC CATHETERIZATION (16.8.66)

Site	Pressure (mm. Hg) ¹		% Oxygen Saturation	Pulmonary Flow (l./min.)	Systemic Flow (l./min.)	Pulmonary to Systemic Flow Ratio
	S/D	Mean				
P.C.V.	a=17 v=27 x=9 y=11	15				
P.A. M. L.	80/17 72/20	40	81 ² 78	8.1	3.2	
R.V. Outflow Inflow R.A.	75/12 a=20 a=16 v=17 x=8 y=5	12	85 87 Low 57 Mid 59 High 56			2.5/1
S.V.C. Brachial artery	— 125/80	98	54 97 ²			

Pulmonary flow 8.1 l./min. Systemic flow 3.2 l./min. Pulmonary/systemic flow ratio 2.5/1.0. S/D = systemic/diastolic

¹Zero level at sternal angle.

²Simultaneous.

from the catheterization figure. There was an easily felt thrill on the anterior surface of the heart at the inferior part of the right ventricle. There was also a definite regurgitant jet through the tricuspid valve.

The right ventricle was opened through a transverse incision, and a defect in the ventricular septum, measuring 1.5 × 2 cm., was explored. This was situated beneath the inferior edge of the septal leaf of the tricuspid valve and had thin white fibrotic margins. Repair was effected by suturing a single-layer pericardial patch over the defect using 12 mattress sutures.

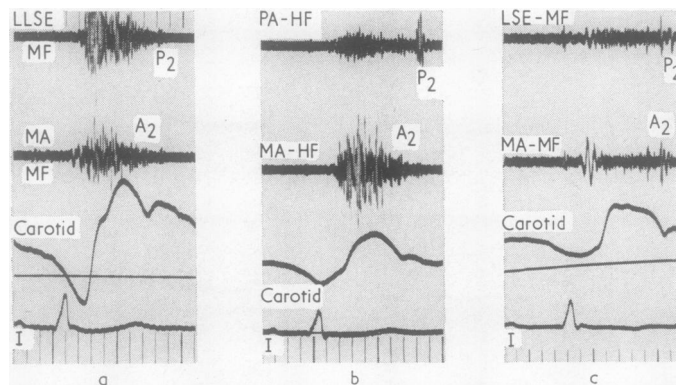


FIG. 3. Phonocardiograms recorded at left sternal edge (L.S.E.) and mitral area (M.A.) with carotid pulse and lead I of the electrocardiogram simultaneously recorded. (a) Five days after rupture of the septum showing pansystolic murmur at the left sternal edge with early systolic accentuation. Pulmonary valve closure (P_2) is delayed 0.06 sec. (b) Seven weeks later P_2 increased. (c) Three months after operation. Soft pansystolic murmur at L.S.E. A_2 increased, P_2 diminished, and less delayed 0.04 sec. inspiration.

The edges of the defect nearest the tricuspid orifice were very thin and close to the probable site of the conducting bundle.

At the completion of bypass there was no obvious thrill and tricuspid regurgitation was considerably reduced. The patient's immediate post-operative progress was satisfactory but slow, with some disorientation which gradually regressed. Initially, there was no obvious murmur, but on the sixth post-operative day a pansystolic murmur was again heard at the apex and left sternal edge. His condition continued to improve slowly, and the jugular venous pulse, which was raised in the first post-operative weeks, gradually fell to normal. For a time he had a low-grade pyrexia, despite repeated negative blood and urine cultures, and the erythrocyte sedimentation rate rose to 56 mm./hr.; this was attributed to continuing post-pericardotomy syndrome. Antiheart antibodies were again found. He returned to Kettering General Hospital to complete his convalescence and returned home on 25 October 1966. When seen again on 20 December 1966 there was no sign of cardiac failure, despite the grade 2/4 pansystolic murmur at the left sternal edge (Fig. 3c).

TABLE II
RESULTS OF POST-OPERATIVE CARDIAC CATHETERIZATION AT REST (7.2.67)

Site	Pressure (mm.Hg)		% Oxygen Saturation	Pulmonary Flow (l./min.)	Systemic Flow (l./min.)	Pulmonary to Systemic Flow Ratio
	S/D	Mean				
M.P.A.	35/6	20	84	10.4	4.8	2:2
R.V.	35/0		87			
R.A.	a=0	-2	68			
S.V.C.			68			
R.B.A.	155/75	110	97			

Note: Heart rate 75/min. throughout. Pressures in mm. Hg with reference to the sternal angle. S/D = systemic/diastolic

On 7 February 1967 he was re-investigated (Tables II and III) and following this he returned to a full-time job as a telephone operator. He has remained well to the present date, able to walk 250 yards (230 m.) on the flat, and climb stairs without dyspnoea angina. The loud pansystolic murmur and thrill remain. The chest radiograph still shows some cardiac enlargement which is less than before surgery (Fig. 4). The electrocardiogram shows ischaemic changes as well as digitalis effect (Fig. 5).

DISCUSSION

Recognition of the disastrous occurrence of ventricular septal rupture complicating myocardial infarction has become widespread in recent years. It mimics ruptured papillary muscle in its disastrous clinical effects and poor prognosis. In this patient, the presence of an enlarged liver noted at the time of the appearance of the pansystolic bruit, and the murmur maximal at the left sternal

TABLE III

HAEMODYNAMIC RESPONSE TO EFFORT FOLLOWING SURGERY, COMPARED WITH FINDINGS AT REST

Heart Rate/min.	O ₂ Cons. (ml.)	Main Pulmonary Artery			Right Atrium			Brachial Artery		Pulmonary			Systemic		Pulmonary to Systemic Flow Ratio	
		Pressure (mm.Hg)	% Satn.		Pressure (mm.Hg)	% Satn.		Pressure (mm.Hg)	Mean	% Satn.	AVDO ₂ (ml.)	Flow (l./min.)	S.V. (ml.)	Flow (l./min.)		S.V. (ml.)
Rest	260	35/6	84	0	155/75	68	110	10.4	97	25	10.4	140	54	4.8	64	2:2
Effort ¹	505	50/12.5	64	0.5	170/80	50	120	7.9	97	64	7.9	79	91	5.5	55	1:44

¹ During fifth minute of pedalling a bicycle ergometer at 150 kpm/min. Note: Pressures in mm. Hg with reference to the sternal angle. AVDO₂ = Arterio-venous oxygen difference O₂ cons. = Oxygen consumption Satn. = Saturation S/D = systemic/diastolic S.V. = Stroke volume

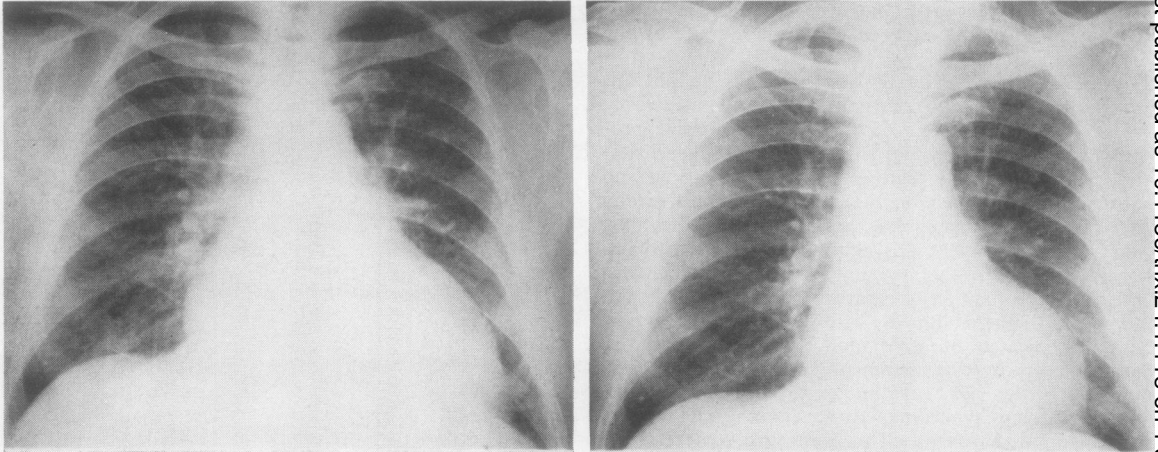


FIG. 4. Chest radiographs (left) immediately before operation and (right) three months after surgery. In the post-operative film the heart has decreased in size and there is less plethora.

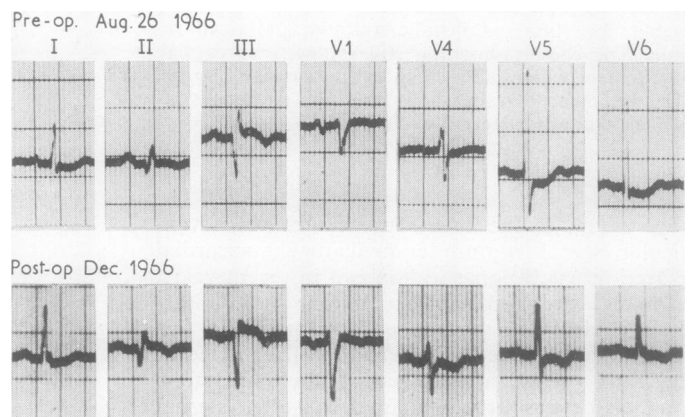
edge with wide radiation, strongly suggested a ruptured septum rather than papillary muscle dysfunction or ruptured chordae. Conduction defects with congestive failure are commoner in ruptured septum than in chordal rupture, which usually presents as acute pulmonary oedema. Pulmonary oedema in this patient occurred only after the cardiac arrests and was probably in part precipitated by the administration of excessive sodium in the form of sodium bicarbonate to relieve the acidosis.

Though there are no electrocardiographic changes peculiar to septal rupture alone, evidence of antero-septal infarction with QS or QT patterns and S-T segment changes in right precordial leads, without evidence of right ventricular hypertrophy, combined with the Q_3T_3 pattern of posterior (or inferior) infarction is frequently found where myocardial infarction has involved

the septum extensively (Roesler and Dressler, 1947). In this patient the lesion was mainly related to postero-inferior infarction but diffuse T-wave changes over the left ventricle suggested the presence of anterior ischaemia.

The high mortality of 50% in the first month after rupture (Sanders *et al.*, 1956) does not all occur in the first few days. The size of the defect must be a critical factor in the production of irreversible heart failure as this directly affects the size of the increase of blood flow and work load on the struggling right ventricle. Furthermore, the development of pulmonary hypertension in later weeks, as occurred in this patient, initially suggested by increased pulmonary valve closure (P_2) (Fig. 3) and confirmed by the catheter, must cause further deterioration and account for some of the later deaths which are not due to a new infarction. Thus it is important to remove the added volume

FIG. 5. Electrocardiograms immediately before surgery and three months after operation.



load imposed by the left-to-right shunt, particularly if the myocardium is embarrassed by coronary disease.

Cardiac catheterization is important in the assessment of ruptured ventricular septum after myocardial infarction. The large left-to-right shunt found at the preoperative catheterization in this patient was in keeping with the large ventricular septal defect, 1.5×2 cm., found at operation. The high wedge pressure with V waves of 27 mm. at rest was due to left ventricular failure which, in this case, clearly resulted from the volume overload as well as from the poor ischaemic myocardium. Honey, Belcher, Hasan, and Gibbons (1967) have emphasized the importance of assessing left ventricular function in these cases before deciding on management, but it may be difficult to separate the role of the left-to-right shunt from that of the primary myocardial disease in causing the failure. Clearly, left ventricular angiography would provide valuable information about the size of the defect, but this was deliberately not done at the first investigation as the patient was breathless when lying at an angle of 45° on the catheter table.

The presence of some left ventricular dysfunction five months after the closure of the defect was confirmed on re-catheterization (Table III). After minimal exercise there was an abnormal increase in heart rate, the pulmonary artery pressure rose, the pulmonary blood flow diminished, and the stroke volume decreased from both ventricles. This is not the usual response in ventricular septal defect of congenital origin where the myocardium is healthy and the heart is adapted to the lesion. It cannot, therefore, be attributed to the persistence of the defect alone and must be due to impaired left ventricular function from ischaemic heart disease. In spite of this the patient was greatly improved, and from having been orthopaedic in bed he was able to return to work.

The site of the defect usually appears to be in the lower part of the septum and of a size which inevitably would produce a serious shunt. A defect which lies close to the tricuspid ring and which is covered by the septal leaf of the valve is close to conducting tissue: this suggests that great care must be taken in placing the sutures used for closure. Other defects can lie close to the apex, hidden in the deep clefts between papillary muscles and sometimes difficult to identify. The margins of the defect are not necessarily fibrotic even several months after the original rupture. In two other instances in our experience part of the margin of the defect operated on several weeks

after the rupture consisted of soft muscle with the rest of the defect surrounded by attenuated fibrous tissue. Direct closure of any defect is not likely to be practical. Some form of patch is almost certainly indicated and, currently, pericardium would appear to be suitable. In spite of careful suturing, the risk of a stitch cutting out of the septum is something that is difficult to prevent when the margins are thin or where the muscle of the septum is soft, which presumably occurred in this case a few days after operation.

Persistence or re-opening of a small ventricular septal defect is not uncommon after surgery for a lesion due to rupture following myocardial infarction (Cooley, Belmonte, Zeis, and Schnur, 1957; Proudfit, Tapia, McCormack, and Effler, 1959; Honey *et al.*, 1967). However, even reducing the shunt clearly helps recovery, and the possibility of re-opening the defect should not prevent surgery even in the most ill patients. The difficulties of closing the defect and maintaining closure are even greater in the first few weeks after rupture as the septum is soft and pliable and the surrounding muscle may be necrotic. In view of this, the patient was deliberately maintained on medical therapy for three months. In many patients this would not be possible and it is often necessary to operate on such patients earlier. Where possible, we would prefer to wait at least six weeks, particularly with the improvements brought about in cardiac resuscitation and in control of arrhythmias after cardiac infarction.

We are grateful to Dr. Wallace Bridgen for permission to publish this case, to Dr. John Robinson for doing the antiheart antibodies at the London Hospital, and to Dr. Herman Ruiz for recording the phonocardiograms.

REFERENCES

- Cooley, D. A., Belmonte, B. A., Zeis, L. B., and Schnur, S. (1957). Surgical repair of ruptured interventricular septum following acute myocardial infarction. *Surgery*, **41**, 930.
- Davison, T., Degenshein, G. A., Yucooglu, Y. Z., Reyes, A. L., Levowitz, B., Dresdale, D. T., and Kantrowitz, A. (1964). Repair of ventricular septal defect following myocardial infarction. *Ann. Surg.*, **160**, 33.
- Honey, M., Belcher, J. R., Hasan, M., and Gibbons, J. R. P. (1967). Successful early repair of acquired ventricular septal defect after myocardial infarction. *Brit. Heart J.*, **29**, 453.
- Oyamada, A., and Queen, F. B. (1961). Spontaneous rupture of the interventricular septum following acute myocardial infarction with some clinic-pathological observations on survival in five cases. Presented at Pan Pacific Pathology Congress, Tripler, U.S. Army Hospital, October 12.
- Proudfit, W. L., Tapia, F. A., McCormack, L. J., and Effler, D. B. (1959). Rupture of the ventricular myocardium and perforation of the interventricular septum complicating acute myocardial infarction. *Circulation*, **20**, 128.
- Roesler, H., and Dressler, W. (1947). An electrocardiographic pattern of infarction of the interventricular septum, extending from the anterior to the posterior aspect of the heart. *Amer. Heart J.*, **34**, 817.
- Sanders, R. J., Kern, W. H., and Blount, S. G. (1956). Perforation of the interventricular septum complicating myocardial infarction: a report of 8 cases, one with cardiac catheterization. *Ibid.*, **51**, 736.