Thorax (1958), **13**, 103.

THE PERIPHERAL PATTERN IN THE NORMAL BRONCHOGRAM AND ITS RELATION TO PERIPHERAL PULMONARY ANATOMY*

BY

LYNNE REID AND G. SIMON

From the Institute of Diseases of the Chest and Brompton Hospital, London

(RECEIVED FOR PUBLICATION OCTOBER 19, 1957)

The appearances in a bronchogram of the more proximal branches of the bronchial tree are well known and have been fully described (Huizinga and Smelt, 1949; Twining and Kerley, 1951; Fischer, 1953; Brock, 1954; Ritvo, 1956). This is not so in regard to the more distal and final branches, and there is, moreover, some confusion as to which structures are outlined by the contrast medium at the periphery of a well-filled clinical bronchogram. The earlier belief that the rather woolly shadows sometimes seen in a well-filled bronchial tree, and illustrated in Fig. 4, represented alveolar filling is to-day thought unsatisfactory (Twining and Kerley, 1951; Fischer, 1953), but the term "peripheral filling," which is tending to replace the earlier description, does not give an exact indication of the structures outlined. Twining suggests, as the result of stereoscopic examination of a lung specimen injected with "lipiodol," that an appearance "like a tree in bud" was the result of filling of respiratory bronchioles, and Ritvo describes a similar granular appearance as being characteristic of filling of respiratory bronchioles.

A more detailed description of the normal appearances of the distal part of the bronchial tree would be of value both in the detection and localization of abnormalities of the peripheral bronchi and bronchioles, such as are seen in chronic bronchitis (Simon and Galbraith, 1953), and in the localization in relation to the peripheral bronchi of small abnormal shadows such as are seen in tuberculosis and sarcoidosis. Several hundreds of apparently normal clinical bronchograms were therefore examined, and these form the basis for the description of the normal pattern of the peripheral part of the bronchial tree given in Part I of this paper. Part II describes how, by histological examination of injected specimens, the exact anatomical site of certain of these shadows was demonstrated.

PART I: STUDY OF THE PERIPHERAL PATTERN IN NORMAL CLINICAL BRONCHOGRAMS

The word "peripheral" or "distal" is used here to describe those parts which are toward the end of the pattern of branching of the bronchial tree. In this sense, a structure may be peripheral or distal and yet deep in the lung's substance, and central in a radiograph. Although the same peripheral pattern is seen throughout the lung, it is easier to study its details in the subpleural region than in the central part where it is apt to be obscured by overlying shadows.

The bronchograms studied were taken as part of the examination of patients, many being rejected because they showed obvious pathological changes or because the contrast medium did not fill the peripheral bronchi. Those showing adequate peripheral filling, and thought to be normal in at least one lobe, were then examined in detail. When possible, the shadow cast by a filled air tube was examined in two planes by identifying it both in the postero-anterior and in the lateral or oblique view. In several cases tomograms were available so that even in well-filled bronchograms it was possible to study the shadow of a bronchus or bronchiole deep in the lung without its being obscured by overlying bronchi. A similar peripheral pattern was shown whether the contrast medium used was iodized oil or oily or watery propyliodone, and whatever the method of introduction.

THE SHAPE OF THE LUMEN.—The pattern of the bronchi when traced from the hilum to the periphery is essentially that of frequently branching line shadows, progressively decreasing in width. Whereas in the larger proximal bronchi it is sometimes possible to see the shadow of the contrast

*A communication based on this paper was delivered to the Thoracic Society in July, 1957.

medium tapering before a division, in the distal parts the air tubes produce line shadows with parallel walls, the decreases in width taking place only after each branching. This is the case over approximately the distal half of an axial pathway, which is the region with which we are concerned in this description.

THE ANGLE OF BRANCHING.—Three types of angulation were noted (see also Hayward and Reid, 1952): (1) the acute angle, in which two branches arise from the end of a parent stem, sometimes equally, and proceed with a slight curve like a wish bone, each branch usually undergoing many further divisions; (2) the right angle, in which one branch leaves a straight parent stem more or less at right angles to it and usually has only a short course before its final termination; (3) the obtuse angle, in which the parent stem in its more distal course has a zigzag appearance (Fig. 3) and the side branches pass outwards from it at the points of angulation in alternate directions. Of these, the right angle and obtuse angle types are more frequent than the acute.

THE "CENTIMETRE" AND "MILLIMETRE" PATTERNS.—The distance between successive branches in the peripheral part of the bronchial tree was measured. Such measurements are only approximate because the bronchi or bronchioles vary in their angle to and distance from the *x*-ray film. In addition there may be variation according to the phase of respiration, although this may be expected to be slight.

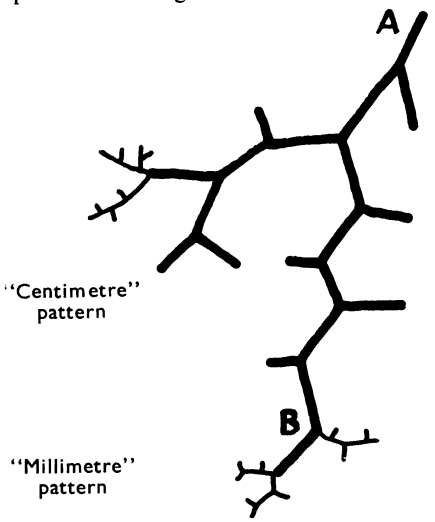

FIG. 1.—Diagram showing the pattern of branching of the end of a bronchial pathway. At first the branches arise at intervals of approximately 0·5 to 1 cm.—A to B—and then beyond B they arise at intervals of approximately 2 mm. (approximately natural size).

Along the distal 10 cm. or so of an axial bronchial pathway, it is found possible to distinguish two patterns of branching, both of which are represented in the diagram in Fig. 1. At first, as between A and B, the branches arise at intervals of approximately 0.5 to 1 cm., and then, over the last centimetre or so, that is, beyond B, the branches, which are now reduced to approximately 1 mm. in diameter, arise at intervals

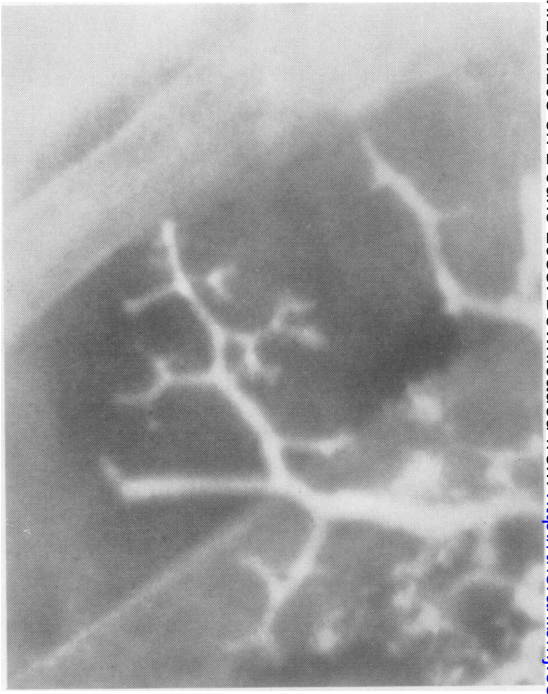

FIG. 2.—Anterior view bronchogram of the right second and third interspace showing "centimetre" pattern of lines arising at intervals of 0·5 to 1 cm., as between A and B in Fig. 1. (×2 approximately.)

of 2 to 3 mm. and are only about 2 mm. long. We have found it convenient to describe these two types of branching as the "centimetre" pattern and the "millimetre" pattern respectively. In addition to being illustrated diagrammatically in Fig. 1, the centimetre pattern as seen in bronchograms is shown in Figs. 2 and 3 and the millimetre pattern in Fig. 3. As soon as short branches arise repeatedly at 2 to 3 mm. the pathway continues only for 1 cm. or less, so that the change to this closer branching is the sign of the final termination of the pathway in respiratory tissue.

APPEARANCES IN BRONCHOGRAM CAUSED BY SUPERIMPOSITION OF LINE SHADOWS.—There may

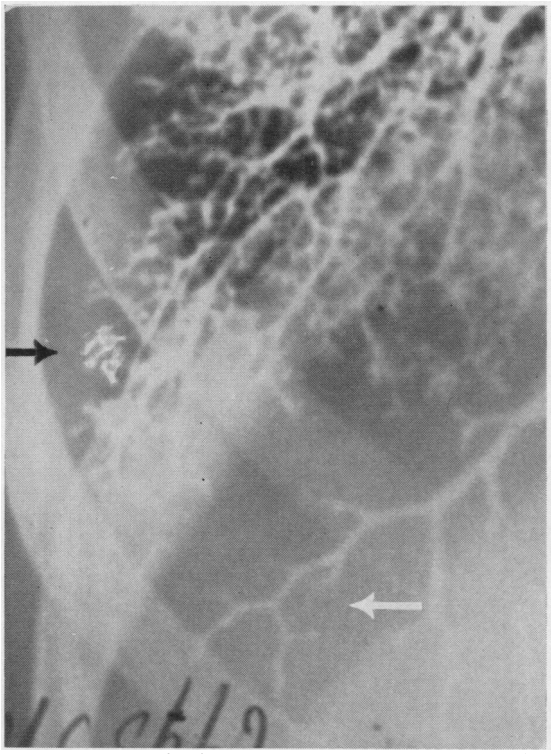

FIG. 3.—Anterior view bronchogram of the lower part of the right chest. The ultimate lines are shorter and finer than those in Fig. 2, being about 2 mm. long and arising at intervals of about 2 mm. This is an example of the "millimetre" pattern (top arrow) and shows also the "unfilled rim" of lung under the ribs. The "centimetre" pattern is seen opposite the lower arrow. (×1.)

be so much radio-opaque material in the lungs that it causes a more or less confluent woolly shadow. By comparing bronchograms taken at different angles it is often possible to show that such an appearance results in fact from the superimposition of line shadows. In Fig. 4 woolly shadows 2–3 mm. in size are seen lying laterally in the subpleural region in the anterior view. These are not present in the lateral view shown in Fig. 5, and were evidently the result of superimposition of the line shadows which can here be separately identified. Proof that a woolly shadow is caused by superimposed line shadows can usually be found only at the edge of the lung because centrally where the lung is thick it may not be possible to distinguish the individual shadows in any view. If a broncho-tomogram is done, however, line shadows can usually be detected even in the central part of a well-filled lobe.

Sometimes a punctate shadow may be seen overlying a line shadow either directly (Fig. 6) or slightly to one side. This may give a somewhat bulbous appearance to the parent line. Fig. 6 also shows several punctate shadows, which in the lateral view of the bronchogram were established as side branches viewed end-on. Such shadows are not wider than the line with which they are associated. A ring shadow of a somewhat greater diameter than that of a bronchiole, i.e., 3–5 mm., is sometimes seen where there is intensive peripheral filling (Fig. 6). From comparison with other views it can be established that such a ring is an artefact due to superimposed line shadows and that it does not represent a separate structure. Rarely the end of the line may be a little blurred if filling has gone slightly further than the structures represented by a 2 mm. line shadow.

THE UNFILLED RIM.—However peripheral the filling in a normal clinical bronchogram, the contrast medium terminates some 2–5 mm. from the edge of the lung. This rim of unfilled lung surrounds each lobe. In the sense that, throughout the lung, this region is unfilled, each secondary lobule, each bronchiole even, is surrounded by an unfilled rim. In an anterior view the unfilled rim will be seen only in the subpleural region along the axillary border (Fig. 3), and in a lateral view it will be seen most clearly on either side of the interlobar septum (Fig. 7). At the margin of this unfilled rim the contrast medium in the bronchial tree is still in the form of line shadows except when superimposition of branches causes some bulbous expansions.

PART II: CORRELATION OF PERIPHERAL BRONCHOGRAPHIC SHADOWS WITH THE ANATOMY OF THE LUNG

MATERIAL AND METHODS.—Normal lung specimens were radiographed after injecting them with radio-opaque material and a pattern similar to that seen in clinical bronchograms was identified. Four lungs were injected, two from male subjects aged 50 and 42, who died from intestinal obstruction and coronary occlusion respectively; two from female subjects, one aged 33 who died of carbon monoxide poisoning, while the other, aged 49, died three days after an operation for the repair of an atrial septal defect. Cardiac catheterization had shown pulmonary hypertension, but there was no histological evidence of organic pulmonary artery disease. As the appearances in the bronchogram of this lung were similar to those in the other three, it was concluded that, even if the pulmonary vascular bed was affected by the congenital cardiac defect, the bronchial tree was within normal limits and the lung could be used for these studies.

The method of injection resembled that described by Reid (1955), save that pressure was applied by a

FIG. 4.—Anterior view bronchogram of the right upper chest showing woolly opacities, 2–3 mm. in diameter, towards the axilla. (×1.)

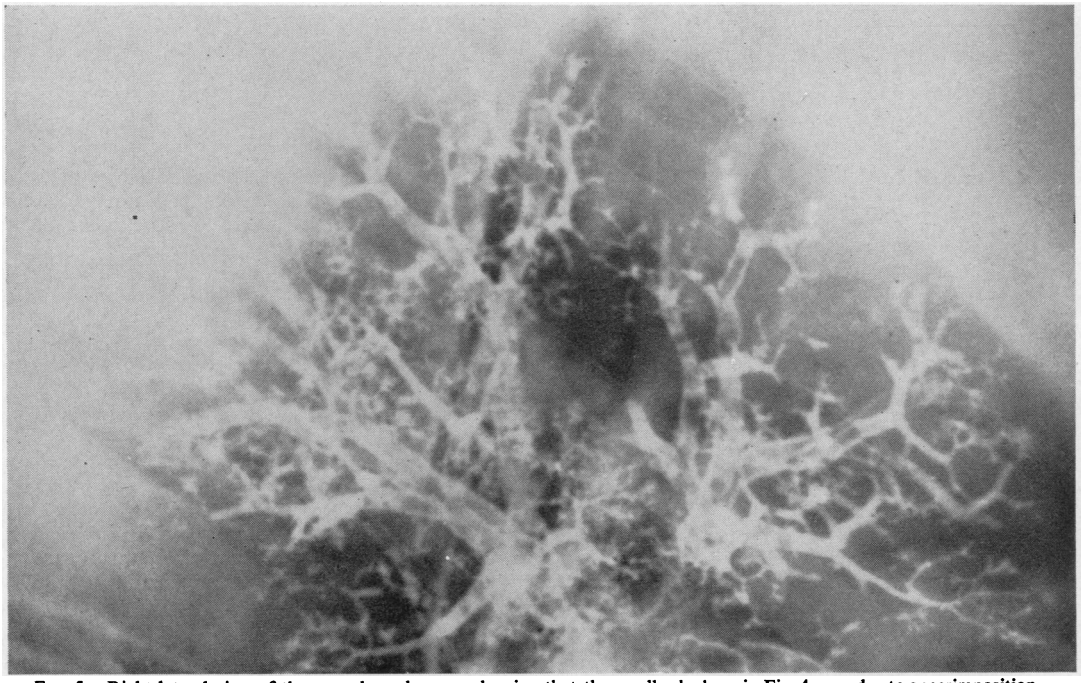

FIG. 5.—Right lateral view of the same bronchogram showing that the woolly shadows in Fig. 4 were due to superimposition of line shadows. (×1.)

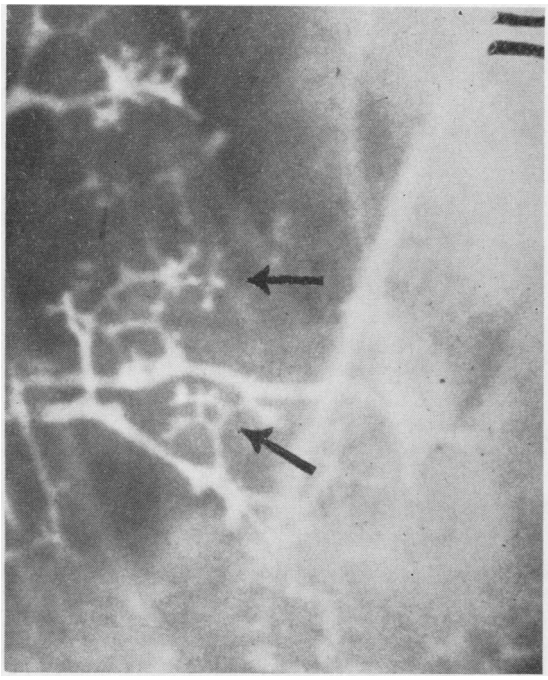

FIG. 6.—Bronchogram showing punctate shadows overlying lines (upper arrow); other views show that these appearances result from side branches viewed end on. Ring shadows (lower arrow), which other views show are not separate structures, are also the result of the superimposition of lines. (× 1·5.)

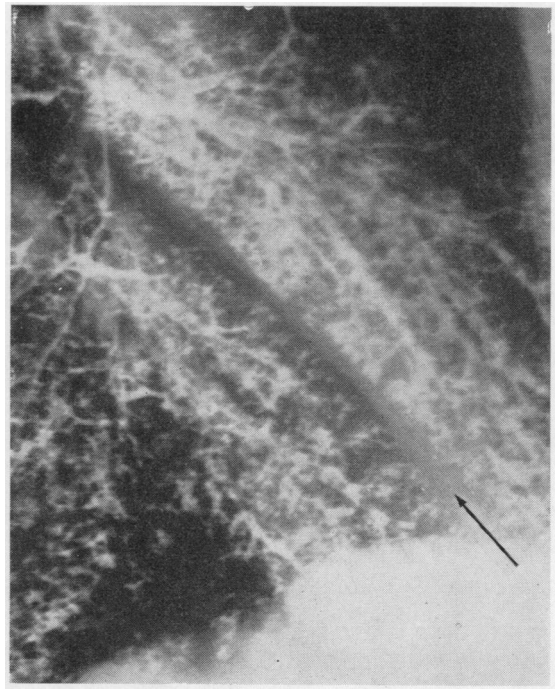

FIG. 7.—Lateral view bronchogram of the right lung, showing the unfilled zone along the oblique fissure (arrow points to its lower end). (× 0·5.)

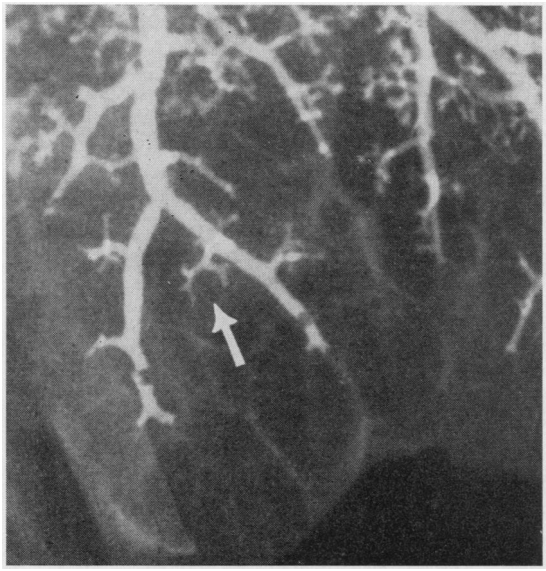

FIG. 8.—Bronchogram prepared on the lung of a woman, showing a cluster of lines taken as an example of the "millimetre" pattern. The radio-opaque material at the end of each of these lines was found to be within terminal bronchioles. (× 1·5.)

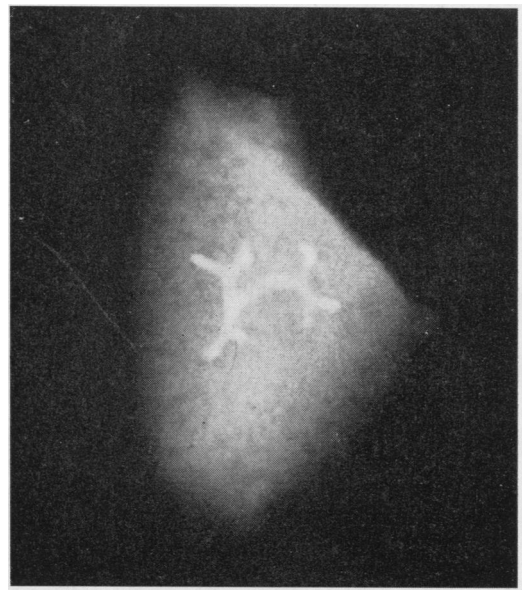

FIG. 9.—Radiograph of a paraffin block including a similar cluster of "millimetre" pattern lines to that shown in Fig. 8. From such blocks sections were cut serially. (× 3.)

hydrostatic pump. A subatmospheric pressure was applied until the lung was well inflated. It was then released and the injection solution (barium sulphate in gelatine) allowed to flow into the bronchus at a pressure of 30 cm. of water, this being controlled by a hydrostatic device. Since this solution sets firm, the lung could be handled without dislodging the radio-opaque material, which would not be possible with a fluid medium such as iodized oil.

The specimen was then examined by fluoroscopy to see that filling was satisfactory. Fixation was achieved by running formalin into the pulmonary artery and immersing the lung in formalin for one week. In radiographs of all specimens it was possible to recognize a pattern similar to that described in clinical bronchograms. From the bronchogram suitable parts of the lung could be selected for microscopic study (Fig. 8), in particular areas showing the millimetre pattern of lines, so that these could be related to the structures they represent. As these patterns were either near the edge of the lung, or not obscured by overlying shadows, the blocks could be cut after a suitable area was localized in the specimen by fluoroscopy. From three of the four cases blocks were taken for microscopic study. In three blocks from one subject 12 examples of the millimetre pattern of line shadows were included, in two blocks from another there were six examples, and from the third subject one block contained four examples, making a total of 22 examples of millimetre line shadows. The blocks were selected in such a way that serial sections could be cut at right angles to the long axis of at least one of the bronchioles responsible for a line in the bronchogram. Sections were examined at intervals of 0.2 mm. over the several millimetres which included lung proximal and distal to the point where radio-opaque material disappeared. This frequency of sections was found convenient for examining structures of this size. The sections were 7 μ thick and stained by the Verhoeff-van Gieson method.

The series of sections were examined most conveniently under low magnification, for which a plate microscope was particularly useful, as a field of 1 cm. diameter could be examined at a magnification of 12. In this way a large slide could be quickly scanned. Photographs at a magnification of 12 were found particularly useful for studying relevant parts of sections. Fig. 10 is prepared from one of these photographs.

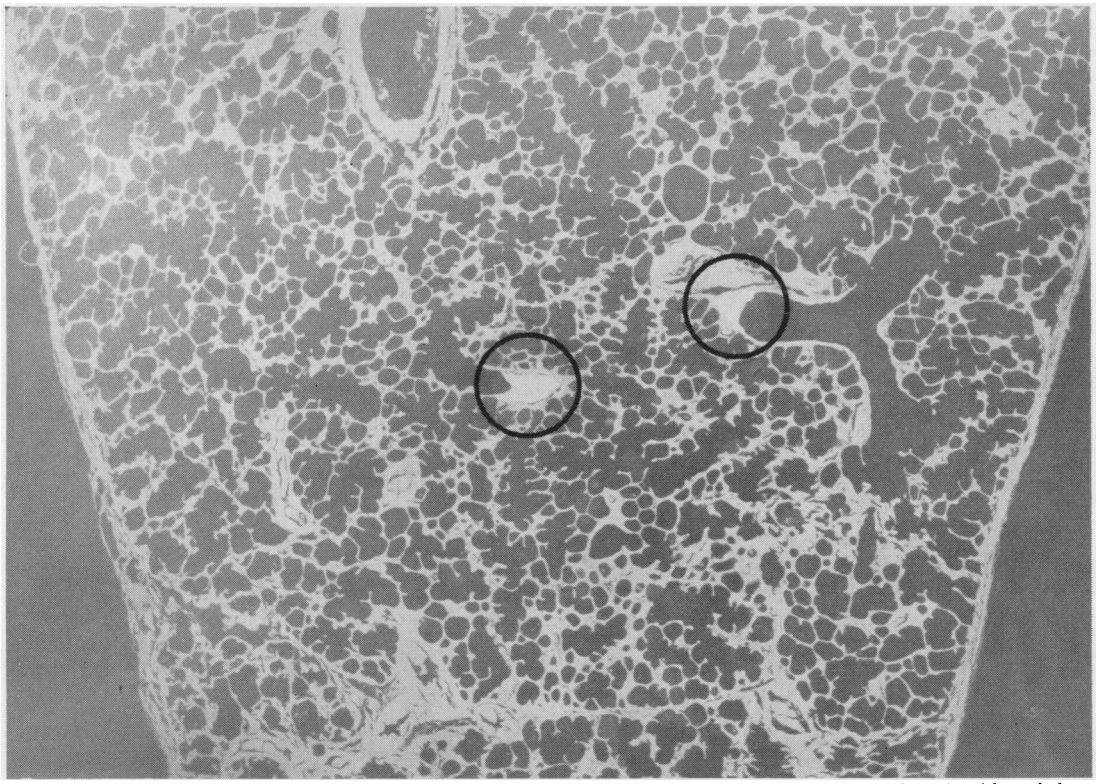

FIG. 10.—One of a series of sections including the ends of two lines of the "millimetre" pattern, each of which is enclosed in a circle. The radio-opaque material shows as white, and lies in a terminal bronchiole. Between the end of the radio-opaque material and the pleura the nature of the unfilled area is also demonstrated, and two respiratory bronchioles arising from the bronchiole on the right are evident. (× 12.)

IDENTIFICATION OF SITE OF THE MILLIMETRE PATTERN.—Fig. 9 shows a cluster of lines, from near the diaphragm, which was chosen as an example of the millimetre pattern and included in a block of tissue which was serially sectioned. Each of these short lines was found to represent a terminal bronchiole (Fig. 10), as in each case the radio-opaque material filled this structure but did not penetrate further. (By definition a terminal bronchiole is immediately proximal to a respiratory one, that is, a bronchiole into whose lumen alveoli open directly.)

In another series of sections six lines were included and in each case a terminal bronchiole was outlined although in four of the cases the opaque medium had just reached into a respiratory bronchiole. Radio-opaque material could be detected microscopically just within a respiratory bronchiole, but because it extended for only a fraction of a millimetre it could scarcely be said to outline a respiratory bronchiole. In 17 instances from three lungs similar correlation between the millimetre pattern and a terminal bronchiole was established.

IDENTIFICATION OF SITE OF THE CENTIMETRE PATTERN.—While the fine lines of the millimetre pattern represent terminal bronchioles, proximally in the centimetre pattern no such precise relation exists between shadow and structure, as it is not possible to be sure whether it is a bronchus or bronchiole which casts a particular shadow. The bronchiole is defined as an airway lying beyond the most peripheral cartilage, but this point is not constant for all bronchial pathways. For example, in tracing bronchial pathways passing towards the pleura it can be shown that there is considerable variation in both the distance and the number of branches between the last piece of cartilage and the pleura (Reid, 1958). For the purpose of correlating the bronchogram with the structure filled, it is clear that no arbitrary division can be set between the bronchial and the bronchiolar part of a particular pathway, and that these cannot be recognized on a bronchogram. Although proximally the centimetre pattern represents bronchi, in its more peripheral part it may represent either bronchioles or small bronchi.

STRUCTURES REPRESENTED IN THE UNFILLED RIM.—In the illustration (Fig. 10) used to show the extent of filling, it is also possible to get some idea of the histological structure of the unfilled part of the lung beyond, i.e., the unfilled rim. Beyond the terminal bronchiole, that is the point where the contrast medium ends, there may be one, two, or three generations of respiratory bronchioles and then possibly the same number of alveolar ducts with the alveoli they supply. The alveolar duct with its alveoli (primary lobule of Miller, 1947) is 1–1.5 mm. long, a respiratory bronchiole is also 1–1.5 mm. long (Davies, 1949). Thus an approximate calculation from these figures gives the likely depth of unfilled rim of lung as 4–5 mm.; a cross-section of this may intersect part of 16 or so alveoli.

SUMMARY

The peripheral part of the airways in a normal bronchogram consists of parallel-walled line shadows. After the eighth to tenth division of a segmental bronchus along an axial pathway, branching occurs at intervals of about 0.5 to 1.0 cm. until near the end when there is a transition to branches every 2–3 mm., these divisions being only 2–3 mm. long. These we have called the "centimetre" and "millimetre" pattern respectively.

Correlation with the histology shows that the centimetre pattern mostly represents bronchi, but a varying number of its peripheral branches represents bronchioles, while the closer set millimetre pattern represents terminal bronchioles. Even in a well-filled normal clinical bronchogram all orders of respiratory bronchioles, alveolar ducts, and alveoli are usually free from contrast medium, and are represented in the bronchogram by an unfilled rim in the subpleural region. The woolly appearance sometimes seen is either due to superimposed line shadows or is pathological. The alveoli do not normally fill appreciably.

We wish to thank Dr. D. Teare (St. George's Hospital), Dr. R. Drury (University College Hospital), and Dr. G. Canti (St. Bartholomew's Hospital) for sending us suitable specimens of normal lung. For the photography we are indebted to Mr. D. Kemp, Photographic Department, Institute of Diseases of the Chest.

REFERENCES

Brock, R. C. (1954). *The Anatomy of the Bronchial Tree*, 2nd ed. Oxford University Press, London.
Davies, C. N. (1949). *Brit. J. industr. Med.*, **6**, 245.
Fischer, F. K. (1953). In *Roentgen-Diagnostics* by H. R. Schinz, W. E. Baensch, E. Friedl, and E. Uehlinder. English translation by J. T. Case, Vol. 3, p. 2036. Heinemann, London.
Hayward, J., and Reid, L. McA. (1952). *Thorax*, **7**, 89.
Huizinga, E., and Smelt, G. J. (1949). *Bronchography*. Van Gorcum, Assen, Netherlands.
Miller, W. S. (1947). *The Lung*, 2nd ed. Thomas, Springfield, Illinois.
Reid, L. M. (1958). *Thorax*, **13**, 110.
Ritvo, M. (1956). *Chest X-Ray Diagnosis*, 2nd ed., p. 101. Kimpton, London.
Simon, G., and Galbraith, H.-J. B. (1953). *Lancet*, **2**, 850.
Twining, E. W., and Kerley, P. (1951). In *A Text-Book of X-Ray Diagnosis*, 2nd ed., vol. 2, p. 208. By British authors, edited by S. C. Shanks and P. Kerley. Lewis, London.