Thorax (1956), **11**, 241.

THE RADIOTHERAPEUTIC AND RADIOLOGICAL ASPECTS OF RADIATION FIBROSIS OF THE LUNGS*

BY

WILLIAM M. ROSS

From Newcastle Regional Hospital Board

(RECEIVED FOR PUBLICATION FEBRUARY 23, 1956)

All ionizing radiations tend to produce changes in all tissues through which they pass, and if an adequate dose is delivered inflammation leading to scarring will ensue. In the lung the earliest description I have found of such changes, based on clinical examination, was in 1896. By 1922 the effects of radiations on the lung were sufficiently well known for descriptions of the symptoms and morbid anatomical features to be published, and very soon afterwards efforts were made to plan radiotherapy of the breast so as to avoid directing radiations perpendicularly into the chest. Before the last war Dr. Levitt had reached the conclusion that it was in some cases possible to cure carcinoma of the oesophagus by deep *x*-ray therapy, but only at the expense of pulmonary fibrosis which was often crippling and sometimes fatal. In 1934 and 1940 Engelstad described the histological changes in the lungs of experimental animals and of patients whose chests had been irradiated, as also did Shields Warren and Spencer in the latter year.

In the term " post-radiation fibrosis " is included the sequence of events from the time of treatment onwards, comprising the initial inflammation and any subsequent changes, such as resolution and fibrosis.

Radiation fibrosis of the lungs is likely to be encountered in any patient in whom the chest has been irradiated. I have already referred to experiences in treating oesophageal tumours. Bronchogenic carcinoma is a much more common condition, but the interpretation of the symptoms, signs, and radiographs after radiation therapy of a lung carcinoma is difficult and one cannot with certainty differentiate the effects of *x*-rays from those of infection and tumour, although I have no doubt that patients with bronchial cancer treated by deep *x*-ray therapy develop post-radiation fibrosis. There is a small group of patients, in whom the diagnosis of bronchogenic carcinoma is made, without histological proof, and who receive deep *x*-ray therapy, but in whom the diagnosis must be open to grave suspicion when after some years there is no evidence of further extension of the carcinoma. In a few such patients, one sees features closely resembling those described below, which are purely those of radiation scarring. A further group of patients in whom the chest is irradiated is that of the malignant reticuloses, but in them the picture is complicated by the possibility of lymphatic infiltration into the lung parenchyma and of infections and structural changes distal to a deformity of the bronchial tree caused by enlarged hilar glands. In these patients, too, the ionizing radiations are frequently directed towards the mediastinum rather than the peripheral lung tissue, and the dose delivered is often limited to 2,000 röntgens or less. For all these reasons, post-radiation scarring of the lungs has not been seen in Newcastle as a sharply defined syndrome in this group of patients, as has been described in other centres (Whitfield, Bond, and Arnott, 1954; Whitfield, Lannigan, and Bond, 1954).

This communication deals, therefore, with those patients treated by deep *x*-ray therapy for carcinoma of the breast, a very important class of patient for a number of reasons. Carcinoma of the breast is to-day one of the commonest tumours treated in radiotherapy departments; the average survival is greater than in any of the diseases I have mentioned above; the lung subjacent to the breast which is irradiated and in which fibrosis occurs is previously normal, and the disability due to scarring is very real and important to an otherwise fit patient. I think it is beyond the scope of this paper to justify the use of radiotherapy in the management of breast carcinoma. In general, the tissues which are irradiated are the breast, if it has not been amputated, the chest wall from the mid-line to the posterior axillary line, and the

* Based on a paper presented before the Thoracic Society on July 2, 1955.

axillary, supraclavicular, and internal mammary lymph nodes on the same side. This block of tissue is treated as one mass, as nearly as possible to uniform dosage, the aim being to deliver a dose which is believed to be lethal to the cancer cells. In practice, however, one is usually limited by the expected tolerance of the irradiated skin. As mentioned, treatment techniques have been designed for over 30 years so as to attempt to limit the dose to the underlying lung, and one method of doing this was to use a relatively soft radiation for the treatment of the chest wall as opposed to the lymph node areas. This method had the disadvantage of increased differential absorption in bone, causing frequent rib necroses in later years, and it failed to abolish lung fibrosis, and therefore it has been largely abandoned in favour of what is known as the "glancing technique" in which the chest wall is irradiated by hard *x*-rays directed tangentially to the chest wall, so that only a relatively shallow segment of the peripheral pulmonary tissue is included within the *x*-ray beam. Kaplan and Bell (1938) considered that such a glancing technique did not damage normal lung tissue, and Chu, Phillips, Nickson, and McPhee (1955) published a series of cases in which only 7% of those treated by conventional *x*-ray therapy developed what they prefer to call "pneumonitis." Of the standard works on radiotherapy in this country at present, one says: "As a sequel to irradiation, there will always be some degree of superficial lung fibrosis in the slice irradiated and there may be a pleural reaction. These can be disregarded, but must be remembered when assessing the importance of slight shadowing in any subsequent radiograph" (Paterson, 1948); while another says: "If heavy irradiation is directed through the chest wall, pneumonitis with subsequent fibrosis which may be of great severity is likely to develop" (Carling, Windeyer, and Smithers, 1955).

Incidence of Post-radiation Fibrosis

Our experience in Newcastle led us to form the impression that even with the use of a glancing technique the development of post-radiation fibrosis was considerably more frequent than these publications would suggest, and I therefore studied a consecutive series of 58 cases treated at one hospital in 1952–53. The great majority of these patients had the glancing technique, a few for various reasons had direct fields on the supraclavicular and axillary regions without irradiation of the chest wall, but all appeared to develop this form of scarring with equal facility. Our policy has been, and is, to give as high a dose as is practicable, although we know that radiotherapists elsewhere might not subscribe to our views, and the frequency of fibrosis in our experience is almost certainly associated with this policy. Of the 58 patients, three failed to attend regularly for follow-up examinations and died before reliable evidence of the state of their lungs could be obtained, and a further six died within about a year with widespread metastases including intrathoracic deposits, and have been excluded from the analysis. In the case of the remaining 49, serial radiographs have been taken at frequent intervals. Five showed no convincing evidence of post-radiation changes in the underlying lung, 23 showed changes which have been assessed as mild, and 21 showed more severe changes. It is not possible to be certain of the exact dosage received within the affected parts of the lungs in these patients, nor to compare the slightly different volumes of lung which were irradiated, but all were given a radical course of treatment, and I think it is unnecessary to postulate that the lungs of these different patients received different doses, because similar differences in the response to radiotherapy are seen in other tissues such as the skin, mucous membranes, and haemopoietic tissues, to name only a few. I have not been able to correlate the severity of post-scarring of the lungs in these patients with the intensity of the reaction in the overlying skin and ribs, or with the symptoms of which these patients complain or to which they admit when closely questioned. Some patients with quite severe changes in the radiographs show only slight skin pigmentation, while in others the reverse is true, and in at least two patients I have seen post-radiation fractures of ribs developing where the evidence of lung scarring is minimal. While in general the patients with the more marked radiological changes have more dyspnoea and productive cough than those with less abnormality in their radiographs, the correlation is by no means an absolute one, nor have I been able to show any greater tendency to this form of post-radiation scarring in the older group of women who might be expected to have a greater degree of pulmonary arteriosclerosis.

Radiological Features

In 1939 McIntosh and Spitz described four grades of radiological change as follows:

(1) Increased vascular markings, or a generalized homogeneous haze, that is to say a pleural reaction, either of these features being temporary; (2) either or both of the above plus small patches of peribronchial exudative reaction and possibly elevation of the diaphragm; (3) confluent areas of

exudation, retraction of the mediastinum, contraction of the lung, and elevation of the diaphragm; (4) extensive confluence of exudation, and marked contraction of the lung producing almost complete consolidation.

In 1940 Warren and Spencer claimed that the earliest radiological change was increased translucency, followed after a few weeks by increased density within the treated area with discrete bands and displacement of the mediastinum, and the other features which I have already mentioned. They stated that the acute reaction coincides with the height of the cutaneous reaction, and that the condition may proceed to complete regression or may leave residual fibrosis. Bergmann and Graham (1951) considered that there may be increased translucency first, but more often a diffuse haziness was seen followed by irregular patchy consolidations and pleural reaction, with later pulmonary sclerosis and shrinkage, possibly with bronchiectatic cavities. In none of the cases we have seen in Newcastle has there been any suggestion of even transient increased translucency of the affected area of the lung as the first sign of radiation changes, and I would suggest that the radiological appearances which we recognize be considered under three headings.

(1) Parenchymal Reaction.—The parenchymal reaction is first evident as a homogeneous or patchy area of increased density in the irradiated zone of the lung and it is, I think, due to an exudative reaction in the alveoli and bronchioles which have been irradiated, with some degree of collapse. At this stage the process is presumably a "pneumonitis." Although it is very difficult to deliver comparable doses to two volumes of lung, one immediately beneath the chest wall and another nearer the hilum, my impression is that the reaction is more marked in the peripheral tissues and this would accord with the known tendency to endarteritis of the small vessels after irradiation, a phenomenon more likely to be important in a minute or terminal artery than in a major one. This parenchymal opacity tends in a small number of cases to resolve, though I do not recollect the radiological appearances ever becoming quite normal again, but in the majority it tends to become smaller and more dense. Subsequently streaky shadows appear between this peripheral shadow and the lung hilum which, with the mediastinum, is slowly displaced towards the affected side. In a number of cases dilatation of the bronchioles of the affected area of lung then develops and bronchiectasis can be demonstrated by tomography and bronchography. This parenchymal reaction is most commonly located in the lateral part of the infraclavicular region of the lung. Only rarely does it appear above the clavicle, probably as a result of contraction of the scarred tissue, and then it is associated with displacement of the mediastinum and elevation of the interlobar fissure.

(2) Pleural Reaction.—The second feature is the pleural reaction to the treatment. Very occasionally, this may appear as a uniform haze within the treated area, but much more frequently in my experience it is first evident as a small effusion accumulating under the influence of gravity at the lowest possible level. The pleural reaction may resolve but as a rule is followed by adhesions which contract and contribute to the reduction in volume of the affected lung. While both the parenchymal and the pleural reactions are commonly seen in the same patient, either may be seen alone, and the relative degree of the two types of response to the irradiation varies markedly.

(3) Thirdly, there remains a further syndrome seen in a small group of patients who present some months after treatment in poor general condition, with acute dyspnoea, and whose radiographs show diffuse patches of opacity not limited to the treated area and often bilateral in distribution. Over a period of some weeks to a few months their general condition slowly improves, the dyspnoea becomes less distressing, and the radiographic appearances may ultimately be closely similar to those seen in patients whose disease has run the more normal course. The fact that the radiological changes are not confined to the irradiated tissues suggests that an additional factor, probably infective, is present in these cases. Subsequent resolution is radiologically complete in the non-irradiated tissues but incomplete in those parts of the lung treated by deep *x*-rays. This syndrome was not encountered in any of the 58 patients referred to above.

Interval between Treatment and Fibrosis

The course of radiotherapy lasts between three and four weeks and no convincing evidence of any radiographic change in the lungs was seen during the treatment or the first month after it. The first radiographic abnormality was observed, in almost all cases, between two and six months after the end of treatment, and the whole process then unfolded over the following 18 months to two years, by the end of which period one has a very good idea of what the ultimate state of the irradiated lung is likely to be. One knows that

in the more severe cases further contraction of the scarred tissue may continue for some years, but there is no evidence that later changes are likely in the less severely affected patients. The cutaneous reaction to the treatment, on the other hand, is at its height at about one week after the end of treatment, and resolution has usually become maximal within three months. In other words, the pulmonary and cutaneous reactions are not maximal at the same time. In the lung as in the skin it seems probable that where there is severe scarring late necrosis may be precipitated at any time by such factors as local trauma or secondary infection.

Differential Diagnosis

The differential diagnosis is an important aspect of this subject, and the particular conditions from which post-radiation fibrosis must be distinguished are fibrosis of the lung due to other agents, pulmonary tuberculosis, and extension of the tumour for which the patient has been treated. Engelstad considered that there were no characteristic radiological features of this particular form of pulmonary fibrosis and that confirmation of the diagnosis required prolonged observation. Bergmann and Graham agreed that there is no specific pattern for the radiological appearances, and I think that the differential diagnosis from fibrosis of the lung due to agents other than ionizing radiations must depend largely on the history. The possibility of pulmonary tuberculosis being diagnosed is increased by the fact that the changes described in the lung parenchyma tend to be found most commonly in the infraclavicular zone of the lung, but there is of course very often an absence of the breast shadow on that side to give a valuable clue. It is not uncommon for patients to be examined by mass miniature radiography, and subsequently to be referred to a chest clinic because of changes due to post-radiation fibrosis. A clear history of the previous treatment may be neither asked for nor volunteered, and there may be no telltale skin changes. As an example of the errors which may be made, I quote the experience of a patient who, seven years after treatment of a carcinoma of the breast by conservative mastectomy and radiotherapy, attended for miniature radiological examination "because her friend was going." Evidence of post-radiation scarring was misinterpreted, and, despite the failure to isolate tubercle bacilli from her very scanty sputum, she was treated by bed rest and chemotherapy until, after three months, the next routine follow-up examination was due and the error was discovered. In radiotherapy departments, differentiation from metastases is probably more important, especially in those conditions for which further irradiation may be given if the diagnosis of extension of the malignant disease is confirmed, but in further irradiation of a lung the site of post-radiation scarring should be avoided. The recognition of post-radiation scarring depends largely, I think, on the awareness of the possibility of its existence

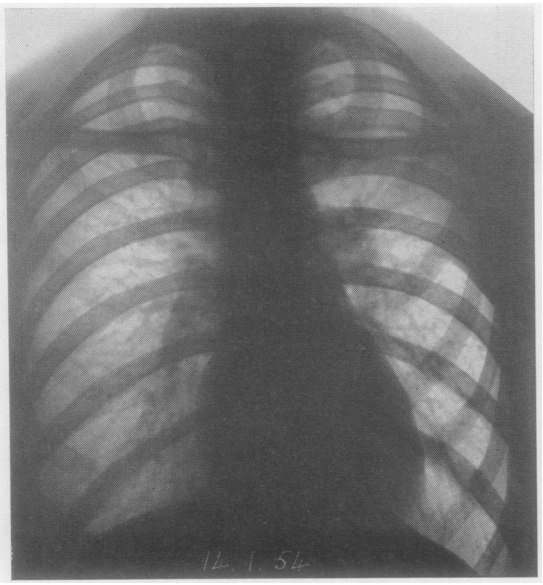

Fig. 1

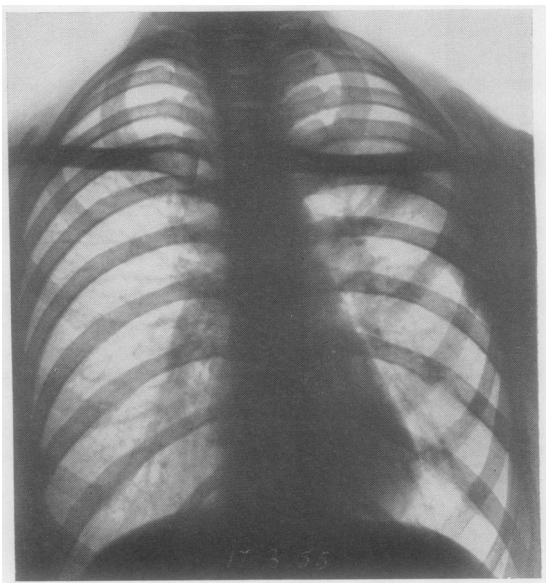

Fig. 2

and on a careful study of its distribution within the chest. In those cases where no further radiation treatment is contemplated, observation over a period of some months will enable an accurate diagnosis to be reached.

Case Histories

A small selection of representative films from the several hundred cases which have been treated and subsequently observed in the Follow-up Clinic is shown.

Figs. 1 and 2, Miss J. H., aged 27.—These films show mild post-radiation changes in the area of lung subjacent to the irradiated chest wall. The scarring is most evident one year after the treatment (Fig. 1), and in the subsequent year some resolution has occurred (Fig. 2), but the appearances have not quite returned to normal. The telltale sign of the missing breast shadow will be noticed.

Figs. 3, 4, and 5, Mrs. E. K., aged 53.—These films show moderately severe post-radiation scarring, first evident between two and three months after treatment, at which time the patient complained of some discomfort in the left chest which improved after six to eight months. At no time has she complained of cough or dyspnoea. The radiographs show a diffuse opacity in the upper zone of the chest three months after treatment (Fig. 3) which subsequently became

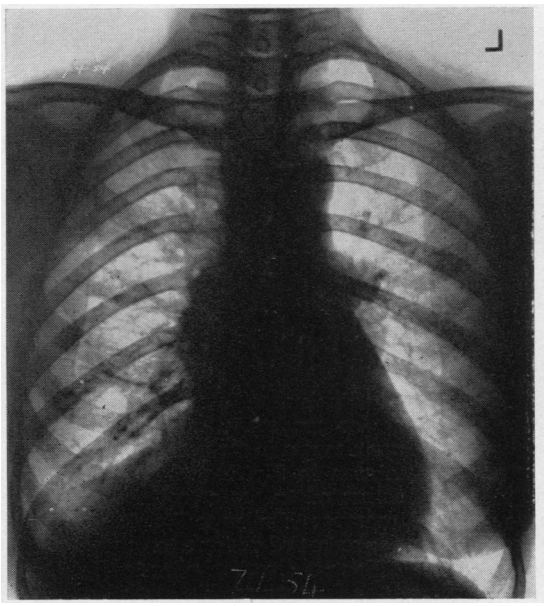

Fig. 3

more localized and more dense with a reduction in the size of the upper lobe and elevation of the interlobar fissure (Figs. 4 and 5). Because of the contraction of the scar tissue the densest opacity due to post-radiation changes is now seen to be behind the clavicle.

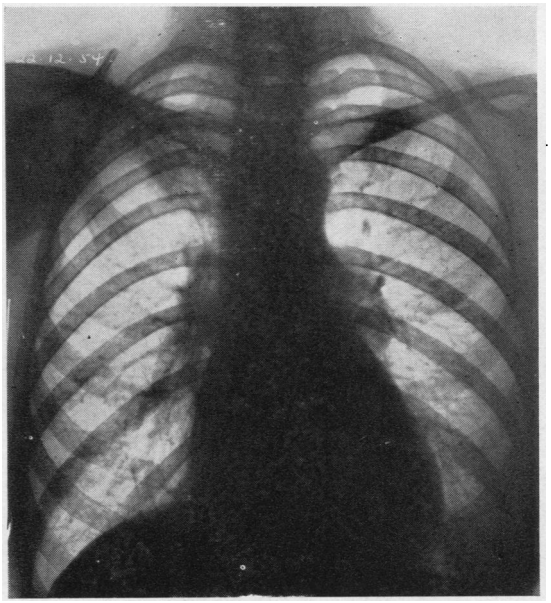

Fig. 4

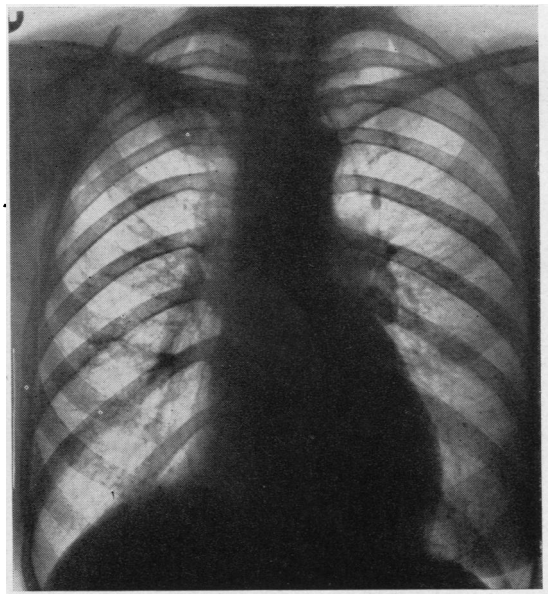

Fig. 5

Figs. 6, 7, and 8, Mrs. M. C., aged 49.—These films show rather more severe changes in the affected part of the lung. This patient has had an intermittent productive cough since two months after her treatment. A year later the cough became troublesome and she had occasional frank haemoptyses. At that time the postero-anterior film of the chest (Fig. 6) shows a typical opacity in the upper zone with dis-

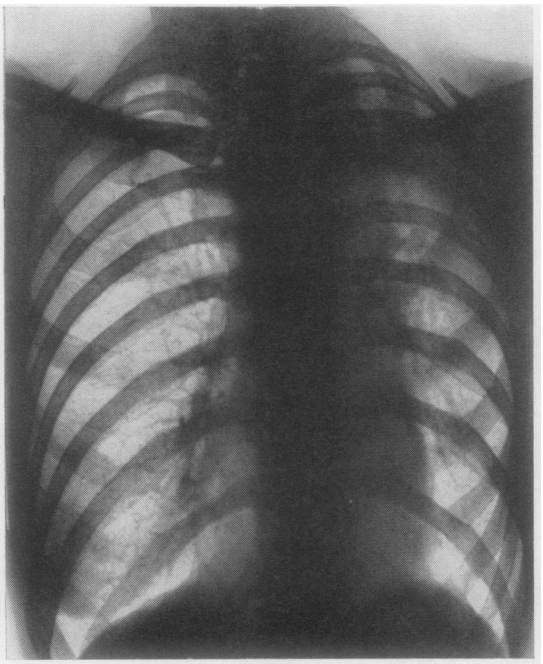

FIG. 6

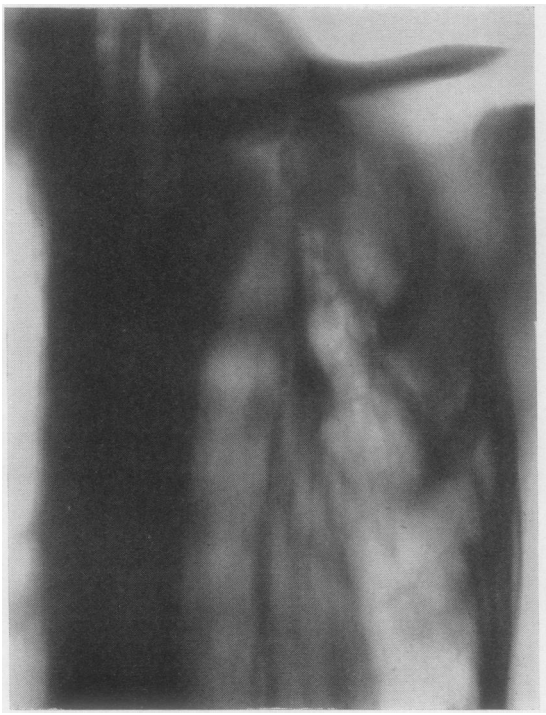

FIG. 7

placement of the trachea towards it and a suggestion of multiple small cavities within the opaque area. Tomography (Fig. 7) confirmed these appearances, and the bronchogram (Fig. 8) shows crowding of the bronchi in the irradiated lung and irregular dilatation of their lumina. In the succeeding year this patient's radiographs showed scarcely any change. Her symptoms improved considerably during the summer months, but have again been more persistent during the cold weather though she has not had any further haemoptyses.

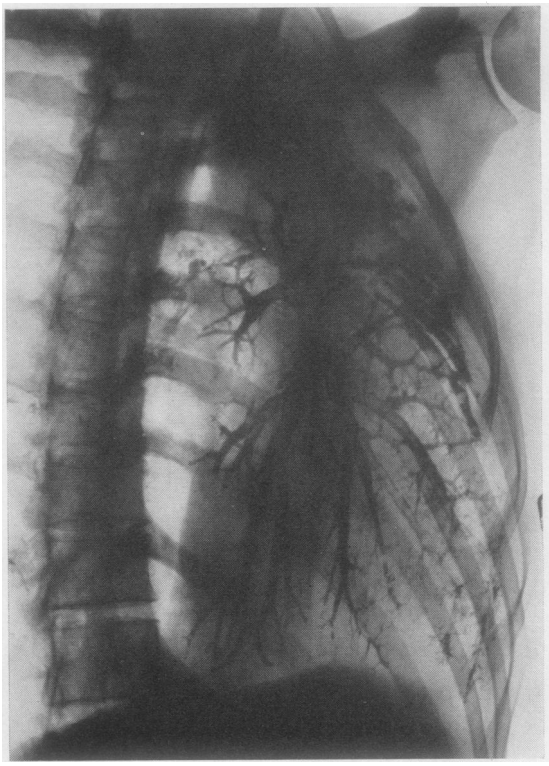

FIG. 8

Bronchography has been advised only in patients with haemoptysis or productive cough with copious sputum and severe changes in the postero-anterior film similar to those seen in Fig. 6. As yet only three patients have consented to the examination, and all have shown appearances similar to Fig. 8. In a considerably greater number of patients tomographs have been obtained which are closely similar to Fig. 7, and as this examination is more readily carried out Figs. 7 and 8 are shown together for comparison.

FIGS. 9, 10, AND 11, MRS. I. E., AGED 45.—These films show a relatively mild degree of parenchymal post-radiation fibrosis although the last film (Fig. 11) shows fractures of the third to seventh ribs on the affected side and the overlying skin is the site of gross scarring with a tendency to indolent superficial ulcera-

tion, demonstrating that there is not necessarily a close correlation between the severity of the skin and lung changes. The films are shown mainly to demonstrate the pleural changes. Three months after treatment the patient complained of cough and dyspnoea, and a radiograph (Fig. 9) showed a small effusion in the costophrenic sinus which resolved after a few months (Fig. 10) but has been followed by a later recurrence, and she now has an obliterated sinus (Fig. 11). Her cough and dyspnoea are much improved.

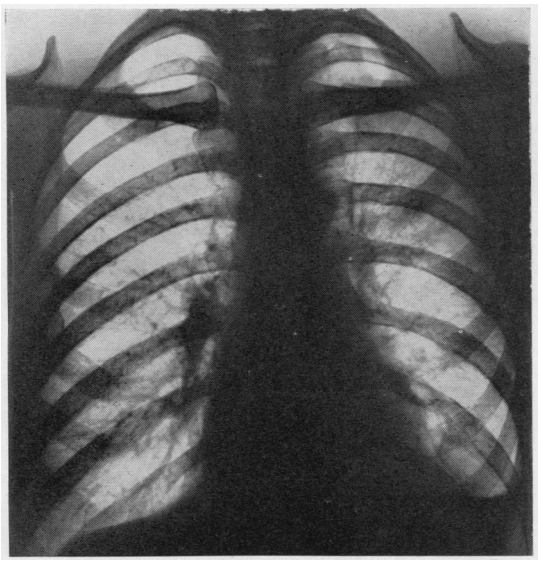

FIG 9

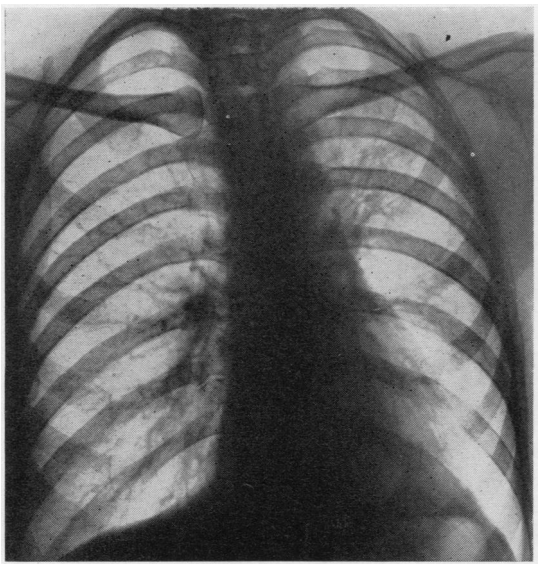

FIG. 10

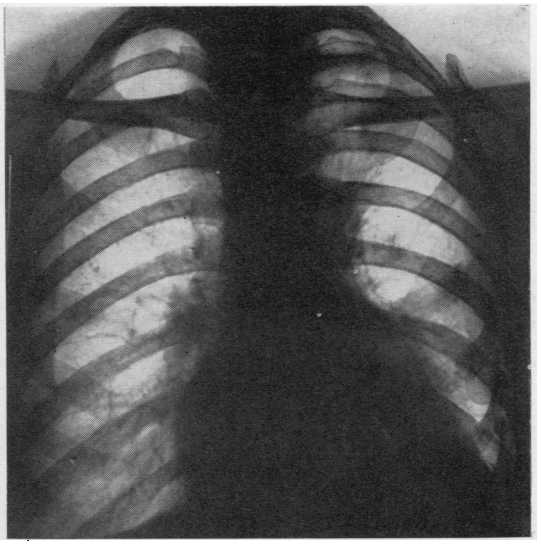

FIG. 11

FIG. 12, MRS. V. W., AGED 53.—This patient has been symptom-free since her treatment, although the radiographs show a moderate degree of post-radiation scarring. Six months after the treatment there was gross elevation of the anterior part of the right side of the diaphragm as shown in Fig. 12. A lateral film at that time excluded any suggestion of parenchymal collapse. Subsequent films over two years have shown that the elevation of the diaphragm has slowly become less marked.

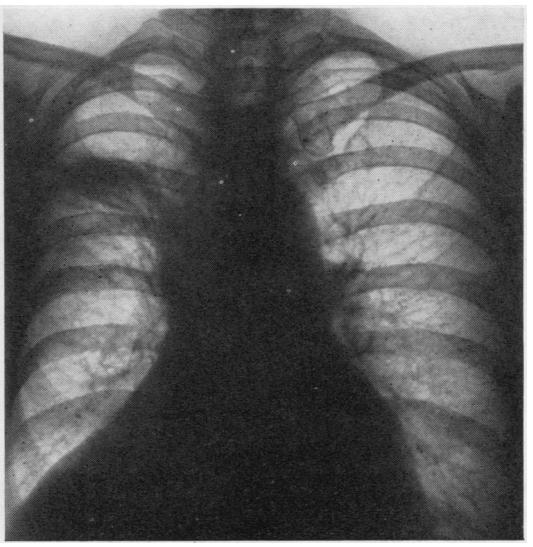

FIG. 12

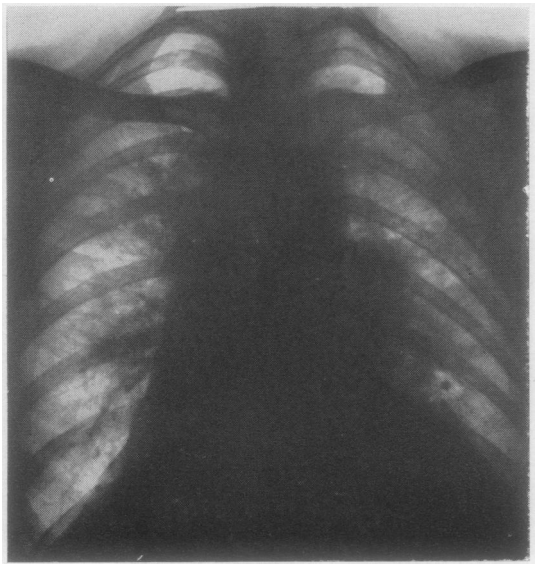

FIG. 13

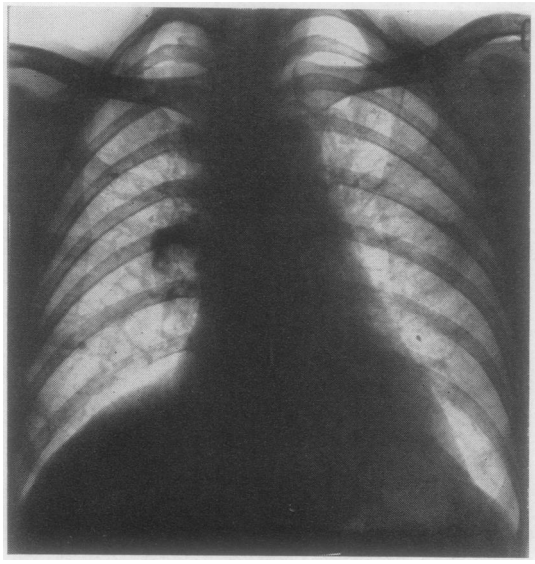

FIG. 14

FIGS. 13 AND 14, MRS. E. R., AGED 60.—This patient had bilateral carcinomas of the breasts, for which local amputations were carried out in April and May, 1954. In June she had a course of deep *x*-ray therapy limited to the supraclavicular and internal mammary lymph node areas on both sides. For three months after the treatment she was quite well, but in October she became ill with severe dyspnoea and malaise. After a few weeks this began to improve, although she never became symptom-free. The films show opacities in both lungs which are largely outside the irradiated tissues but which, after some months, slowly changed to present an appearance more like that usually seen in post-radiation scarring. She subsequently developed multiple metastases, skeletal at first, and later in the abdomen, but was never found to have pleural or pulmonary deposits.

These two films illustrate the atypical syndrome described under the third heading above.

CONCLUSION

When part of a lung is irradiated to high dosage by conventional radiotherapy, as in the treatment of patients with carcinoma of the breast, it is our experience that the majority of patients will develop radiological evidence of scarring in the lung, a small number will have troublesome symptoms, and a minority will develop acute dyspnoea or bronchiectasis. We recognize this syndrome as a sequel of intensive radiotherapy using conventional apparatus and techniques. There is not yet sufficient evidence to show whether a similar process follows treatment by radiotherapy in the megavoltage range. Clinical trials are proceeding in an attempt to determine the best method of management of patients affected by the syndrome.

SUMMARY

The literature concerning scarring of the lung due to irradiation is briefly summarized.

It is shown that about 90% of patients treated by conventional deep *x*-ray therapy for carcinoma of the breast develop some degree of post-radiation fibrosis. The radiological features are described, and the differential diagnosis is discussed.

It is a pleasure to thank Mr. C. J. L. Thurgar for encouragement in making this study, and for permission to refer to the cases; Dr. S. Whately Davidson for discussing the radiological features; Mr. G. A. Mason for the bronchograms performed by members of his staff; and my colleagues, radiotherapeutic and radiological, who have helped in the management of the patients.

REFERENCES

Bergmann, M., and Graham, E. A. (1951). *J. thorac. Surg.*, **22**, 549.
Carling, E. Rock, Windeyer, B. W., and Smithers, D. W. (1955). *British Practice in Radiotherapy*, p. 143. London.
Chu, F. C. H., Phillips, R., Nickson, J. J., and McPhee, J. G. (1955). *Radiology*, **64**, 642.
Engelstad, R. B. (1934). *Acta radiol.* (*Stock.*), Suppl. 19.
—— (1940). *Amer. J. Roentgenol.*, **43**, 676.
Kaplan, I. I., and Bell, D. (1938). Ibid., **39**, 387.
McIntosh, H. C., and Spitz, S. (1939). Ibid., **41**, 605.
Paterson, R. (1948). *The Treatment of Malignant Disease by Radium and X-rays*, p. 136. Arnold, London.
Warren, S., and Spencer, J. (1940). *Amer. J. Roentgenol.*, **43**, 682.
Whitfield, A. G. W., Bond, W. H., and Arnott, W. M. (1954). *J. Fac. Radiol.* (*Lond.*), **6**, 12.
—— Lannigan, R., and Bond, W. H. (1954). *Lancet*, **2**, 117.