ANSWER

From the question on page 1082

The lung biopsy showed a picture consistent with a congenital surfactant deficiency (either of protein B or C) or the absence of lamellar bodies in alveolar type 2 cells (fig 1).

Genetic analysis showed a de novo mutation in SFTP-C gene (I73T aminoacidic substitution). Diagnosis of surfactant protein C deficiency (SP-C) was formulated.

Hydroxychloroquine 10 mg/kg/day was started in the first twin, preceded by 3 months of prednisone 2 mg/kg/day because of the severity of the disease. As they began treatment, only one episode of upper airway infection occurred. After 18 months of continuous hydroxychloroquine treatment the respiratory rate at rest was 36/min and 34/min, respectively, and oxygen saturation 99%. The levels of physical activity were normal for age, digital clubbing was no longer evident and height raised back to 25° centile.

Surfactant protein C deficiency

Mutations in SFTP-C gene cause certain forms of interstitial lung disease which present both as recurrent lung infection and chronic hypoxaemia, cyanosis, clubbing and growth failure.[1] Moreover, I73T mutation is associated with an interfamilial phenotypic variability. Surfactant C seems to play an important role as a hydrophobic protein in stabilisation of surfactant. In heterozygous mutations the aberrant protein interacts with the regular pathway of regular SP-C biosynthesis, leading to inhibition of functionally active SP-C production. Lung damage is therefore induced both by SP-C deficiency in the alveolus and by aberrant proSP-C that cannot be handled by the protein degradation pathway and induces cellular injury and pulmonary inflammation.

In these patients hydroxychloroquine treatment seemed effective. Since prednisone was also used in one of the twins, a possible benefit from the combination of the two drugs can also be suggested. A worsening of the clinical condition after interruption of treatment would be needed to firmly confirm efficacy, even though the long lasting clinical improvement was remarkable.

The exact mechanism of action of hydroxychloroquine is unknown. Antimalarial agents have profound effects on macrophages by interfering with antigen presentation, by inhibiting production of inflammatory mediators such as interleukin (IL)1 and IL6 and by inhibiting activation of toll-like receptors. In SP-C deficiency the drug may act not only through an anti-inflammatory action but also by blocking the intracellular processing of SP-C precursors.[2] To our knowledge, only very few cases of SP-C deficiency successfully treated with hydroxychloroquine have been reported.[3 4]

SP-C deficiency should be suspected in any case of unusually severe recurrent lung infections or undiagnosed interstitial lung disease in infants.

Thorax 2008;**63**:1090. doi:10.1136/thx.2007.092650a

REFERENCES

1. **Hartl D,** Griese M. Interstitial lung disease in children: genetic background and associated phenotypes. *Respir Res* 2005;**6**:32.
2. **Beers MF.** Inhibition of cellular processing of surfactant protein C by drugs affecting intracellular pH gradients. *J Biol Chem* 1996;**271**:14361–70.
3. **Rosen DM,** Waltz DA. Hydroxychloroquine treatment and surfactant protein C deficiency. *N Engl J Med* 2005;**352**:207–8.
4. **Amin RS,** Wert SE, Baughman RP, *et al*. Surfactant protein deficiency in familial interstitial lung disease. *J Pediatr* 2001;**139**:85–92.

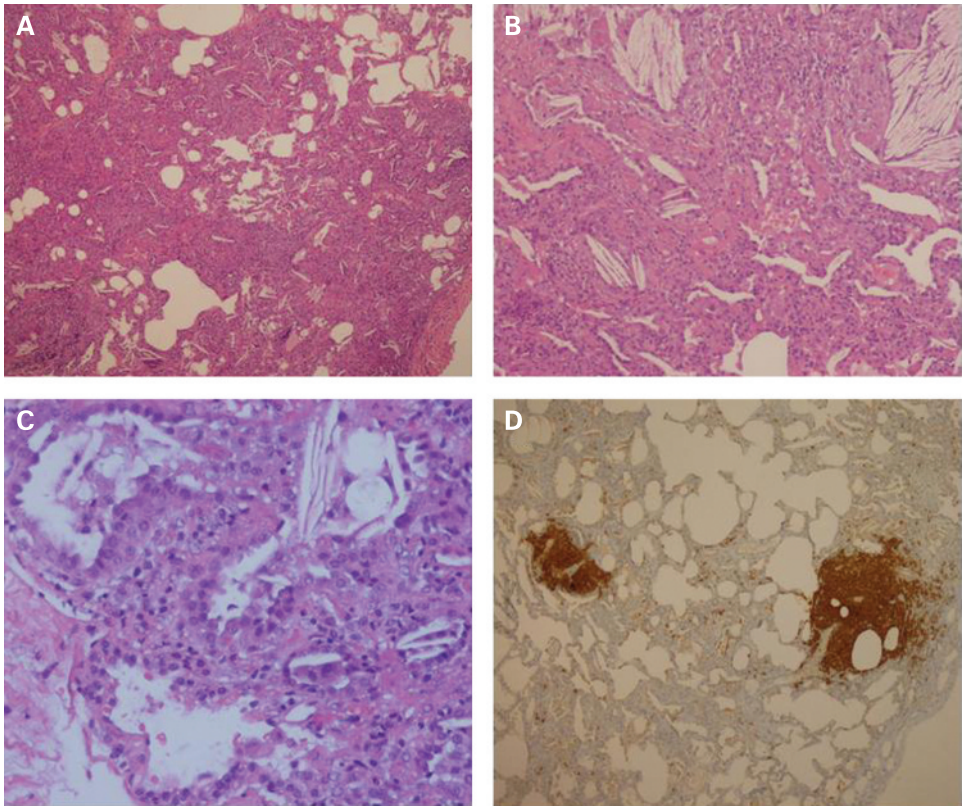

Figure 1 (A) Open lung biopsy showing diffuse hypercellularity of alveolar walls and airspaces with focal overdistension due to disventilation. (B) Severe alveolar septal widening by chronic inflammatory cell infiltration (lymphocytes and histiocytes) without significant fibrosis. The airspaces show an increase in alveolar macrophages with diffuse phagocytosis of cholesterol clefts (endogenous lipidic alveolitis). (C) Focal PN2 cuboidal metaplastic changes with airspace consolidation by clustered alveolar macrophages (DIP-like pattern of macrophagic alveolitis). (D) BALT hyperplasia with predominant B lymphocytes CD20 positive.

Thorax: first published as 10.1136/thx.2007.092650a on 19 November 2008. Downloaded from http://thorax.bmj.com/ on April 16, 2024 by guest. Protected by copyright.

25. **Mattes J,** Storm van's Gravesande K, Reining U, *et al*. NO in exhaled air is correlated with markers of eosinophilic airway inflammation in corticosteroid-dependent childhood asthma. *Eur Respir J* 1999;**13**:1391–5.
26. **Bisgaard H,** Loland L, Oj JA. NO in exhaled air of asthmatic children is reduced by the leukotriene receptor antagonist montelukast. *Am J Respir Crit Care Med* 1999;**160**:1227–31.
27. **Rolla G,** Di Emanuele A, Dutto L, *et al*. Effect of inhalation aspirin challenge on exhaled nitric oxide in patients with aspirin-inducible asthma. *Allergy* 2004;**59**:827–32.
28. **Gaber F,** Acevedo F, Delin I, *et al*. Saliva is one likely source of leukotriene B4 in exhaled breath condensate. *Eur Respir J* 2006;**28**:1229–35.
29. **Maclouf J,** Antoine C, De Caterina R, *et al*. Entry rate and metabolism of leukotriene C4 into vascular compartment in healthy subjects. *Am J Physiol* 1992;**263**:H244–9.
30. **Green FA,** Claesson HE, Hamberg M. Lipoxygenase products from polymorphonuclear leukocytes and epithelial cells of human saliva. *Arch Biochem Biophys* 1987;**257**:321–7.
31. **Wallaert B,** Janin A, Lassalle P, *et al*. Airway-like inflammation of minor salivary gland in bronchial asthma. *Am J Respir Crit Care Med* 1994;**150**:802–9.
32. **Peters-Golden M,** Henderson WR Jr. Leukotrienes. *N Engl J Med* 2007;**357**:1841–54.

Pulmonary puzzle

Twins with severe recurrent chest infections

CLINICAL PRESENTATION

Two homozygotic twins were delivered at 31 weeks of gestational age by caesarean section, with birth weight 1490 and 1710 g, respectively. The family history was unremarkable. Their mother received steroid prophylaxis for hyaline membrane disease. They showed no perinatal problems. By the age of 8 months both had recurrent spells of respiratory distress, possibly triggered by viral infections, characterised by cough, fever, wheezing, tachypnoea, dyspnoea, desaturation, bilateral crackles and chest radiographs suggestive of an acute interstitial involvement. One twin had four admissions (two of these required orotracheal intubation) and the other had three (one with intubation). Each time they were empirically treated with oxygen, antibiotics, steroids and nebulised bronchodilators. Endotracheal tube suction cultures and tests for cytomegalovirus, *Pneumocystis* and *Mycoplasma* were negative.

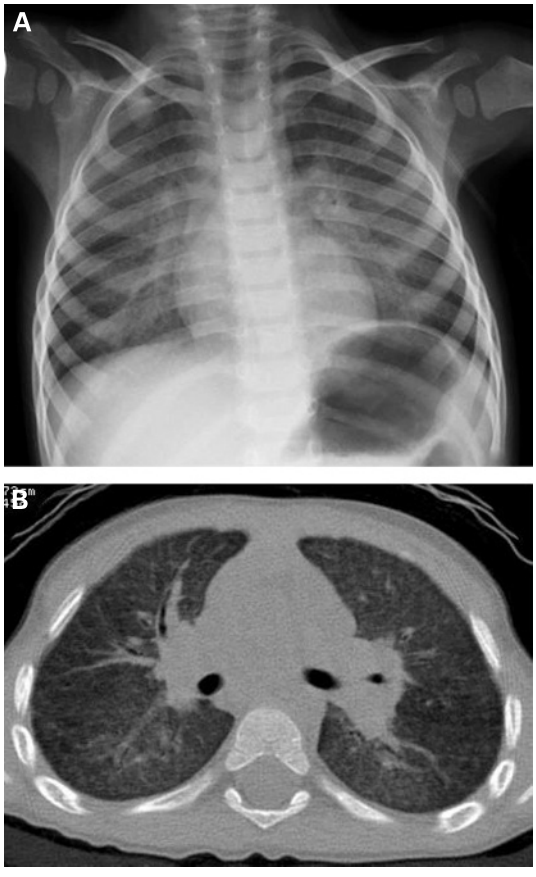

Figure 1 (A) Chest radiograph showing bilateral diffuse interstitial alveolar involvement. (B) High-resolution CT scan of the chest showing diffuse ground glass attenuation with interstitial pattern and fine nodules due to alveolar infiltrates throughout the lungs.

By 11 months of age both showed progressive growth impairment (from 25° to 3° centile) and, in the following months, reduced levels of physical activity. Physical examination progressively showed digital clubbing, chest deformities with flattening of the anteroposterior diameter, tachypnoea at rest (respiratory rate 60/min and 50/min) with oxygen saturation of 97% in both and no requirement for domiciliary oxygen.

Sweat tests, immunoglobulin levels, fecal elastase levels and lymphocyte subsets were normal. Genetic tests for cystic fibrosis, Schwachmann disease and mannose binding lectin deficiency were negative. The cardioechogram was normal with no evidence of pulmonary hypertension.

At the age of 30 months a chest radiograph performed in the twin with the most severe clinical history during a period of well being showed persistent findings of interstitial alveolar involvement (fig 1A). At that age his respiratory rate at rest was 60/min, heart rate 120/min, oxygen saturation 97% with digital clubbing. In the same twin a high-resolution CT scan of the chest revealed ground glass attenuation with interstitial pattern and fine nodules throughout the lungs (fig 1B).

QUESTION

What is your diagnosis?

See page 1090

This case was submitted by:

F Minen,[1] E Barbi,[1] A Ventura,[1] P Carrera,[2] F Zennaro,[3] P Chiodera[4]

[1] Department of Pediatrics, IRCCS Burlo Garofolo, Trieste, Italy; [2] San Raffaele Scientific Institute and Laboraf, Molecular Biology, Milan, Italy; [3] Department of Pediatric Radiology, IRCCS Burlo Garofolo, Trieste, Italy; [4] Department of Pathologic Anatomy and Citodiagnostic, Istituto Clinico S. Anna S.p.A., Brescia, Italy

Correspondence to: Dr F Minen, Department of Pediatrics, IRCCS Burlo Garofolo, Trieste 34100, Italy; federicominen@gmail.com

Competing interests: None.

Patient consent: Parental/guardian consent obtained.

Thorax 2008;**63**:1082. doi:10.1136/thx.2007.092650