

## CASE REPORT

## Acute respiratory distress syndrome due to pulmonary involvement by neoplastic plasma cells in multiple myeloma

D B Marmor, J L Farber, J E Gottlieb

Thorax 2006;61:455–456. doi: 10.1136/thx.2004.029397

Pulmonary involvement with multiple myeloma occurs infrequently and may be difficult to distinguish from more common primary lung tumours, metastatic disease, or other pleural and parenchymal abnormalities. A patient who developed acute respiratory distress syndrome (ARDS) was subsequently found to have multiple myeloma with involvement of lung parenchyma by neoplastic plasma cells. Only one other report of ARDS in association with multiple myeloma was found, and there are no previous reports where the appearance of ARDS antedated a diagnosis of multiple myeloma. In patients with ARDS, parenchymal involvement from multiple myeloma should be included in the differential diagnosis.

A 65 year old woman was admitted to hospital complaining of dull pleuritic retrosternal chest pain of 5 days' duration. It had been somewhat relieved with non-steroidal anti-inflammatory drugs. She also complained of a cough and worsening dyspnoea upon exertion. A 2 month history of nausea was accompanied by a weight loss of 11 lb. Past medical history included non-insulin dependent diabetes, hypertension, asthma, and obesity.

On physical examination the patient initially appeared comfortable at rest but was dyspnoeic with limited activity. Her temperature was 101.7°F, heart rate 96 beats/min, respiratory rate 20 breaths/min, blood pressure 117/72 mm Hg. The only significant physical finding was bilateral basilar crackles. Laboratory data revealed a white blood cell count of 10 400/mm<sup>3</sup> and haemoglobin of 9.7 g/dl. The serum sodium was 131 mEq/l, total calcium 8.5 mg/dl, and creatinine 1.0 mg/dl. Urinalysis revealed trace protein. The chest radiograph showed bilateral multifocal areas of nodular consolidation (fig 1), and the ECG showed normal sinus rhythm with diffuse non-specific T wave abnormalities. Serum troponin levels were normal. Oxygen saturation was 88% on room air and 94% on 5 l oxygen via nasal cannulae.

The patient's respiratory status steadily declined over the ensuing days, despite treatment with antibiotics for presumed pneumonia. Four days after admission she was in acute respiratory distress with tachypnoea and the use of accessory muscles. Arterial blood gas showed pH 7.46, PaCO<sub>2</sub> 5.2 kPa, and PaO<sub>2</sub> 4.5 kPa on 50% Fio<sub>2</sub> non-rebreather mask. She required intubation and mechanical ventilation with a low tidal volume high positive end expiratory pressure protocol. Bronchoalveolar lavage yielded fluid that contained 40% macrophages, 25% neutrophils, and 35% lymphocytes. No malignant cells and no pathogens were identified. All blood, sputum, and urine cultures were negative. A chest CT scan showed diffuse, patchy, multifocal air space consolidation bilaterally with a nodular character, small bilateral pleural effusions, mediastinal lymphadenopathy, and a questionable lytic lesion of the T9 vertebra.

Ultrasound guided thoracentesis yielded 200 ml of bloody exudative effusion. Cytology was negative for malignant cells. Thoracoscopic biopsy revealed diffuse and nodular infiltration of the lung parenchyma by neoplastic plasma cells (fig 2). The 24 hour urine contained 918 mg protein, and immunoelectrophoresis revealed a monoclonal band in the gamma region identified as IgG kappa with excess kappa light chains. Serum immunoelectrophoresis similarly showed hypergammaglobulinaemia with a monoclonal IgG kappa band.

Treatment continued with piperacillin/tazobactam, azithromycin, and vancomycin for pneumonia, and methylprednisolone for myeloma. She was judged to be a poor candidate for more aggressive chemotherapy owing to progressive multisystem organ failure. In keeping with the patient's advance directive and after consultation with her family, supportive care was withdrawn. Permission for bone marrow biopsy or necropsy was withheld.

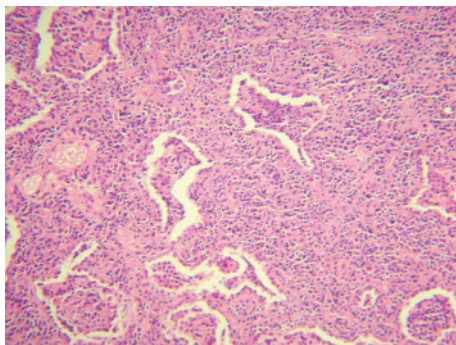
## DISCUSSION

This patient was diagnosed with multiple myeloma on the basis of a monoclonal serum protein spike, the presence of urinary Bence Jones proteins, and infiltration of the lungs by neoplastic plasma cells. She developed acute respiratory distress syndrome (ARDS) secondary to this nodular involvement of the lungs by the myeloma. Multiple myeloma presenting as ARDS has not been reported previously. Absence of leucocytosis on admission, failure to respond radiographically or clinically to antibiotics, the absence of positive cultures for microorganisms, and pathological findings without evidence of infectious pneumonia all argue against infection as a major factor contributing to the development of ARDS.

Multiple myeloma may involve the thorax in a variety of ways, but pulmonary parenchymal involvement is uncommon. Thoracic manifestations include skeletal abnormalities,

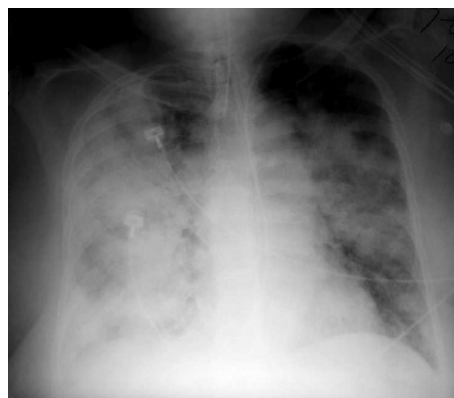

Figure 1 Chest radiograph showing bilateral multifocal areas of nodular consolidation.



**Figure 2** Photomicrograph of thoracoscopic biopsy specimen. Stain: haematoxylin/eosin; original magnification  $\times 10$ .

infiltrative processes, pleural effusions, plasmacytomas, and diaphragmatic dysfunction due to peripheral neuropathy. In a review of 958 patients with multiple myeloma at the Mayo Clinic, Kintzer *et al*<sup>1</sup> reviewed the thoracic and pulmonary abnormalities in multiple myeloma. Thoracic skeletal involvement, including osteolytic lesions of ribs or vertebrae, was the most common presentation, which occurred in 267 (28%) patients. Pulmonary infiltrates were seen in 95 patients (10%), the majority of which were attributed to infectious processes, presumably from altered host immunity. Pleural effusions were present in 58 patients (6%) and extramedullary plasmacytomas in 11 (1%).

Patients who have developed respiratory failure from pulmonary involvement in myeloma have only rarely been reported. Only eight cases of respiratory failure caused by multiple myeloma were identified. These cases span decades, and definitions of respiratory failure are inconsistent. Mechanisms of respiratory failure in these patients include both intraparenchymal and thoracic mechanical aetiologies.

The intraparenchymal causes of respiratory failure from multiple myeloma include alveolar septal amyloidosis, plasma cell infiltration of lung parenchyma, accumulation of alveolar paraproteins, and metastatic calcification of the alveolar walls and blood vessels.<sup>2-5</sup> One patient with respiratory failure and infiltration of lung tissue with plasma cells had been diagnosed with multiple myeloma 5 years earlier and developed respiratory failure following radiation therapy for an orbital plasmacytoma.<sup>3</sup> Two other patients without acute lung injury had bilateral lung densities on radiographic imaging and pathological evidence of neoplastic plasma cell infiltration of the lungs.<sup>6,7</sup> Chejfec *et al*<sup>6</sup> described the pulmonary infiltrates of neoplastic plasma cells with crystalline casts as "myeloma lung".

Poe *et al*<sup>2</sup> reported a patient with multiple myeloma and ARDS resulting from diffuse metastatic calcification of the alveoli and blood vessels. The lung calcification was thought to be due in part to the patient's existing renal failure and consequent hypercalcaemia.

Respiratory insufficiency without parenchymal involvement has also been described in association with multiple myeloma. Two distinct mechanisms are recognised: spontaneous flail chest and diaphragmatic dysfunction. Flail chest arises from multiple osteolytic rib lesions that lead to destabilisation of the rib cage with paradoxical breathing and respiratory failure.<sup>8,9</sup> Hypercapnic respiratory failure has been reported from diaphragmatic paralysis that resulted from chronic demyelinating polyneuropathy with phrenic nerve involvement.<sup>10</sup>

Multiple myeloma may produce varied patterns on chest radiographs including multiple masses mimicking solid tumour metastasis, diffuse interstitial disease from alveolar septal amyloidosis, or consolidation.<sup>11,12</sup> Our patient presented with a chest radiographic pattern that was consistent with the diagnosis of ARDS, as defined by the American-European Consensus Conference on ARDS.<sup>13</sup> However, both the ARDS Clinical Trials Network (in terms of inclusion criteria) and a recent review of "imitators" of ARDS highlight the pathophysiological heterogeneity that may underlie such a broad clinical definition.<sup>14,15</sup> Since our patient had neither prior history nor clinical evidence of multiple myeloma, this pathological diagnosis was not made until an open lung biopsy was obtained. A greater clinical suspicion could conceivably have resulted in bone marrow biopsy, thereby obviating the need for lung biopsy. We suggest that multiple myeloma with direct plasma cell invasion of pulmonary parenchyma be added to the list of pathological mechanisms that can produce the clinical syndrome of ARDS.

#### Authors' affiliations

**D B Marmor**, Department of Medicine, Jefferson Medical College, Philadelphia, PA 19107, USA

**J L Farber**, Department of Pathology, Jefferson Medical College, Philadelphia, PA 19107, USA

**J E Gottlieb**, Department of Pulmonary Medicine and Critical Care, Jefferson Medical College, Philadelphia, PA 19107, USA

Competing interests: none declared.

Correspondence to: Dr D B Marmor, Department of Medicine, Jefferson Medical College, Philadelphia, PA 19107, USA; david.marmor@jefferson.edu

Received 2 June 2004

Accepted 13 September 2004

#### REFERENCES

- 1 Kintzer JS, Rosenow EC III, Kyle RA. Thoracic and pulmonary abnormalities in multiple myeloma. A review of 958 cases. *Arch Intern Med* 1978;**138**:727-30.
- 2 Poe RH, Kamath C, Bauer MA, *et al*. Acute respiratory distress syndrome with pulmonary calcification in two patients with B cell malignancies. *Respiration* 1989;**56**:127-33.
- 3 Harinder G, Durie BGM. Aggressive phase of multiple myeloma with pulmonary plasma cell infiltrates. *JAMA* 1982;**248**:1875-6.
- 4 Meijer WG, Van Marwijk Kooy M, Ladde BE. A patient with multiple myeloma and respiratory insufficiency due to accumulation of paraprotein in the alveolar space. *Br J Haematol* 1994;**87**:663-5.
- 5 Morgan JE, McCaul DS, Rodriguez FH, *et al*. Pulmonary immunologic features of alveolar septal amyloidosis associated with multiple myeloma. *Chest* 1987;**92**:704-8.
- 6 Chejfec G, Ntarelli J, Gould VE. "Myeloma lung" – a previously unreported complication of multiple myeloma. *Hum Pathol* 1983;**14**:558-61.
- 7 Ludmerer KM, Kissane JM. Right arm weakness and pulmonary nodules in a 75 year old man with multiple myeloma. *Am J Med* 1993;**95**:101-10.
- 8 Fleegler B, Fogarty C, Owens G, *et al*. Pathologic flail chest complicating multiple myeloma. *Arch Intern Med* 1980;**140**:414-5.
- 9 Singh S, Lone AA, Khan BA, *et al*. Shortness of breath and diffuse chest pain. *Postgrad Med* 2000;**76**:721-31.
- 10 Dooley KE, Sinha SR, Haponik E, *et al*. A 39 year old man with hip pain and respiratory failure. *Chest* 2002;**121**:1345-9.
- 11 Shin MS, Carcelen MF, Ho KJ. Diverse roentgenographic manifestations of the rare pulmonary involvement in myeloma. *Chest* 1992;**102**:946-8.
- 12 Mouloupolous LA, Granfield CAJ, Dimopoulos MA, *et al*. Extraosseous multiple myeloma: imaging features. *AJR* 1993;**161**:1083-7.
- 13 Bernard GR, Artigas A, Brigham KL, *et al*. The American-European Consensus Conference on ARDS: definitions, mechanisms, relevant outcomes, and clinical trial coordination. *Am J Respir Crit Care Med* 1994;**149**:818-24.
- 14 National Heart, Lung, and Blood Institute ARDS Clinical Trials Network. Higher versus lower positive end-expiratory pressures in patients with the acute respiratory distress syndrome. *N Engl J Med* 2004;**351**:327-36.
- 15 Schwarz MI, Albert RK. Imitators of ARDS: implications for diagnosis and treatment. *Chest* 2004;**125**:1530-5.