

# Pulmonary *Mycobacterium* *malmoense* and aspergillus infection: a fatal combination?

Friederike G E Böllert, Patricia J Sime,  
William MacNee, Graham K Crompton

## Abstract

**Three patients with chronic obstructive pulmonary disease developed coexisting *Mycobacterium malmoense* and aspergillus infection. All suffered progressive lung destruction leading to early death despite prolonged antimycobacterial chemotherapy.**

(Thorax 1994;49:521-522)

Three cases of pulmonary *Mycobacterium malmoense* with superadded aspergillus infection are reported. All patients died within eight months of the first evidence of fungal infection/colonisation.

## Case 1

A 73 year old woman with longstanding chronic obstructive pulmonary disease (FEV<sub>1</sub> 1.0 l (predicted 1.7 l), FVC 1.8 l (predicted 2.4 l)) presented in August 1989 with fever, pleuritic chest pain, and weight loss. A chest radiograph showed right middle zone cavitation, fibrosis, and associated pleural thickening. Sputum was film positive for acid and alcohol fast bacilli (AAFB) and cultures grew *M. malmoense*. Quadruple chemotherapy was commenced (table). Isoniazid was later discontinued because of nausea and rifampicin was temporarily withdrawn because of hepatitis. A combination of compliance difficulties and toxicity resulted in a variable combination of antimycobacterial chemotherapy for a total of 17 months. Rifampicin and ethambutol were the mainstay, but streptomycin, ciprofloxacin, and rifabutin were used briefly. There was radiographic improvement but mycobacterial cultures remained positive throughout. In June 1991 the chest radiograph showed appearances typical of an aspergilloma in the right mid zone cavity and sputum was positive on culture for *A. fumigatus*. Rifampicin, ethambutol, and ciprofloxacin were restarted. The patient died in December 1991. Post mortem examination revealed an aspergilloma, *M. malmoense* bronchopneumonia with abscess formation in the right upper lobe, and a small gastrointestinal haemorrhage from a gastric ulcer as the causes of death.

## Antimycobacterial treatment used in the three cases

Case no	Age/sex	Antimycobacterial treatment	Duration of treatment
1	73/F	RMP,INH,EMB,PZA (Aug 1989) RMP,EMB,STM (Sept 1989) RMP,EMB,CIPRO (Oct 1989) EMB,CIPRO (Nov 1989) CIPRO (Dec 1989) No treatment (July 1990) Rifabutin (Aug 1990) No treatment (Sept 1990) RMP,EMB (Oct 1990) No treatment (Jan 1991) RMP,EMB,CIPRO (Nov 1991)	17 months
2	58/F	RMP,INH,EMB (July 1989) RMP,EMB (March 1990) RMP,INH,↑EMB (Sept 1990) CIPRO (March 1991)	21 months
3	57/M	RMP,INH,EMB,PZA (June 1991) RMP,EMB,STM,CIPRO (Aug 1991) EMB,STM,CIPRO (Jan 1992) EMB,CIPRO (April 1992)	13 months

CIPRO = ciprofloxacin; EMB = ethambutol; INH = isoniazid; PZA = pyrazinamide; RMP = rifampicin; STM = streptomycin; () = given intermittently; ↑ = increased dose.

## Case 2

A 58 year old woman presented in June 1989 with an exacerbation of longstanding chronic obstructive pulmonary disease (FEV<sub>1</sub> 0.4 l (predicted 1.6 l), FVC 1.4 l (predicted 2.1 l)). She had a low grade pyrexia and the chest radiograph showed cavitation in both upper lobes. Sputum was film negative for AAFB but the culture was reported positive for *M. malmoense* three months later. Initially she was treated with triple antituberculous chemotherapy (rifampicin, isoniazid, and ethambutol) but subsequently received rifampicin and ethambutol (table). Radiographic and clinical deterioration occurred in September 1990 and isoniazid was reintroduced and the dose of ethambutol increased with no objective response. In March 1991 triple therapy was discontinued because of gastrointestinal symptoms and abnormal liver function tests and treatment with ciprofloxacin was started. Sputum became positive for *A. fumigatus* and precipitating antibodies were detected in the serum for the first time. The patient died in April 1991. Post mortem examination showed gross destruction of both upper lobes and left lower lobe pneumonia in addition to changes consistent with chronic obstructive pulmonary disease. Lung tissue was film positive but culture negative for AAFB and culture positive for *A. fumigatus*.

## Case 3

A 57 year old man with longstanding chronic obstructive pulmonary disease (FEV<sub>1</sub> 0.8 l (predicted 3.1 l), FVC 2.5 l (predicted 3.9 l)) on maintenance prednisolone (5 mg/day) presented in June 1991 with worsening dyspnoea and fever. His chest radiograph (fig 1) showed new right upper lobe shadowing and sputum grew *M. malmoense* over the next six months. Standard quadruple antituberculous chemotherapy was commenced but, because of drug

Respiratory Unit,  
Western General  
Hospital, Edinburgh  
EH4 2XU  
F G E Böllert  
G K Crompton

Chest Unit, City  
Hospital, Edinburgh  
EH10 5SB  
P J Sime  
W MacNee

Reprint requests to:  
Dr F G E Böllert.

Received 11 March 1993  
Returned to authors  
14 April 1993  
Revised version received  
14 June 1993  
Accepted for publication  
6 July 1993

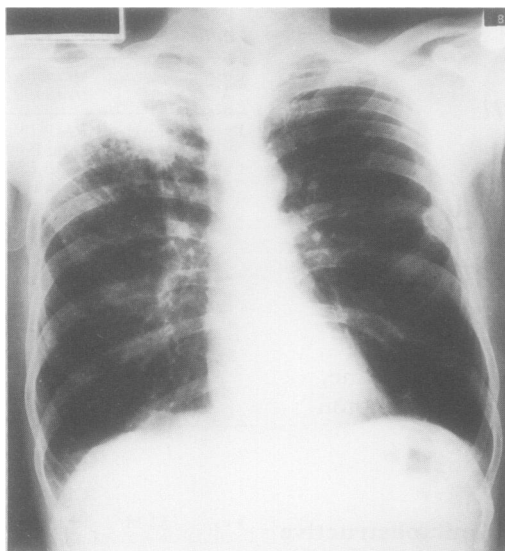


Figure 1 Chest radiograph of case 3 at presentation in June 1991.

intolerance and clinical and radiographic deterioration, treatment was changed to rifampicin, ethambutol, streptomycin, and ciprofloxacin (table). Rifampicin and streptomycin were discontinued after six and nine months respectively because of adverse effects. Serology sputum samples became positive for *A. fumigatus* and *A. terreus*. Itraconazole was given for four months without benefit. Radiographic deterioration occurred with increasing right upper lobe cavitation and new left upper lobe shadowing (fig 2). From March 1992 onwards *Achromobacter xylosoxidans* was isolated from the sputum despite appropriate antibiotics. The patient died in July 1992. Post mortem examination showed destruction of both upper lobes, an aspergilloma in the right upper lobe cavity, and pneumonic consolidation of the right middle and lower lobe. There was no histological evidence of fungal invasion of

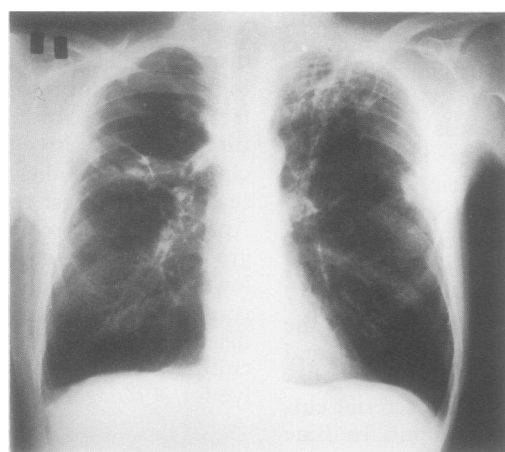


Figure 2 Chest radiograph of case 3 before death in June 1992.

blood vessels but specimens from both upper lobe cavities revealed fungal hyphae on direct microscopy and cultures grew *A. fumigatus*. All specimens were film and culture negative for AAFB. *Achromobacter xylosoxidans* was cultured from lung, kidney, and spleen.

## Discussion

There has been an increase in the incidence of pulmonary *M. malmoense* infection in the UK since 1980 which cannot be attributed to improved culture techniques alone.<sup>1</sup> Coexistence of *M. malmoense* and aspergillus infection has not been reported previously although *M. tuberculosis*, *M. xenopi*, and *M. kansasii* infections are known to occur in patients with aspergillomata.<sup>2-5</sup> In contrast, our patients developed aspergillus infection soon (5–22 months) after isolation of *M. malmoense* and all died within eight months of aspergillus colonisation. All patients had evidence of active *M. malmoense* infection rather than colonisation of pre-existing damaged pulmonary tissue. There was radiographic improvement with antimycobacterial treatment in only one patient (case 1) but sputum cultures remained positive for *M. malmoense*. In cases 2 and 3 deterioration occurred in spite of treatment, and all three patients declined rapidly after *A. fumigatus* was isolated. In no patient, however, was there proof of invasive aspergillosis at post mortem examination, this diagnosis being suspected before death in cases 2 and 3. One patient may have been immunocompromised because of long term treatment with prednisolone 5 mg daily. None of the patients had any risk factors for HIV infection. Case 3 consented as part of a research study to an HIV test which was negative.

We suggest that the combination of pulmonary non-tuberculous mycobacterial infection and *A. fumigatus* may have a poorer prognosis than pulmonary mycobacteriosis alone. In the light of our experience with these three cases it may be prudent to treat *A. fumigatus* infection aggressively whenever it is found to complicate non-tuberculous mycobacterial infections.

We are grateful for the help of Dr B Watt (TB Reference Laboratory at the City Hospital, Edinburgh) and Dr L J R Milne (Mycology Reference Laboratory at the Western General Hospital, Edinburgh).

- 1 Jenkins PA. *Mycobacterium malmoense*. *Tubercle* 1985;66:193–5.
- 2 British Tuberculosis Association. Aspergillus in persistent lung cavities after tuberculosis. *Tubercle* 1968;49:1–11.
- 3 Jewkes J, Kay PH, Paneth M, Citron KM. Pulmonary aspergilloma: analysis of prognosis in relation to haemoptysis and survey of treatment. *Thorax* 1983;38:572–8.
- 4 Johnston IDA. *Mycobacterium xenopi* infection and aspergilloma. *Tubercle* 1988;69:139–44.
- 5 Maliwan N, Zvetina JR. Pulmonary mycetoma following *Mycobacterium kansasii* infection. *Arch Intern Med* 1985;145:2180–3.